

# Feasibility of vNOTES hysterectomy in patients with enlarged uteri: a single-center experience

✉ Candost Hanedan, ✉ Hande Nur Öncü, ✉ Neslihan Öztürk, ✉ Gökçen Ege, ✉ Oğuz Kaan Köksal, ✉ Vakkas Korkmaz

Clinic of Gynecologic Oncology, University of Health Sciences Türkiye, Ankara Etlik City Hospital, Ankara, Türkiye

## Abstract

**Objective:** To evaluate the feasibility, safety, and surgical outcomes of vaginal natural orifice transluminal endoscopic surgery (vNOTES) hysterectomy in patients with enlarged uteri due to benign, premalignant, and malignant conditions.

**Material and Methods:** Patients who underwent vNOTES hysterectomy at a tertiary gynecologic oncology center were included. Patients with large uteri (>280 g or equivalent to >12-week size) were included regardless of prior cesarean delivery, obesity, nulliparity, or the presence of premalignant or malignant pathology. Demographic data, surgical outcomes, and complication details were analyzed. Complications were classified as minor or major.

**Results:** The cohort consisted of 46 women with a median age of 54 (40-74) years, and median body mass index 31 (21-51) kg/m<sup>2</sup>. A history of previous abdominal surgery was present in 58.7%, and 21.7% (10/46) had previously undergone cesarean section. The median operative time was 56 (35-95) minutes, and the median uterine weight was 410 (280-1036) grams. The overall conversion and complication rates were both 4.3% (n=2). No major complications were observed. Minor complications included intraoperative bleeding controlled without transfusion and postoperative vaginal bleeding managed conservatively. The median hospital stay was 30 (16-72) hours. All patients were discharged without requiring reoperation during the postoperative period.

**Conclusion:** vNOTES hysterectomy was a feasible and safe, minimally invasive approach for patients with enlarged uteri, including those with obesity, prior abdominal surgery, and premalignant or malignant indications. It provides favorable surgical outcomes with low complication and conversion rates. This study supports the use of the vNOTES technique with a broader adoption in patients with large uteri. [J Turk Ger Gynecol Assoc.2025; 26(4): 284-8]

**Keywords:** Hysterectomy, vNOTES, natural orifice endoscopic surgery

**Received:** 13 May, 2025 **Accepted:** 30 July, 2025 **Epub:** 22.09.2025 **Publication Date:** 03 December, 2025

## Introduction

Vaginal natural orifice transluminal endoscopic surgery (vNOTES) has recently emerged as a popular surgical approach that combines the advantages of both laparoscopic and vaginal surgery, offering patients a minimally invasive alternative (1). Hysterectomy via vNOTES is performed transvaginally without the need for an abdominal incision, and is associated with

reduced postoperative pain, shorter operative times, faster recovery, and improved cosmetic outcomes (2-4).

However, large uteri present surgical challenges and may complicate the vaginal approach. In such cases, the limited mobility of surgical instruments, suboptimal visualization of pelvic organs, increased risk of bleeding, and prolonged uterine morcellation and operative times make both vaginal



**Address for Correspondence:** Candost Hanedan  
e-mail: cnhanedan@hotmail.com **ORCID:** orcid.org/0000-0003-3435-8943  
**DOI:** 10.4274/jtgga.galenos.2025.2025-4-3

**Cite this article as:** Hanedan C, Öncü HN, Öztürk N, Ege G, Köksal OK, Korkmaz V. Feasibility of vNOTES hysterectomy in patients with enlarged uteri: a single-center experience. J Turk Ger Gynecol Assoc. J Turk Ger Gynecol Assoc. 2025; 26(4): 284-8



Copyright© 2025 The Author. Published by Galenos Publishing House on behalf of Turkish-German Gynecological Association.  
This is an open access article under the Creative Commons Attribution-NonCommercial-NoDerivatives 4.0 (CC BY-NC-ND) International License.

hysterectomy (VH) and laparoscopic hysterectomy (LH) more difficult (5,6). vNOTES combines the benefits of VH with the magnified visualization provided by endoscopic surgery. It is considered a safe and effective method that expands the traditional indications for VH (7). In the management of patients with large uteri, vNOTES provides easier access to the uterine vasculature and enables the separation of uterine ligaments under direct optical guidance, offering a significant advantage for safe surgery (8,9).

The literature on the feasibility of vNOTES in patients with large uteri is limited, although clinical experience in this area is steadily increasing. In the present study, the aim was to evaluate the feasibility and safety of vNOTES hysterectomy in patients with large uteri performed at a single center.

## Material and Methods

This study was approved by the Scientific Research Ethics Committee of University of Health Sciences Türkiye, Ankara Etlik City Training and Research Hospital (approval number: AEŞH-BADEK-2025/0266, date: 12.03.2025), patients scheduled for hysterectomy in the gynecologic oncology clinic and who underwent vNOTES hysterectomy were included in the study. Written informed consent was obtained from all patients prior to the procedure. Uterine weight was measured intraoperatively using a precision scale in the operating room, and only patients with uterine weights  $\geq 280$  grams were included. Patients with uterine weights  $< 280$  grams or who did not provide consent were excluded.

All surgeries were performed by two gynecologic oncologists with more than 10 years of experience in laparoscopic and vaginal surgery. Prior to surgery, pap smear and endometrial biopsy samples were obtained from all patients. The vNOTES port system (Alexis® retractor and GelPOINT® V-Path, Applied Medical) was used in all patients. No other port systems were used. All patients underwent bilateral salpingectomy in addition to vNOTES hysterectomy, and oophorectomy was performed when indicated. Pathological evaluations were conducted by histopathologists specialized in gynecologic pathology.

The International Society for Gynecologic Endoscopy guidelines, define a uterus weighing  $\geq 280$  grams as a large uterus (10). The median operative time refers to the total duration from the initial incision (beginning of colpotomy and port placement) to the final closure of the vaginal cuff, commonly defined as “skin-to-skin” time.

Patient characteristics including age, body mass index (BMI reported in  $\text{kg/m}^2$ ), parity, history of previous abdominal surgery, history of cesarean delivery, operative time (in minutes), uterine weight (in g), length of hospital stay (in hours), preoperative and postoperative hemoglobin (Hb) levels (g/dL), surgical indications, sentinel lymph node procedures,

conversions to laparoscopy, and complications were recorded. Complications were classified as minor or major.

## Statistical analysis

Statistical analyses were performed using SPSS for Mac, Version 22.0 (IBM INC., Armonk, NY, USA). The normality of data distribution was assessed using normality tests. Parametric variables are presented as mean  $\pm$  standard deviation, while non-parametric variables were reported as median (minimum and maximum values).

## Results

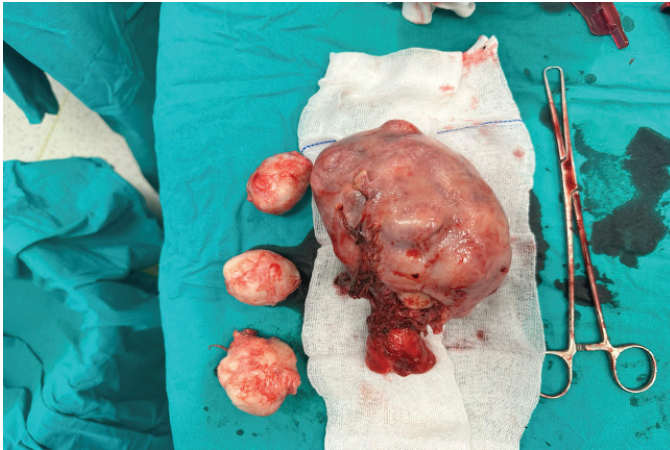
The study included 46 patients with a median age of 54 (40-74) years, BMI of 31 (21-51)  $\text{kg/m}^2$ , and parity of 3 (0-6). Of the cohort, 58.7% (27/46) had a history of abdominal surgery, and 21.7% (10/46) had previously delivered via cesarean section. The demographic characteristics of the patients are presented in Table 1.

The median operative time was 56 (35-95) minutes, median uterine weight was 410 (280-1036) grams, preoperative Hb level was 13.1 (8.6-15.9) g/dL with postoperative Hb level of 11.7 (8.8-14.4) g/dL, and median hospital stay was 30 (16-72) hours. The maximum uterine weight recorded was 1036 grams (Figure 1). The most common surgical indications were myomatous uterus (30.4%) and adnexal mass (17.4%). Sentinel lymph node mapping was performed in 4 (8.7%). Conversion to laparoscopy was required in 2 (4.3%).

One intraoperative complication (2.2%) and one postoperative complication (2.2%) were observed. There were no bladder or bowel perforations. Intraoperatively, insufficient coagulation of the right uterine artery led to an approximately 500 cc blood loss, which did not require transfusion. After identification of the ureter in the retroperitoneal space, the artery was proximally re-ligated to achieve hemostasis. However, one patient in our series experienced postoperative bleeding that

**Table 1. The demographic characteristics of patients**

Variables	
Number of patients	46
Age (years), median (min-max)	54 (40-74)
BMI ( $\text{kg/m}^2$ ), median (min-max)	31 (21-51)
Parity, median (min-max)	3 (0-6)
Prior surgery, n (%)	27 (58.7)
Prior caesarean section, n (%)	10 (21.7)
Data are expressed as median, minimum, maximum or number (%) BMI: body mass index, Min: Minimum, Max: Maximum	



**Figure 1. vNOTES hysterectomy specimen with a uterine weight of 1036 g**  
*vNOTES: Vaginal natural orifice transluminal endoscopic surgery*

required blood transfusion. The source of the bleeding was identified as the posterior aspect of the vaginal cuff. This was managed conservatively with medical treatment, including hemodynamic support and hemostatic agents, without the need for surgical reintervention. We believe the bleeding was most likely venous in origin, arising from small vessels in the vaginal cuff area, and not related to any significant vascular injury. All patients were discharged without requiring further surgical intervention. Operative and histopathological data of the patients are summarized in Table 2.

## Discussion

In the United States, approximately 600,000 hysterectomies are performed annually, making it the most common non-obstetric surgical procedure among women (11). Hysterectomy may be indicated for various conditions, including fibroids, adenomyosis, abnormal uterine bleeding, adnexal masses, endometrial intraepithelial neoplasia, and low-risk endometrial cancer.

Hysterectomy can be performed via abdominal hysterectomy (AH), laparoscopic surgery, VH, or robotic-assisted laparoscopy (RH). Vaginal and laparoscopic procedures (LAVH/LH/RH) are considered “minimally invasive” approaches as they avoid large abdominal incisions. Consequently, these methods are associated with shorter hospital stays and faster postoperative recovery than open AH (12). Current evidence supports using minimally invasive techniques as the preferred method for hysterectomy whenever feasible (10,13).

The vNOTES hysterectomy technique was introduced by Su et al. (14) in 2012 as a novel minimally invasive approach utilizing the transvaginal route to access the peritoneal cavity. This technique merges elements of traditional vaginal surgery with single-port laparoscopy, allowing for comprehensive

**Table 2. Operation and histopathological characteristics of the 46 patients**

Variables	
Operation time (min)	56 (35-95 )
Uterine weight (g)	410 (280-1036)
Length of hospital stay (hour)	30 (16-72)
Hemoglobin before surgery (g/dL)	13.1 (8.6-15.9)
Hemoglobin after surgery (g/dL)	11.7 (8.8-14.4)
Indication for surgery, n (%)	
Myomatous uterus	20 (43.4)
Adenomyosis	1 (2.2)
Prolapse	2 (4.4)
Adnexal mass	8 (17.4)
Treatment-resistant DUB	5 (10.9)
Atypical endometrial hyperplasia	4 (8.7)
Endometrial intraepithelial neoplasia	3 (6.5)
Endometrial adenocarcinoma	3 (6.5)
Sentinel lymph node mapping, n (%)	4 (8.7)
Conversions, n (%)	2 (4.3)
Complications	
Intra-operative, n (%)	1 (2.2)
Post-operative, n (%)	1 (2.2)
Data are expressed as median, minimum, maximum or number (%) DUB: dysfunctional uterine bleeding, Min: Minimum, Max: Maximum	

intra-abdominal evaluation. It has proven to be safe, even in patients without uterine prolapse or those with intra-abdominal adhesions.

Over the past five years, the adoption of vNOTES for both gynecologic and oncologic surgeries has notably increased. The growing body of randomized controlled trials has helped to overcome early skepticism, establishing vNOTES as an increasingly popular and promising surgical approach among gynecological surgeons (15-17).

The choice of hysterectomy method often depends on the surgeon’s training and experience. Many authors emphasize the declining use of VH due to insufficient training, leading gynecologists to favor abdominal or laparoscopic routes (10,18). This tendency is more pronounced in specific patient populations, such as those with previous cesarean sections, nulliparous women, obese patients, cases involving large uteri large uteri (defined as >280 g or >12-week gestational size equivalent), and those with premalignant or malignant pathologies. Although the definition of a “large uterus” remains debatable, many studies consider uteri exceeding 280 g or measuring more than 12 weeks in size as large (10,19). A large uterus can obstruct the pelvic space, making mobilization

and manipulation difficult. This limitation can hinder the identification of critical anatomic landmarks, delay bleeding control, and complicate surgical procedures, especially in cases involving cervical myomas.

To date, there is a lack of published data on the use of vNOTES hysterectomy in cases involving large uteri with benign, premalignant, or malignant pathologies. In such scenarios, surgeons must pay particular attention to structures like the ureters, especially given the reduced opportunity for uterine manipulation, restricted visualization, and potential challenges during posterior colpotomy in large uteri (>1000 g).

In the present study, the median BMI was in the obese range (31 kg/m<sup>2</sup>), with previous abdominal surgery and cesarean section rates of nearly 60% and just over one fifth, respectively. In a cross-sectional study, Kaya et al. (20) compared total LH (TLH) (n=35) and vNOTES (n=48) in obese patients. The mean BMI values were similar (31.6 vs. 31.9), but the vNOTES group had shorter operative times (80 vs. 135 minutes) and significantly lower postoperative visual analog scale pain scores at both 6 and 24 hours.

In our series, the conversion and complication rates were both 4.3% (n=2), while the 30-day readmission rate was 2.17% (n=1). The discharge rate within 24 hours was 30% (n=14). One patient requiring conversion had a BMI of 48 kg/m<sup>2</sup> and a history of cesarean section; the other had deep infiltrating endometriosis initially mistaken for an adnexal mass. In both cases, conversion to multiport laparoscopy allowed for safe completion of the procedure. Two patients experienced intra- or post-operative bleeding, both successfully managed with medical treatment alone. One patient developed a cuff hematoma within 30 days, which resolved with conservative antibiotic management.

These outcomes are consistent with the existing literature. For example, Baron et al. (21) and Lee et al. (22) reported vNOTES conversion rates of 2.8% and 5.1%, respectively. In a randomized controlled trial by Baekelandt et al. (23), the 6-week readmission rate was 3%, and the study confirmed that vNOTES is non-inferior to TLH in terms of surgical success and conversion rates. The findings also suggest that vNOTES may allow more patients to undergo hysterectomy in a day-care setting.

In the present study, no cases of bladder or bowel perforation were observed. This rate was notably lower than the complication rates reported in the literature. For instance, in a study by Stuart et al. (24), intraoperative complications occurred in 3.2% of cases (n=144), with cystotomy being the most common among less experienced surgeons (1.3%). In addition, bowel or other intra-abdominal organ injuries were reported in 20 cases (0.44%). The absence of such complications in our series may be attributed to the surgeons'

extensive experience, strict adherence to surgical protocols, careful patient selection and small group size. These factors likely contributed to the lower complication rates observed and suggest that outcomes may vary significantly depending on the surgical team's expertise.

### Study limitations

One of the main strengths of our study was its focus on large uteri, including challenging patient groups, such as those with a history of cesarean section, nulliparity, obesity, and premalignant or malignant pathology. We believe this adds to the current limited literature on vNOTES. All procedures were performed by two experienced gynecologic oncologists, which may have contributed to the low complication rates observed in this study. However, the study has several limitations. The relatively small sample size limits the generalizability of our findings. Moreover, the procedures being performed by only two highly experienced surgeons may affect reproducibility in different clinical settings. Another limitation of this study was the lack of a control group of patients with uteri <280 g, which limits the ability to directly compare outcomes across different uterine sizes. Future prospective studies with appropriate control groups are necessary to validate and build on our findings.

### Conclusion

A vNOTES hysterectomy was a feasible and safe, minimally invasive approach for patients with enlarged uteri, including those with obesity, prior abdominal surgery, and premalignant or malignant indications. It provides favorable surgical outcomes with low complication and conversion rates. This study supports the use of the vNOTES technique with a broader adoption in patients with large uteri.

### Ethic

**Ethics Committee Approval:** This study was approved by the Scientific Research Ethics Committee of University of Health Sciences Türkiye, Ankara Etlik City Training and Research Hospital (approval number: AEŞH-BADEK-2025/0266, date: 12.03.2025).

**Informed Consent:** Written informed consent was obtained from all patients prior to the procedure.

### Footnotes

**Author Contributions:** Surgical and Medical Practices: C.H., V.K., Concept: C.H., V.K., Design: C.H., V.K., Data Collection or Processing: H.N.Ö., N.Ö., G.E., Analysis or Interpretation: C.H., V.K., Literature Search: N.Ö., O.K.K., C.H., Writing: C.H., H.N.Ö., N.Ö.



**Conflict of Interest:** No conflict of interest is declared by the authors.

**Financial Disclosure:** The authors declared that this study received no financial support.

## References

1. Baekelandt J. Total vaginal NOTES hysterectomy: a new approach to hysterectomy. *J Minim Invasive Gynecol.* 2015; 22: 1088-94.
2. Housmans S, Noori N, Kapurubandara S, Bosteels JJA, Cattani L, Alkatout I, et al. Systematic review and meta-analysis on hysterectomy by vaginal natural orifice transluminal endoscopic surgery (vNOTES) compared to laparoscopic hysterectomy for benign indications. *J Clin Med.* 2020; 9: 3959.
3. Baekelandt JF, De Mulder PA, Le Roy I, Mathieu C, Laenen A, Enzlin P, et al. Hysterectomy by transvaginal natural orifice transluminal endoscopic surgery versus laparoscopy as a day-care procedure: a randomised controlled trial. *BJOG.* 2019; 126: 105-13.
4. Karkia R, Giacchino T, Taylor J, Ghaffar A, Gupta A, Kovoor E. Hysterectomy and adenectomy via transvaginal natural orifice transluminal endoscopic surgery (vNOTES): a UK perspective with a case series of 33 patients. *Eur J Obstet Gynecol Reprod Biol.* 2019; 242: 29-32.
5. Roman H, Zanati J, Friederich L, Resch B, Lena E, Marpeau L. Laparoscopic hysterectomy of large uteri with uterine artery coagulation at its origin. *JSLs.* 2008; 12: 25-9.
6. Drahonovsky J, Haakova L, Otcenasek M, Krofta L, Kucera E, Feyereisl J. A prospective randomized comparison of vaginal hysterectomy, laparoscopically assisted vaginal hysterectomy, and total laparoscopic hysterectomy in women with benign uterine disease. *Eur J Obstet Gynecol Reprod Biol.* 2010; 148: 172-6.
7. Kaya C, Alay İ, Ekin M, Yaşar L. Hysterectomy by vaginal-assisted natural orifice transluminal endoscopic surgery: initial experience with twelve cases. *J Turk Ger Gynecol Assoc.* 2018; 19: 34-8.
8. Nulens K, Bosteels J, De Rop C, Baekelandt J. vNOTES hysterectomy for large uteri: a retrospective cohort study of 114 patients. *J Minim Invasive Gynecol.* 2021; 28: 1351-6.
9. Wang X, Li J, Hua K, Chen Y. Transvaginal natural orifice transluminal endoscopic surgery (vNOTES) hysterectomy for uterus weighing  $\geq 1$  kg. *BMC Surg.* 2020; 20: 234.
10. Chrysostomou A, Djokovic D, Edridge W, van Herendael BJ. Evidence-based guidelines for vaginal hysterectomy of the International Society for Gynecologic Endoscopy (ISGE). *Eur J Obstet Gynecol Reprod Biol.* 2018; 231: 262-7.
11. Wu JM, Wechter ME, Geller EJ, Nguyen TV, Visco AG. Hysterectomy rates in the United States, 2003. *Obstet Gynecol.* 2007; 110: 1091-5.
12. Aarts JW, Nieboer TE, Johnson N, Tavender E, Garry R, Mol BW, et al. Surgical approach to hysterectomy for benign gynaecological disease. *Cochrane Database Syst Rev.* 2015; 2015: CD003677.
13. No authors listed. ACOG Committee Opinion No. 444: choosing the route of hysterectomy for benign disease. *Obstet Gynecol.* 2009; 114: 1156-8.
14. Su H, Yen CF, Wu KY, Han CM, Lee CL. Hysterectomy via transvaginal natural orifice transluminal endoscopic surgery (NOTES): feasibility of an innovative approach. *Taiwan J Obstet Gynecol.* 2012; 51: 217-21.
15. Baekelandt JF, De Mulder PA, Le Roy I, Mathieu C, Laenen A, Enzlin P, et al. Transvaginal natural orifice transluminal endoscopic surgery (vNOTES) adnexectomy for benign pathology compared with laparoscopic excision (NOTABLE): a protocol for a randomised controlled trial. *BMJ Open.* 2018; 8: e018059.
16. Lowenstein L, Mor O, Matanes E, Justman N, Stuart A, Baekelandt J. Conventional vaginal approach vs. transvaginal natural orifice transluminal endoscopic surgery for treating apical prolapse, a randomized controlled study. *Eur J Obstet Gynecol Reprod Biol.* 2024; 303: 180-5.
17. Lee SH, Oh SR, Cho YJ, Han M, Park JW, Kim SJ, et al. Comparison of vaginal hysterectomy and laparoscopic hysterectomy: a systematic review and meta-analysis. *BMC Womens Health.* 2019; 19: 83.
18. Miskry T, Magos A. A national survey of senior trainees surgical experience in hysterectomy and attitudes to the place of vaginal hysterectomy. *BJOG.* 2004; 111: 877-9.
19. Yavuzcan A, Çağlar M, Ustün Y, Dilbaz S, Kumru S. Evaluation of the outcomes of laparoscopic hysterectomy for normal and enlarged uterus ( $>280$  g). *Arch Gynecol Obstet.* 2014; 289: 831-7.
20. Kaya C, Yıldız Ş, Alay İ, Aslan Ö, Aydın İE, Yaşar L. The comparison of surgical outcomes following laparoscopic hysterectomy and vNOTES hysterectomy in obese patients. *J Invest Surg.* 2022; 35: 862-7.
21. Baron C, Netter A, Tourette C, Pivano A, Agostini A, Crochet P. Initial experience with vNOTES hysterectomy for benign conditions in a French university hospital. *Facts Views Vis Obgyn.* 2022; 14: 147-53.
22. Lee CL, Wu KY, Su H, Wu PJ, Han CM, Yen CF. Hysterectomy by transvaginal natural orifice transluminal endoscopic surgery (NOTES): a series of 137 patients. *J Minim Invasive Gynecol.* 2014; 21: 818-24.
23. Baekelandt JF, De Mulder PA, Le Roy I, Mathieu C, Laenen A, Enzlin P, et al. Hysterectomy by transvaginal natural orifice transluminal endoscopic surgery versus laparoscopy as a day-care procedure: a randomised controlled trial. *BJOG.* 2019; 126: 105-13.
24. Stuart A, Wagenius J, Badiglian-Filho L, Schnabel J, Montealegre A, Ehrström S, et al. Intra- and postoperative complications in 4565 vNOTES hysterectomies: international registry cohort study. *BJOG.* 2025; 132: 464-72.