

# Fetal intracranial hemorrhage: prenatal sonographic diagnosis criteria and postnatal outcomes

✉ Zeynep Gedik Özköse<sup>1</sup>, ✉ Süleyman Cemil Oğlak<sup>2</sup>, ✉ Ayşegül Bestel<sup>1</sup>, ✉ Mustafa Behram<sup>1</sup>,  
✉ Sema Süzen Çaypınar<sup>1</sup>, ✉ Fatma Ölmez<sup>3</sup>, ✉ İsmail Özdemir<sup>1</sup>

<sup>1</sup>Clinic of Perinatology, University of Health Sciences Turkey, Kanuni Sultan Süleyman Training and Research Hospital, İstanbul, Turkey

<sup>2</sup>Clinic of Obstetrics and Gynecology, University of Health Sciences Turkey, Gazi Yaşargil Training and Research Hospital, Diyarbakır, Turkey

<sup>3</sup>Clinic of Obstetrics and Gynecology, University of Health Sciences Turkey, Kanuni Sultan Süleyman Training and Research Hospital, İstanbul, Turkey

## Abstract

**Objective:** The aim of this study was to improve knowledge of prenatally diagnosed fetal intracranial hemorrhage (ICH), defining the ultrasound (US) examination results, the contribution of fetal magnetic resonance imagination (MRI) to the diagnosis, and the pregnancy outcomes, from a series of fetal ICH cases.

**Material and Methods:** This retrospective, observational study included eleven fetuses diagnosed with ICH from April 2016 to August 2020. The data regarding the medical records, prenatal US and MRI findings, treatment, and prognosis of fetal ICH cases were collected from the hospital database and analyzed.

**Results:** Fetal ICHs were grade 3 in six cases, and grade 4 in the remaining five cases. The mean gestational age at diagnosis was 30.2 weeks. Nine (81.8%) of the cases were diagnosed in the third trimester and two (18.2%) in the second trimester. Fetal cranial MRI was performed in 7/11 (63.6%) following ultrasonographic diagnosis. MRI confirmed fetal ICH diagnosis and previous US findings regarding location and grade in all cases. Five patients (45.5%) diagnosed with grade 3 (n=1) and grade 4 (n=4) ICH underwent pregnancy termination. Of the remaining six cases, one (9.1%) diagnosed with grade 3 fetal ICH resulted in an intrauterine fetal demise. Four cases classified as grade 3 fetal ICH and one case with grade 4 fetal ICH were born alive at term.

**Conclusion:** The clinical manifestations of fetal ICH are diverse and have a wide spectrum of severity and prognostic implications. Fetal ICH cases were mainly detected in the third trimester, with a minority detected in the second trimester. These cases can be safely diagnosed and graded by US examination, but the underlying etiology frequently cannot be determined. Fetal cranial MRI may aid in diagnosis confirmation if this is unclear from US in order to provide appropriate counseling to the parents. (J Turk Ger Gynecol Assoc 2022; 23: 268-74)

**Keywords:** Fetal intracranial hemorrhage, prenatal diagnosis, ultrasound

**Received:** 11 March, 2021 **Accepted:** 29 July, 2021

## Introduction

Neonatal intracranial hemorrhage (ICH) is a common postnatal complication in low birth weight and/or premature infants in the postnatal period. However, it rarely occurs in the prenatal period, affecting approximately 0.5-0.9 per 1000 pregnancies

(1). Fetal ICH is mostly diagnosed in the later stages of gestation as an incidental ultrasound (US) finding following a normal US examination in the second trimester (2). Prenatal diagnosis of fetal ICH has been increasingly reported in recent years because of the advances in both US examination and magnetic



**Address for Correspondence:** Süleyman Cemil Oğlak

e.mail: sampson\_21@hotmail.com ORCID: orcid.org/0000-0001-7634-3008

©Copyright 2022 by the Turkish-German Gynecological Education and Research Foundation - Available online at [www.jtgga.org](http://www.jtgga.org)

Journal of the Turkish-German Gynecological Association published by Galenos Publishing House.

DOI: 10.4274/jtgga.galenos.2021.2021-0042

resonance imaging (MRI) technologies (3). However, the exact incidence of fetal ICH is still unclear, due to difficulties with ultrasonographic diagnosis in some cases and some fetal ICHs are still missed (4).

In most cases, the cause of fetal ICH cannot be identified. Possible predisposing factors for this complication include maternal trauma, thrombocytopenia, maternal use of anti-coagulants that can cross the placenta, fetal coagulation disorders, non-immune hydrops fetalis, twin to twin transfusion syndrome (TTTS), fetal infections, and severe fetal hypoxia (5-7).

There is a wide variation in the US appearance of fetal ICH as it is difficult to identify and differentiate from other intracranial lesions (5). The prognosis of fetal ICH is closely associated with the grade of hemorrhage and the severity of associated brain injury (3). Previous studies reported that prenatally diagnosed ICHs experience a poor outcome; approximately 40% of fetuses die either during the course of gestation or within the first month following birth and less than half of the survivors exhibit healthy neurological development (8). Therefore, diagnosis in the early stages is crucial.

In recent years, with the advancement of US technologies, and the utilization of fetal MRI as a diagnostic tool for fetal cerebral pathologies, the number of diagnosed patients has increased and the predictive ability of the prognosis of this complication has improved. Knowledge of diagnostic criteria, early identification, clinical importance, and the prognosis of fetal ICH is essential to provide accurate prenatal parental counseling and pregnancy management (7,9).

The aim of this study was to improve knowledge of prenatally diagnosed fetal ICH, defining the US examination results, the contribution of fetal MRI to the diagnosis, and the pregnancy outcomes from a series of 11 fetuses with ICH.

## Material and Methods

This retrospective, observational study was performed with patients admitted to the Perinatology Unit of University of Health Sciences Turkey, Kanuni Sultan Süleyman Training and Research Hospital, from April 2016 to August 2020. Eleven fetuses diagnosed as having ICH were included. The study protocol was approved by the University of Health Sciences Turkey, Kanuni Sultan Süleyman Training and Research Hospital Institutional Ethics Committee (approval number: 2020.12.226). A written informed consent form was obtained from all parents.

Data from the medical records, prenatal two-dimensional (2D) US and MRI findings, treatments used, and prognosis of these 11 fetal ICH cases were collected from the hospital database and analyzed. All ultrasonographic fetal cranial examinations were performed and analyzed by expert sonographers with

advanced training in prenatal diagnosis. US examinations were conducted transabdominally and also transvaginally when the fetus was in cephalic presentation, using high-resolution US devices (Voluson 730 Expert and Voluson E6) with a convex probe (3.5-5 MHz for transabdominal examinations, 5-6.5 MHz for transvaginal examinations).

The central nervous system (CNS) examination was performed according to the ISUOG practice guidelines (10). This examination included evaluation of the cisterna magna, lateral ventricles, choroid plexus, thalamus, and cavum septum pellucidum in the transcerebellar, transventricular, and transthalamic planes. In addition, the umbilical cord and its insertion, all four extremities, intra-abdominal organs, heart and great vessels, spine, and face were evaluated to determine any associated abnormalities. Serial 2D US examinations were performed every 2-4 weeks to investigate lesion progression, fetal biometry, and fetal wellbeing. In cases where fetal intrauterine growth restriction (IUGR) was suspected, a Doppler US examination of the fetal umbilical arteries was performed (11).

The diagnosis of fetal ICH was based on the presence of one or more of the following characteristics: intraventricular hyperechogenic foci suggesting clots; hyperechogenic and indented ventricular walls; ventriculomegaly with irregular bulky choroid plexus; parenchymal hyperechogenic avascular mass; increased echogenicity in periventricular white matter; and/or porencephalic cyst formation. The location, size, and appearance of all the lesions were assessed. Intraventricular hemorrhage was classified as grade 1 when the hemorrhage was limited to the subependymal germinal matrix, grade 2, when the blood clots were inside the lateral ventricle without ventriculomegaly or with ventriculomegaly but the clots were <15 mm at the level of lateral ventricular atria, grade 3, when the clots affected one or two lateral ventricles with ventriculomegaly >15 mm at the level of the lateral ventricular atria, and grade 4, when grade 1 to 3 hemorrhages were accompanied with hemorrhage in a large part of the periventricular parenchyma (3,9).

Antenatal work-up to determine the underlying cause of fetal ICH included a history of previous pregnancy characteristics, maternal trauma, history of drug exposure (especially acetylsalicylic acid and anticoagulant therapy), assays for alloimmune and isoimmune thrombocytopenia, coagulation tests (platelet count, prothrombin time, activated partial thromboplastin time), and maternal serological testing for parvovirus B19, toxoplasmosis, rubella, and cytomegalovirus infections (6).

Fetal cranial MRI was offered to all patients to confirm the ICH diagnosis and to evaluate the hydrocephaly, irrespective of the degree of ventriculomegaly (2). Standard MRI scanning

procedures were conducted using a 1.5 T MRI scanner. The mothers underwent MRI scanning after a four hour fast, with an empty bladder, and in the supine position without sedation. Pediatric neurologists performed postnatal evaluation and cranial brain imaging in all living neonates. Pediatric hematologists evaluated all living neonates regarding congenital bleeding diseases. Pregnancy outcomes, fetal and postnatal morbidity, and mortality were analyzed.

### Statistical analysis

IBM SPSS, version 21.0 for Windows (SPSS Inc., Chicago, IL, USA) statistical program was used for statistical evaluation of the research data. A descriptive analysis was performed following completion of the audit. Continuous variables are presented as mean  $\pm$  standard deviation or median (minimum-maximum). Categorical variables are presented as frequencies and percentages.

### Results

During the study period, a total of 11 cases with fetal ICH were identified in a single tertiary referral hospital. The demographic characteristics, US and MRI findings, and outcomes of the cases are summarized in Table 1. Fetal ICHs were grade 3 in six cases, and grade 4 in the remaining five cases. No cases of grade 1 or 2 hemorrhage were detected. ICH was observed as bilateral in all cases (n=11, 100%). The mean gestational age at diagnosis was 30.2 weeks (ranging from 22 weeks to 36 weeks). Nine (81.8%) of the cases were diagnosed in the third trimester and two (18.2%) were diagnosed in the second trimester. One of the cases diagnosed in the second trimester was grade 3 fetal ICH and the other was grade 4. Maternal serological testing was performed in eight cases, while hematological and coagulation tests were performed in all cases. All of these tests were normal and underlying etiology could not be identified in any case.

A selection of US findings of the cases included is presented in Figure 1a-d. Figure 1a demonstrates echogenic, irregular and nodular lateral ventricular borders. Figure 1b shows intraventricular hyperechogenic foci, suggesting clots with unilateral and bilateral ventriculomegaly. Figure 1c represents periventricular hypoechoic nodules. Figure 1d illustrates periventricular leukomalacia.

The outcomes of the six grade 3 fetal ICH cases included one pregnancy termination and one intrauterine fetal demise (IUID) at 25 weeks of gestation. In one further case, ventricular width showed progression at follow-up. This case underwent a ventriculoperitoneal shunt (VPS) placement after the birth but died at six months of age. In two more grade 3 fetal ICH cases, ventriculomegaly showed regression during the postnatal follow-up. However, epilepsy and hemiparesis were observed in both these cases. A VPS placement was performed in one

case in the postnatal period. In this case, whose follow-up continued, no complications or neurological handicaps were observed regarding the fetal ICH and shunt placement.

Similarly, when the five cases with initial diagnosis of grade 4 fetal ICH were investigated, periventricular leukomalacia was observed in three, and both periventricular leukomalacia and porencephalic cysts were observed in the remaining two (Figure 2). Four of these pregnancies were terminated. One live birth infant was lost to follow-up during the postnatal period.

Fetal cranial MRI was performed in 7/11 (63.6%) following ultrasonographic diagnosis. The fetal MRI confirmed the fetal ICH diagnosis and previous US findings regarding location and grade in all cases.

In this series of 11 cases, 5 cases (45.5%) diagnosed with grade 3 (n=1) and grade 4 (n=4) fetal ICH underwent pregnancy termination. Of the remaining six, one case (9.1%) diagnosed with grade 3 fetal ICH resulted in an IUID. Four cases classified as grade 3 fetal ICH and one case with grade 4 fetal ICH were born alive at term. Live born infants were followed-up for a median duration of 18 months (ranging from 7 months to 36 months).

### Discussion

In this series of fetal ICH cases, similar to the previous reports, a range of US findings were seen across various clinical presentations, from hyperechogenic and intended ventricular walls to complete liquefaction with a cystic hypoechoic mass. Different US signs of fetal ICH have been identified. These signs differ because of variation in extension, location and amount of bleeding, and internal echo pattern which also varies depending on the blood clot formation and clot lysis status. Thus, prenatal diagnosis is frequently challenging. Furthermore, the ultrasonographic characteristics of fetal ICH will change over time in a relatively predictable manner (12). The US appearance of a recent hemorrhage, irrespective of location, is a brightly echogenic mass without dorsal shadowing. Initially, a fetal ICH appears as a homogeneous, echogenic zone within the brain parenchyma or ventricles, separated from the choroid plexus. Over time, as the blood clot dissolves, the US presentation becomes more heterogeneous, and an internal sonolucent core becomes evident with an external echogenic rim (2). Fetal ICH is commonly related to ventricular dilatation as a consequence of cerebral aqueduct obstruction by the blood clot. In addition, the blood within the ventricles terminates in an echogenic border lining the ventricle or nodular structures (5). Involvement of the brain cortex can be identified by demonstration of the echogenic collection extension to the surrounding periventricular parenchyma in the early stages (8). Retraction, lysis, and resorption of the surrounding parenchyma and blood clot will conclude with the formation of a porencephalic cyst, a solid mass-like structure

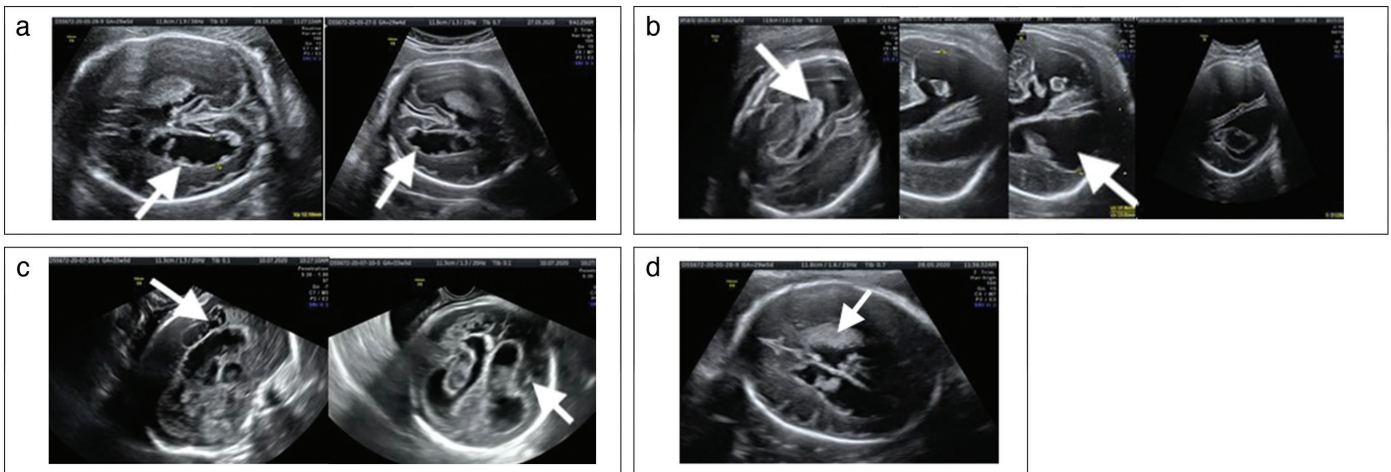
**Table 1. Demographic characteristics, US and MRI findings, and outcomes of the cases**

Case	Age	Gestational week at diagnosis (weeks + days)	Grade of ICH	Ultrasonographic findings	MRI findings	Outcome	Gestational week at delivery (weeks + days)	Type of delivery
1	20	36	Gr 3	- Ventriculomegaly (39/33 mm) - Intraventricular hyperechogenic foci suggesting clots	- Ventriculomegaly (32/35 mm) - Bilateral intraventricular hyperechogenic foci suggesting clots	- Pregnancy termination	37	Vaginal delivery
2	20	25	Gr3	- Ventriculomegaly (15/22 mm)	-	- IUFD	25	Vaginal delivery
3	25	31+2	Gr3	- Ventriculomegaly (19/21 mm) - Echogenic and irregular lateral ventricle borders - Intraventricular hyperechogenic foci suggesting clots	-	- Died at postnatal 6 <sup>th</sup> months	38	Vaginal delivery
4	26	32+5	Gr 3	- Ventriculomegaly (33/20 mm) - Intraventricular hyperechogenic foci suggesting clots	- Ventriculomegaly (37/25 mm) - Intraventricular hyperechogenic foci suggesting clots (More prominent in the left ventricle)	- Hemiparesis and epilepsy	37	Cesarean Delivery
5	19	30+1	Gr4	- Ventriculomegaly (12/22 mm) - Porencephalic cyst	- Ventriculomegaly (11/21 mm) - Intraventricular hyperechogenic foci suggesting clots - Porencephalic and encephalomalastic cysts in periventricular white matter	- Pregnancy termination	32	Vaginal delivery
6	29	32+6	Gr 4	- Ventriculomegaly (19/14 mm) - Echogenic and irregular lateral ventricle borders - Ventricular leukomalacia	-	- Lost to follow-up	36	Vaginal delivery
7	19	22+1	Gr 4	- Ventriculomegaly (19/20 mm) - Diffuse liquefaction in the parenchyma	-	- Pregnancy termination	23	Vaginal delivery
8	30	28+6	Gr 4	- Ventriculomegaly (13/15 mm) - Echogenic and irregular lateral ventricle borders - Parenchymal hemorrhage	- Ventriculomegaly (16/14 mm) - Parenchymal hemorrhage - Cystic-encephalomalastic changes	- Pregnancy termination	30+5	Vaginal delivery

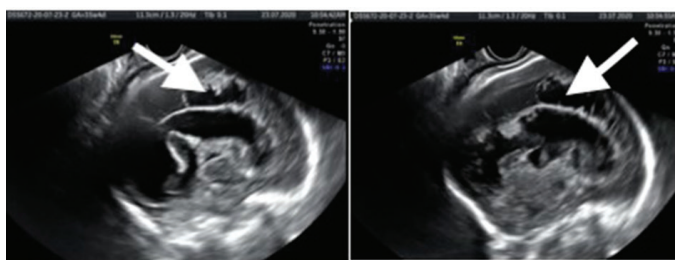
**Table 1. Continued**

Case	Age	Gestational week at diagnosis	Grade of ICH	Ultrasonographic findings	MRI findings	Outcome	Gestational week at delivery	Type of delivery
9	20	35	Gr 3	- Ventriculomegaly (28/28 mm) - Echogenic and irregular lateral ventricle borders	- Ventriculomegaly (32/35 mm) - Intraventricular hyperechogenic foci suggesting clots	- Ventriculoperitoneal shunt placement	38+2	Cesarean delivery
10	21	28	Gr 3	- Ventriculomegaly (14/13 mm) - Echogenic and irregular lateral ventricle borders	- Ventriculomegaly (17/17 mm) - Irregular lateral ventricle borders - Intraventricular hyperechogenic foci suggesting clots	- Hemiparesis and epilepsy	36+3	Vaginal delivery
11	18	32	Gr4	- Ventriculomegaly (26/35 mm) - Echogenic lateral ventricle borders - Parenchyma is liquefied	- Ventriculomegaly (26/35 mm) - Parenchyma is liquefied	- Pregnancy termination	32+3	Vaginal delivery

US: Ultrasound, MRI: Magnetic resonance imagination, ICH: Intracranial hemorrhage, Gr: Grade, IUFD: Intrauterine fetal demise



**Figure 1. (a) Echogenic, irregular and nodular lateral ventricle borders. (b) Intraventricular hyperechogenic foci suggesting clots with unilateral and bilateral ventriculomegaly (arrow). (c) Periventricular hypoechoic nodules (arrow). (d) Periventricular leukomalacia (arrow)**



**Figure 2. Porencephalic cyst (arrow)**

composed of the infarcted brain and blood clot (3). This cyst commonly becomes evident about two weeks after the initiation of hemorrhage (8).

Fetal and maternal risk factors have been associated with fetal ICH. Predisposing fetal risk factors include fetal alloimmune thrombocytopenia, umbilical cord entanglement, umbilical cord thrombosis, fetal thrombophilia, the demise of a co-twin in monochorionic placentation, TTTS, severe hypoxia, and severe IUGR. Maternal risk factors include vitamin K deficiency, pregnancy complications (placental abruption, preeclampsia), infections, immune thrombocytopenia, coagulation disorders,

seizures, trauma, medications (warfarin), and drugs (3,7,13). However, previous studies reported that in the majority of cases no identifiable risk factor was found and identified fetal and maternal pathologies that may have caused the fetal ICH are only present in 20-45% of cases (6,8,13,14). In this study, no identifiable etiologic factor was detected in any of the cases. However, maternal serological testing was performed in 8/11 cases with no abnormalities found.

The mean gestational age at the time of diagnosis in this study cohort was 30.2 weeks. This finding was consistent with previous studies (6-8,13,14). All cases suffered from bilateral fetal ICH, similar to previous reports (7,13). All cases were grade 3 and 4, and consistent with those of previous studies, where incidence of these grades ranged from 70% to 100% (7,12,13). Grade 1 fetal ICH was rarely reported since the findings are subtle and are easily missed in the standard axial planes used on US examination.

The neurodevelopmental outcomes of the fetuses affected by ICH are still unclear due to the paucity of data in the literature. Also, differing pregnancy termination rates and the heterogeneity of the etiology in fetal ICH or concomitant comorbidities make it difficult to evaluate the results. Previous studies reported that there was a significant association between the grade and location of the hemorrhage and the occurrence of severe neurologic complications (15,16). Cases with grade 2 ICH are reported to have good outcomes, with a survival rate of 100% and only 10% suffer from mild neurologic sequelae. Also, in lower grades of hemorrhage, complete disappearance of abnormal US findings may be observed with better postnatal neurologic consequences (3,8,13). However, evidence concerning outcome in grade 1 and 2 fetal ICHs is limited and these grades were absent from the present study. Grade 3 and 4 hemorrhages are associated with poorer neonatal outcomes than the lower grade fetal ICHs. Ghi et al. (8) reported that no losses were reported in fetuses with grade 1 and 2 hemorrhages and 72% of these infants showed healthy neurologic development. However, only 41% of infants staged as grade 3 and 4 were considered neurodevelopmentally normal (8). A recent study reported that 2/3 of infants with grade 3 fetal ICH suffered from adverse neurologic outcomes (3). In our study cohort, 45.5% (5/11) were born alive at term, with no postnatal deaths. Of these, two cases suffered from epilepsy and hemiparesis while the other three (60%) were reported to exhibit healthy neurologic development.

In most fetal ICH cases, the sonographic signs were detected between 28 and 33 weeks of pregnancy. However, Anderson and McGahan (17) stated that fetal ICH may be identified between 18-20 weeks of gestation. Previous studies demonstrated that US examination provided an accurate diagnosis with no false-positive results (6,8,13). However, blood clots may undergo

complete resolution and disappear, ventriculomegaly resolves and thus may be observed as a healthy brain appearance in later US examination. These US features make the prenatal diagnosis challenging (12). Therefore, fetal ICH should be considered in the differential diagnosis of ventriculomegaly cases in the prenatal period.

The role of fetal MRI in the diagnosis, grading, and evaluation of fetal ICH is still controversial and dependent on clinician experience (6,8). Previous studies postulated that fetal MRI is a beneficial adjunct to US examination in the examination of fetal ICH or ischemic lesions and provides information differing from other imaging techniques (3,6,8). Ghi et al. (8) reported that US examination was always diagnostic in fetal ICH cases, and MRI, when performed, proved accurate but did not add further information about the case. They stated that MRI has a role at least in those patients where the US examination is inconclusive (8). Kutuk et al. (6) demonstrated that MRI confirmed the diagnosis made by the US and defined the hematoma dimension, bleeding zone, and eliminated other intracranial abnormalities, particularly in fetuses with grade 3 and 4 ICHs. In the case series of Adiego et al. (3), MRI accurately detect the location and grade of the ICH, and provided additional information concerning the etiology of ICH in one case. In this cohort, fetal cranial MRI was performed in seven (63.6%). In these cases, MRI confirmed the diagnosis, bleeding region and grade of the hemorrhage detected by US examination. However, fetal MRI did not provide additional information. This may be because the study cohort consisted only of fetuses with grade 3 and 4 hemorrhage. It should be noted that we performed fetal MRI within seven days of US evaluation, eliminating the probability of up-grading of the fetal ICH between US and MRI investigations. It seems reasonable to combine MRI with US in the evaluation of the fetuses with lower grade ICH. This may help in identifying the predisposing factors of the hemorrhage.

### Study Limitations

There are some limitations of this study, including its retrospective design, an absence of autopsy information and the small sample size. Also, the lack of grade 1 and 2 fetal ICH cases may lead to biased outcomes due to the high termination rate in grade 4 ICH. The absence of serologic testing in three cases may be considered another limitation of this study. Moreover, we did not perform three-dimensional (3D) sonography in the assessment of ICH. Pooh and Kurjak (18) demonstrated that a 3D US scan was superior to an MRI in the evaluation of normal and abnormal CNS findings. Further studies with larger cohorts, including all grades of ICH, are needed to compare 3D US scan findings with those of MRI.

## Conclusion

The clinical manifestations of fetal ICH are diverse and have a wide spectrum of severity and prognostic implications. Fetal ICH cases were mainly detected in the third trimester, with a minority detected in the second trimester. These cases can be safely diagnosed and graded using US examination, but the underlying etiology is often not determined. Fetal cranial MRI appears to add little additional information but may provide some information as to the etiology of fetal ICH. Further studies are required, with larger cohorts should be performed to compare 3D US and MRI in affected fetuses. Combined use of US and MRI may also enable appropriate counseling to the parents.

**Ethics Committee Approval:** *The study protocol was approved by the University of Health Sciences Turkey, Kanuni Sultan Süleyman Training and Research Hospital Institutional Ethics Committee (approval number: 2020.12.226).*

**Informed Consent:** *A written informed consent form was obtained from all parents.*

**Peer-review:** *Externally peer-reviewed.*

**Author Contributions:** *Surgical and Medical Practices: Z.G.Ö., A.B., M.B., S.S.Ç., İ.Ö.; Concept: Z.G.Ö., S.C.O., A.B., M.B., S.S.Ç., F.Ö., İ.Ö.; Design: Z.G.Ö., S.C.O., A.B., M.B., S.S.Ç., F.Ö., İ.Ö.; Data Collection or Processing: Z.G.Ö., A.B., M.B., S.S.Ç.; Analysis or Interpretation: Z.G.Ö., S.C.O., A.B., M.B., S.S.Ç., F.Ö., İ.Ö.; Literature Search: Z.G.Ö., S.C.O., A.B.; Writing: Z.G.Ö., S.C.O.; Critical Review: Z.G.Ö., S.C.O., F.Ö.*

**Conflict of Interest:** *No conflict of interest is declared by the authors.*

**Financial Disclosure:** *The authors declared that this study received no financial support.*

## References

- Sanapo L, Whitehead MT, Bulas DI, Ahmadzia HK, Pesacreta L, Chang T, et al. Fetal intracranial hemorrhage: role of fetal MRI. *Prenat Diagn* 2017; 37: 827-36.
- Society for Maternal-Fetal Medicine (SMFM), Monteagudo A. Intracranial Hemorrhage. *Am J Obstet Gynecol* 2020; 223: B34-7.
- Adiego B, Martínez-Ten P, Bermejo C, Estévez M, Recio Rodriguez M, Illescas T. Fetal intracranial hemorrhage. Prenatal diagnosis and postnatal outcomes. *J Matern Fetal Neonatal Med* 2019; 32: 21-30.
- Qi W, Luo JY, Li ZL, Zhang QJ, Liu ZD, Liao QP, et al. Clinical analysis of eight cases of fetal intracranial hemorrhage in pregnancy. *J Matern Fetal Neonatal Med* 2021; 16: 2609-15. 1-7.
- Carletti A, Colleoni GG, Perolo A, Simonazzi G, Ghi T, Rizzo N, et al. Prenatal diagnosis of cerebral lesions acquired in utero and with a late appearance. *Prenat Diagn* 2009; 29: 389-95.
- Kutuk MS, Yikilmaz A, Ozgun MT, Dolanbay M, Canpolat M, Uludag S, et al. Prenatal diagnosis and postnatal outcome of fetal intracranial hemorrhage. *Childs Nerv Syst* 2014; 30: 411-8.
- Abdelkader MA, Ramadan W, Gabr AA, Kamel A, Abdelrahman RW. Fetal intracranial hemorrhage: sonographic criteria and merits of prenatal diagnosis. *J Matern Fetal Neonatal Med* 2017; 30: 2250-6.
- Ghi T, Simonazzi G, Perolo A, Savelli L, Sandri F, Bernardi B, et al. Outcome of antenatally diagnosed intracranial hemorrhage: case series and review of the literature. *Ultrasound Obstet Gynecol* 2003; 22: 121-30.
- Putbrese B, Kennedy A. Findings and differential diagnosis of fetal intracranial haemorrhage and fetal ischaemic brain injury: what is the role of fetal MRI? *Br J Radiol* 2017; 90: 20160253.
- Malinger G, Paladini D, Haratz KK, Monteagudo A, Pilu GL, Timor-Tritsch IE. ISUOG Practice Guidelines (updated): sonographic examination of the fetal central nervous system. Part 1: performance of screening examination and indications for targeted neurosonography. *Ultrasound Obstet Gynecol* 2020; 56: 476-84.
- Oğlak SC, Bademkiran MH, Obut M. Predictor variables in the success of slow-release dinoprostone used for cervical ripening in intrauterine growth restriction pregnancies. *J Gynecol Obstet Hum Reprod* 2020; 49: 101739.
- Huang YF, Chen WC, Tseng JJ, Ho ES, Chou MM. Fetal intracranial hemorrhage (fetal stroke): report of four antenatally diagnosed cases and review of the literature. *Taiwan J Obstet Gynecol* 2006; 45: 135-41.
- Elchalal U, Yagel S, Gomori JM, Porat S, Beni-Adani L, Yanai N, et al. Fetal intracranial hemorrhage (fetal stroke): does grade matter? *Ultrasound Obstet Gynecol* 2005; 26: 233-43.
- Strigini FA, Cioni G, Canapicchi R, Nardini V, Capriello P, Carmignani A. Fetal intracranial hemorrhage: is minor maternal trauma a possible pathogenetic factor? *Ultrasound Obstet Gynecol* 2001; 18: 335-42.
- Jocelyn LJ, Casiro OG. Neurodevelopmental outcome of term infants with intraventricular hemorrhage. *Am J Dis Child* 1992; 146: 194-7.
- Winkelhorst D, Kamphuis MM, Steggerda SJ, Rijken M, Oepkes D, Lopriore E, et al. Perinatal outcome and long-term neurodevelopment after intracranial haemorrhage due to fetal and neonatal alloimmune thrombocytopenia. *Fetal Diagn Ther* 2019; 45: 184-91.
- Anderson MW, McGahan JP. Sonographic detection of an in utero intracranial hemorrhage in the second trimester. *J Ultrasound Med* 1994; 13: 315-8.
- Pooh RK, Kurjak A. Novel application of three-dimensional HDlive imaging in prenatal diagnosis from the first trimester. *J Perinat Med* 2015; 43: 147-58.