



Society of Robotic Gynecologic Surgery



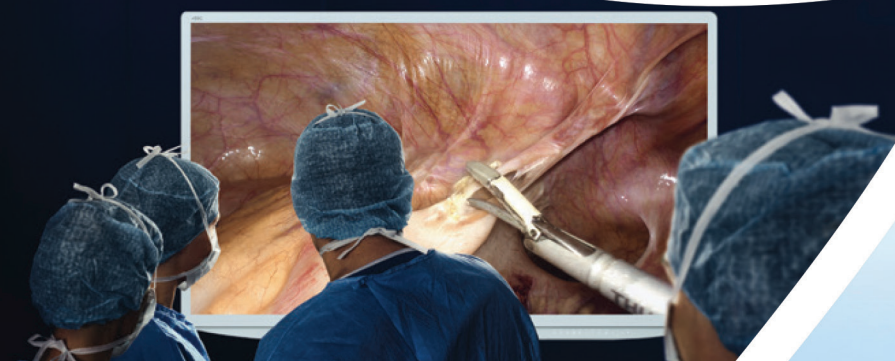5th SEERSS

1st GynOncoMIS and Robotic Surgery Congress

December 15-18, 2016

Hilton Bomonti
Istanbul, Turkey

www.seerss2016.org



*5th SEERSS 1st GynoOncoMIS and Robotic
Surgery Congress Abstracts*

Video Presentation

VP-01

Laparoscopic type III radical hysterectomy

Mehmet Ali Vardar, [Ahmet Barış Güzel](#),
Ümran Küçükğöz Güleç, Ghanim Khatib

Department of Obstetrics and Gynecology, Division of Gynecologic Oncology, Çukurova University Faculty of Medicine, Adana, Turkey

We will present as a video form.

Keywords: Radical, hysterectomy, laparoscopy

VP-02

Laparoscopic pelvic and paraaortic lymphadenectomy treatment of endometrial cancer

[Ahmet Barış Güzel](#), Mehmet Ali Vardar,
Ümran Küçükğöz Güleç, Ghanim Khatib

Department of Obstetrics and Gynecology, Division of Gynecologic Oncology, Çukurova University Faculty of Medicine, Adana, Turkey

We will present as a video form.

Keywords: Laparoscopy, lymphadenectomy, endometrial cancer

VP-03

Robotic excision of deep pelvic endometriotic nodule

[Fatema Adel Alkhan](#), Mehmet Faruk Köse, Mehmet Murat Naki

Department of Obstetrics and Gynecology, Acibadem Atakent University Hospital, İstanbul, Turkey

Thirty years old lady presented with history of left flank pain. Patient seen by urologist and MRI showed left renal pelvis hydronephrosis with dilatation of ureter. Cystoscopy done biopsy collected and pathology showed endometriosis. Therefore, patient referred to our department for further management.

Keywords: Deep infiltrative endometriotic nodule, robotic, renal hydronephrosis

VP-04

Robotic resection of bulky conglomerate of pelvic lymph nodes in a cervical cancer patient

[Tayfun Toptaş](#)¹, Işın Üreyen¹, Aysel Uysal²

¹*Department of Gynecologic Oncological Surgery, Antalya Training and Research Hospital, Antalya, Turkey*

²*Department of Obstetrics and Gynecology, Antalya Training and Research Hospital, Antalya, Turkey*

Objective: We aimed to present a video demonstration of robotic resection of bulky pelvic lymph nodes incidentally found during lymphadenectomy for early stage cervical cancer.

Material and Methods: A brief video presentation of a radical surgery that we performed using daVinci® XI robotic system in a patient with endocervical adenocancer.

Results: A 31-year-old woman admitted to our clinic with a cervical cancer screening test results of positive HPV test (type 16) and negative cytology. Colposcopy revealed major findings including dense acetowhite epithelium inside the transformation zone extending into endocervical canal more than 5 mm. Histopathological examination of endocervical curettage was consistent with adenocarcinoma in situ. She underwent cold-knife cone biopsy which revealed a diagnosis of endocervical adenocancer with a depth of stromal invasion of 4 mm and horizontal spread of 6 mm, positive LVSI and negative cone margins. A definitive surgery consisting of modified radical hysterectomy, pelvic lymphadenectomy and bilateral ovarian transposition was planned. Surgery was initiated with the performance of right pelvic lymphadenectomy. During the dissection, a 3x3 cm conglomerate of bulky hypogastric lymph nodes, densely attached to the ureter, hypogastric artery and external iliac vein, was detected. LNs was resected with fine and blunt dissection using monopolar scissors. No complication was observed. Frozen section examination revealed a positive result for LN metastasis. Radical hysterectomy was abandoned and the operation was terminated following bilateral ovarian transposition was carried out.

Conclusion: Bulky lymph node metastasis can occur in cervical cancer even in case of lack of deep stromal invasion. Robotic surgery may enhance dissection capability of surgeon in cases with densely adherent tumor.

Keywords: Cervical cancer, robotic surgery, bulky lymph node metastasis

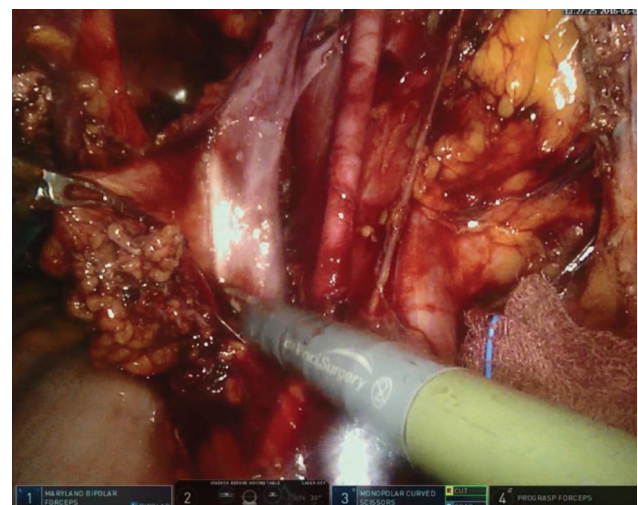


Figure 1. Right hypogastric bulky lymph node

VP-05

Laparoscopic blinded endometrial cavity resection for Robert's uterus

Hüseyin Kiyak, Lale Susan Türkgeldi, Rabia Erbiyik, İbrahim Polat

Department of Obstetrics and Gynecology, İstanbul Health Science University, Kanuni Sultan Süleyman Training and Research Hospital, İstanbul, Turkey

Robert's uterus is a rare Müllerian duct anomaly characterized by a blind endometrial cavity and an asymmetrical uterine septum. A 15 year old virgin patient presented to the gynecology clinic with a history of progressively increasing colicky lower abdominal pain and dismenorhea. The patient underwent laparoscopic surgery and no indentations could be visualized on the fundus or outer border of the uterus during exploration. However the right fallopian tube appeared agenetic and the right side of the uterus appeared distended due to menstrual blood retention. The left fallopian tube appeared normal and the patient was diagnosed with Robert's uterus. The blind endometrial cavity was excised totally with harmonic scapel. The patient was discharged on the first postoperative day without any complications. Upon follow-up the patient reported that her dismenorhea symptoms had resolved totally. The aim during treatment is to either provide a communication between the blind cavity and the patent hemicavity or to excize the blind cavity totally. This can be carried out by laparotomy, laparoscopy or hysteroscopy. The total excision of of the blind cavity by laparoscopy is a safe and effective treatment modality which does not adversely affect the hemiuterus or its blood supply.

Keywords: Robert's uterus, endometrectomy, laparoscopy

VP-06

Laparoscopic obturator nerve repair: A video presentation

Özgüç Takmaz¹, Esra Özbaşı², Savaş Gündoğan², Mete Güngör²

¹*Department of Obstetrics and Gynecology, Acibadem Maslak Hospital, İstanbul, Turkey*

²*Department of Obstetrics and Gynecology, Acibadem University Faculty of Medicine, İstanbul, Turkey*

Objective: To demonstrate epineural repairment of iatrogenically injured obturator nerve during pelvic lymphadenectomy.

Material and Methods: A surgical video presentation of laparoscopic repairment of an iatrogenically transected obturator nerve with an ultrasonic energy device. Case: A 50 year-old woman who had diagnosis of endometrial adenocarcinoma was referred to Acibadem Maslak Hospital for laparoscopic staging surgery. She had no significant previous medical and surgical history. During right pelvic lymphadenectomy, obturator nerve was transected totally via

ultrasonic energy device. After completion of lymphadenectomy, proximal and distal ends of the right obturator nerve were identified. A 3.0 poliglactin u-suture was placed to the edges of the nerve, and epineural end-to-end enclosing was completed.

Results: Patient had no motor or sensory loss of function clinically. She was discharged postoperative day two. During 3 month follow ups, she had no complaint related with obturator nerve.

Conclusion: Obturator nerve is a land mark for pelvic lymphadenectomy in gynecologic cancer surgery. During pelvic lymphadenectomy obturator nerve is at risk of injury. Transection of obturator nerve can be made with sharp dissection or with an electro/ultrasonic surgical device. As a result of the obturator nerve transection, weakness in the adduction of thigh, sensory loss or pain of the medial thigh can be seen clinically. After transection, immediate repair of the nerve should be considered. To prevent functional loss and to restore anatomy, epineural end to end coaptation is considered preferable method. As in our case, repairing obturator nerve immediately after injury usually produces favorable results.

Keywords: Laparoscopy, obturator nerve, nerve repair

VP-07

A simple new method for laparoscopic sacrocervicopexy

Adnan Orhan, Işıl Kasapoğlu, Mehmet Aral Atalay, Bahadır Koşan, Sevde Nur Mert, Kemal Özerkan

Department of Obstetrics and Gynecology, Uludağ University Training and Research Hospital, Bursa, Turkey

Objective: We are demonstrating a new technique for laparoscopic sacrocervicopexy for uterine prolapse in this video abstract.

Material and Methods: The first part is the vaginal procedure. We use a polypropylene macroporous T-shaped mesh to fix it to the cervix. We dissect anterior and posterior of the cervix like in the mcdonald cerclage operation and place the head of the mesh around the cervix with suturing non-absorbable 2.0 prolene sutures. After that tail of the T-shaped mesh is passed with the clamps between the sacrouterine ligaments from rectouterine space to the abdomen. In the second part we perform laparoscopy. We dissect the peritoneum and rectum down and take the mesh from vagina. We use laparoscopic tacker with stainless steel tack to fix the mesh in tension free manner to the sacrum and anterior longitudinal ligament. After that we close the peritoneum with polyglactine 2.0 sutures and finish the operation.

Results: We perform this operation on 42 patient from 2010-2016 in our tertiary referral university teaching hospital. Mean age of the patients is 36.7 years old. After 1 year follow-up; all of the patients but one have sufficient vagina in pelvic examination. Average C point lifting was 6.1 cm. Thirty-one patients reported satisfied sexual intercourse. Three patients reported disparunia. Seven of 42 patients who had symptoms of stress or urge incontinence preoperatively, didn't undergo any concomitant continence surgery. Four of these patients reported subjective improvement of their incontinence after one year. There was only one complication which is a mesh erosion and excised laparoscopically.

Conclusion: This method can be an alternative to the traditional vaginal methods and classical laparoscopic sacrocervicopexy. Although it has not long term results and there is not enough patients who undergone this operation, the technique can be considered as a simple, easier and feasible surgical method.

Keywords: Sacrocervicopexy, laparoscopy, urogynecology, new method

VP-08

Transvaginal extraction for myoma retrieval by using CCL vaginal extractor without power morcellation in robotic surgery

Selim Mısırlıoğlu¹, Tonguç Arslan², Çağatay Taşkiran³, Bülent Urman³

¹Department of Obstetrics and Gynecology, Vehbi Koç Foundation Koç University Faculty of Medicine Hospital, İstanbul, Turkey

²Department of Obstetrics and Gynecology, Vehbi Koç Foundation American Hospital, İstanbul, Turkey

³Department of Gynecologic Oncology, Vehbi Koç Foundation Koç University Faculty of Medicine and American Hospital, İstanbul, Turkey

A 34 years old woman was admitted with lower abdominal pain and infertility. Multiple myomas were found on pelvic examination and transvaginal sonography. Robotic myomectomy was suggested to preserve the uterus. At the end of the surgery, CCL vaginal extractor (manufactured by STORZ) was used to remove the myomas without power morcellation. The purpose of this video article is to demonstrate the transvaginal retrieval method during robotic myomectomy.

Keywords: Robotic surgery, transvaginal extraction, myoma

VP-09

Laparoscopic Hysterectomy for Intraligamentary Myoma

Nejat Özgül, Gökhan Boyraz

Department of Gynecologic Oncology, Hacettepe University Faculty of Medicine, Ankara, Turkey

A case of a 54 year-old patient with abdominal pain. The gynecologic ultrasonography revealed 95 mm *844 mm solid mass on left adnex. Ca 125 and other tumor markers were normal. Laparoscopic hysterectomy and bilateral salpingo oophorectomy was performed. Permanent pathology: degenerative myoma.

Keywords: Myoma, laparoscopy, broad ligament

VP-10

Step by step bag morcellation in laparoscopic myomectomy

Selim Mısırlıoğlu¹, Ayşen Boza², Sertan Aksu², Tonguç Arslan², Barış Ata³, Çağatay Taşkiran³, Bülent Urman³

¹Department of Obstetrics and Gynecology, Vehbi Koç Foundation Koç University Faculty of Medicine Hospital, İstanbul, Turkey

²Department of Obstetrics and Gynecology, Vehbi Koç Foundation American Hospital, İstanbul, Turkey

³Department of Gynecologic Oncology, Vehbi Koç Foundation Koç University Faculty of Medicine and American Hospital, İstanbul, Turkey

The Morsafe tissue isolator bag has been designed and is specifically indicated for morcellation and as a result offers significant features and benefits that cannot be duplicated by other non-indicated bags being considered. Morsafe, with its unique two port design, offers the surgeon superior visibility during the surgery. It also contains a special ring in the bag opening to allow the surgeon ultimate control of the bag opening and easy access to the interior of the bag during surgery. The aim of this video is to demonstrate the each step of bag morcellation during laparoscopy. This video is included inserting the isolation bag into the abdomen, where tissue slated for removal was placed within the bag. The surgeon then pulled the opening of the bag to the exterior of the abdomen, inflated the bag, and fragmented the tissue within the bag to contain and remove it. After each procedure, the surgeon visually inspected the isolation bag for tears, as well as the abdominal and peritoneal cavities for tissue pieces left behind. At the end, Versator tissue morcellator can morcellate large tissue quickly, efficiently and safely.

Keywords: Laparoscopy, myomectomy, bag morcellation

VP-11

Laparoscopic versus robotic hysterectomy

Mehmet Ali Vardar, Ahmet Barış Güzel, Ümran Küçüköz Güleç, Ghanim Khatib

Department of Obstetrics and Gynecology, Division of Gynecologic Oncology, Çukurova University Faculty of Medicine, Adana, Turkey

We will present as a video form.

Keywords: Laparoscopy, robot, hysterectomy

VP-12

The presentation of 2 cases which have been operated due to the testicular feminization

Kadir Güzin, Halenur Bozdağ, Kemal Sandal, Ece Çelikbaş, Ateş Karateke

Department of Obstetrics and Gynecology, İstanbul Medeniyet University, Göztepe Training and Research Hospital, İstanbul, Turkey

The presentation of 2 cases which have been operated due to the testicular feminization;

Case 1: H.B. 18 years old. She was diagnosed with 17-hydroxylase insufficiency due to the homozygote mutation in *CYP17* gene. Since the patient's karyotype is 46,XY and there is a risk of malignancy, her gonads were removed from the inguinal canal bilaterally with laparotomy.

Case 2: A.D. 16 years old. L/S gonadectomy case presentation due to the testicular feminization. Her gonads were removed from the abdomen in which the ovaries were placed via laparoscopy. The size of uterus were observed as 4x3 cm.

Keywords: testicular feminization, gonadectomy, 17-hydroxylase insufficiency

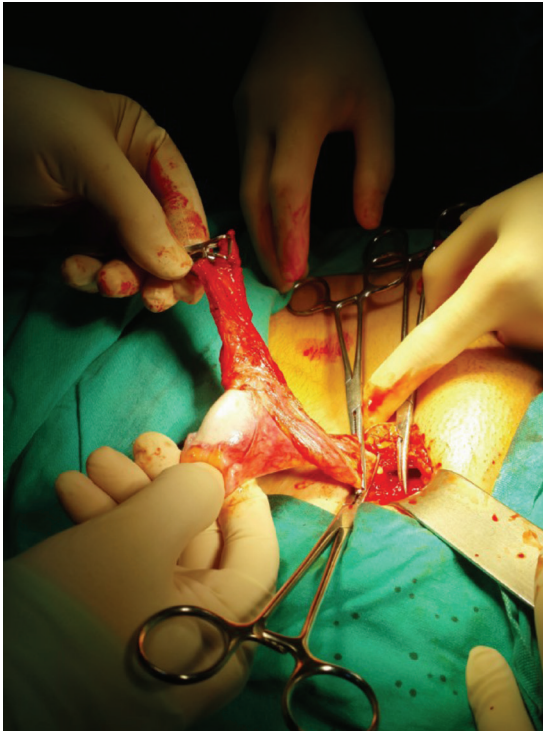

Figure 1. Gonadectomy from inguinal canal

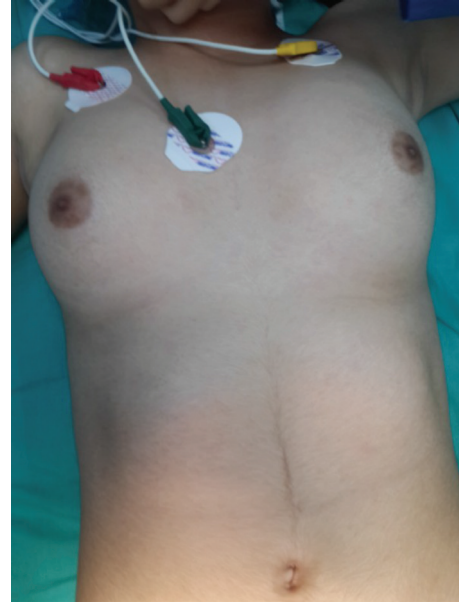


Figure 2. Testicular feminisation, patient

VP-13

Single port robotic assisted laparoscopic hysterectomy: A video presentation

Özgüç Takmaz¹, Esra Özbaşlı², Savaş Gündoğan², Mete Güngör²

¹Department of Obstetrics and Gynecology, Acıbadem Maslak Hospital, İstanbul, Turkey

²Department of Obstetrics and Gynecology, Acıbadem University Faculty of Medicine, İstanbul, Turkey

Objective: To demonstrate single port robotic hysterectomy.

Material and Methods: A surgical video presentation of single port robotic assisted (RASS) laparoscopic hysterectomy. Operation time was defined as the time from intubation to the end of extubation. Setup time was defined as the time from first incision to the end of the docking of the robotic arms. Estimated blood loss (EBL) was calculated from the difference between irrigation and suction fluid volumes. Case: A 53-year-old woman who had 8 months of medical treatment for resistant uterine bleeding underwent RASS laparoscopic hysterectomy. She had no significant medical or operative history.

Results: Operation time was 160 min, EBL was 30ml and no perioperative complication occurred. The patient was discharged the day after surgery. No significant pathology was revealed by histopathological examination.

Conclusion: Minimal invasive procedures improve perioperative outcomes in gynecologic procedures (1). Evidence shows single port laparoscopic hysterectomy has comparable operative outcomes compared with traditional laparoscopy and also better cosmetics and less port site complications (2, 3). Following the

single port laparoscopic procedures, RASS surgery is the very last promising procedure for gynecologic minimal invasive surgery. And also RASS hysterectomy has comparable outcomes compared with classic multi-port hysterectomy (4). RASS surgery brings some advantages (greater dexterity, better visualisation, less instrument crowding or more triangulation) to single site laparoscopic surgery, however there are several limitations such as nonarticulated instruments, limited electrosurgical options, instrument clashing and higher costs. RASS may find a broader application area in gynecologic surgeries in near future if these technical challenges can be overcome.

Keywords: Single port robot, single site, hysterectomy

VP-14

Laparoscopic hysterectomy in bulky uterus

Mehmet Ali Vardar, [Ahmet Barış Güzel](#),
Ümran Küçüköz Güleç, Ghanim Khatib

Department of Obstetrics and Gynecology, Division of Gynecologic Oncology, Çukurova University Faculty of Medicine, Adana, Turkey

We will present as a video form.

Keywords: Laparoscopy, bulky, difficult

VP-15

Laparoscopic bulky lymphadenectomy

Ümran Küçüköz Güleç, [Ahmet Barış Güzel](#),
Mehmet Ali Vardar, Ghanim Khatib

Department of Obstetrics and Gynecology, Division of Gynecologic Oncology, Çukurova University Faculty of Medicine, Adana, Turkey

We will present as a video form.

Keywords: Laparoscopy, lymphadenectomy, bulky lymph node

VP-16

Robotic repair of central cystocele with vaginal sacroplexy suspension

[Fatema Adel Alkhan](#), Mehmet Murat Naki, Mehmet Faruk Köse

Department of Obstetrics and Gynecology, Acibadem Atakent University Hospital, Istanbul, Turkey

A 63 years old lady presented with swelling of anterior vaginal wall. Patient examined and diagnosed to have grade 3 central cystocele. Therefore, patient posted for robotic repair.

Keywords: Central cystocele, sacroplexy, robotic

VP-17

Laparoscopic management of incidental obturator nerve injury during pelvic lymphadenectomy

[Mert Göl](#)

Department of Obstetrics and Gynecology, Near East University Faculty of Medicine, Nicosia, Cyprus

Minimal invasive surgery is now accepted in endometrial cancer as the main type of surgery as prognosis of the patients and harvested lymph nodes count do not decrease compared to laparotomy. Furthermore, in cervical cancer and even in early stage of ovarian cancer minimal invasive surgery has promising results.

In this video we present a patient with endometrial cancer 1B Grade 3 who underwent laparoscopic pelvic and paraaortic lymphadenectomy. We present here important anatomical landmarks to be aware of during dissection to avoid complications. Furthermore here we present some tips to visualise anatomical planes clearly to facilitate the surgery.

Keywords: Laparoscopy, pelvic, paraaortic, lymph node

VP-18

Morcellation of large and multiple myomas in a safety compartment

[Gonca Çoban](#), Songül Alemdaroğlu, Gülşen Durdağ,
Hüsnü Çelik

Department of Gynecologic Oncology, Başkent University Faculty of Medicine, Adana, Turkey

Objective: To explain the details of the Safe Compartment Technique (SCT) developed to prevent dissemination resulting from morcellation used to remove huge and multiple myomas during laparoscopic surgery.

Material and Methods: The SCT we routinely perform during myomectomy.

Results: The technique was successfully performed in all cases. The mean time it took to create the safe compartment was found to be 4 ± 1 minutes.

Keywords: Myoma, safety, morcellation

VP-19

Deep pelvic endometriosis with infiltrating ureter

Gonca Çoban, Songül Alemdaroğlu, Pınar Çağlar Aytaç, Hüsni Çelik

Department of Gynecologic Oncology, Başkent University Faculty of Medicine, Adana, Turkey

Objective: We aim to detailed laparoscopic deep endometriosis surgery.

Material and Methods: We performed laparoscopic pelvic deep endometriosis surgery with ureter dissection.

Results: Laparoscopic management of deep pelvic endometriosis with minimal complications.

Keywords: Deep endometriosis, laparoscopic surgery, infiltrating ureter

VP-20

Step by step laparoscopic sacrocolpopexy

Gonca Çoban, Songül Alemdaroğlu, Seda Yüksel Şimşek, Hakan Kalaycı, Hüsni Çelik

Department of Gynecologic Oncology, Başkent University Faculty of Medicine, Adana, Turkey

Objective: Describe to laparoscopic sacropexy is a valid option women presenting with genital prolapse.

Material and Methods: We performed laparoscopic sacrocolpopexy for total uterine prolapse saving uterus, using a permanent polypropylene Y-mesh standard operative technique for sacrocolpopexy was used. Two-three sutures were placed on the anterior vesico-cervical fascia. Two sutures were placed in the presacral ligament. Mesh was retroperitonealized with a running 2-0 monocryl suture.

Results: Traditional laparoscopic sacrocolpopexy should be considered a primary therapy for vaginal vault prolapse.

Keywords: Laparoscopic, sacrocolpopexy, total uterine prolapse

VP-21

Laparoendoscopic single site hysterectomy

Gökhan Demirayak, Çağlar Helvacıoğlu, Cihan Comba, Hüseyin Cengiz, Cihan Kaya, İsa Aykut Özdemir

Department of Obstetrics and Gynecology, Bakırköy Dr. Sadi Konuk Training and Research Hospital, İstanbul, Turkey

The aim of this presentation is to show a laparoendoscopic single-site (LESS) hysterectomy case. Currently, most gynecological surgeries, including radical ones, can be performed via laparoendoscopic single-site surgery. 54 years old woman with cervical intraepithelial neoplasia 3 (CIN 3) was operated by using this technique. LESS hysterectomy is safe and feasible technique.

Keywords: Laparoendoscopic single site hysterectomy, single port hysterectomy, single port access total laparoscopic hysterectomy (SPA-TLH)

VP-22

Laparoscopic resection of bladder endometriosis

Selim Mısırlıoğlu¹, Bülent Urman², Sertan Aksu³, Tonguç Arslan³, Ayşen Boza³, Özgür Öktem², Barış Ata², Çağatay Taşkiran²

¹*Department of Obstetrics and Gynecology, Vehbi Koç Foundation Koç University Faculty of Medicine Hospital, İstanbul, Turkey*

²*Department of Gynecologic Oncology, Vehbi Koç Foundation Koç University Faculty of Medicine and American Hospital, İstanbul, Turkey*

³*Department of Obstetrics and Gynecology, Vehbi Koç Foundation American Hospital, İstanbul, Turkey*

A 33-year-old woman was referred to us with urinary storage symptoms and severe pelvic pain. She had Gravida 2 with Cesarean sections. On Pelvic MRI, 2x3 cm suspected endometriotic lesion was detected over the fundal part of bladder. Laparoscopic surgery was planned and sacro-uterine nodul excision, endometrioma cyst excision and partial bladder excision was performed. During the postoperative period, folet catheter was kept 7 days after surgery, and spontan urination was started at 8 hours after removing of foley. Patient were followed-up at least 3 months after surgy without any complication.

Keywords: Laparoscopy, endometriosis, bladder resection

VP-23

Laparoscopic dermoid cyst excision in an endobag

Mustafa Ulubay, Uğur Keskin, Ulaş Fidan, Serkan Bodur, Ramazan Erda Pay, Müfit Cemal Yenen

Department of Obstetrics and Gynecology, University of Health Sciences, Gülhane Faculty of Medicine, Ankara, Turkey

This video presentation demonstrates removal of a dermoid cyst inside the same bag without any spillage. Dermoid cyst excision in a bag seems to be a feasible method to prevent intraperitoneal spillage and to reduce the operative time.

Keywords: Dermoid cyst, mature cystic teratom, bag

VP-24

Preservation of uterine support in robot-assisted total laparoscopic hysterectomy

Selim Mısırlıoğlu¹, Engin Türkgeldi¹, Tonguç Arslan²,
Bülent Urman³, Çağatay Taşkiran³

¹Department of Obstetrics and Gynecology, Vehbi Koç Foundation Koç University Faculty of Medicine Hospital, İstanbul, Turkey

²Department of Obstetrics and Gynecology, Vehbi Koç Foundation American Hospital, İstanbul, Turkey

³Department of Gynecologic Oncology, Vehbi Koç Foundation Koç University Faculty of Medicine and American Hospital, İstanbul, Turkey

For the robotic surgical procedure we used the 3-arm Robot da Vinci Si system (Intuitive Surgical Inc., Sunnyvale, CA), with side docking. The 4 trocars were placed above the level of the umbilicus with 8 cm from each other, with the trocar for the camera as highest above the umbilicus. We used as robotic instruments for arm 1 the bipolar fenestrated forceps and for arm 2 the unipolar scissor, besides the 3D camera in the central robot arm. The patients' legs were put in boot-type leg holders, and the patients were placed in 25-30° trendelenburg. The abdominal cavity was insufflated with CO₂ to a maximum of 15 mmHg. Round ligaments were cut, and retroperitoneal space was opened. Bilateral ureters were exposed and identified by the gentle and careful dissection along the posterior leaflet of the broad ligament. The uterovesical fold was dissected from the anterior wall of the uterus to clarify the colpotomy area. After that, the infundibulopelvic ligament was grasped, coagulated and transected on both sides. Before coagulation and transection of the uterine arteries, the safety of ureters was confirmed again. Uterine arteries were grasped and coagulated, and then cut bilaterally by using Ligasure 5-mm Blunt Tip LF1537 with the Force Triad generator. After the uterine artery transection, a Clermont-Ferrand surgical uterine manipulator (Storz, Germany) was inserted into the vagina in place of the sharp curette. The plastic rotating blade of uterine manipulator was strongly pushed forward into the anterior vaginal fornix. Colpotomy incision was started from the uppermost middle point of an anterior vagina, and extended to both sides with a monopolar. The vagina was cut from the uppermost part leaving cardinal ligaments maximally on the vaginal side. By using the manipulator's blade, at the uppermost margin of the vagina, ureters remained apart from the transection area, uterosacral and cardinal ligaments were protected, and the vaginal length was preserved maximally.

Keywords: Robotic hysterectomy, uterine manipulator, cardinal ligament

VP-25

Laparoscopic sacrocolpopexy: Modus operandi

Mustafa Ulubay, Uğur Keskin, Ulaş Fidan, Müfit Cemal Yenen
Department of Obstetrics and Gynecology, University of Health Sciences, Gülhane Faculty of Medicine, Ankara, Turkey

Sacrocolpopexy is a surgical technique used to treat vaginal vault or uterine prolapse. The objectives of the procedure are to reduce prolapse and to restore the anatomy and function of the vagina. During the procedure, the apex of the vagina/fundus of the uterus or stump of the cervix is lifted back up to its natural position by attaching a synthetic mesh from the top and back of the vagina to the sacral promontory. The mesh provides the vagina with the right amount of support to keep it in the correct position. We want to present our approach and our modus operandi.

Keywords: Laparoscopy, sacrocolpopexy, pelvic organ prolapse

VP-26

Learning ovarian dermoid cyst excision: Easy or difficult?

Adnan Orhan, Işıl Kasapoğlu, Hamza Furkan Sen, Ebru Sakar, Kemal Özerkan

Department of Obstetrics and Gynecology, Uludağ University Training and Research Hospital, Bursa, Turkey

Objective: In this video abstract we define a simple, easy and effective technique of dissecting the dermoid cyst after iatrogenic rupture.

Material and Methods: If a perforation occurs in laparoscopy, we suture the ruptured site of the cyst with polyglactin 2.0 sutures. So that we can close cyst wall and stop leaking fluid to the abdomen. Most of the cases, one suture is sufficient. After aspirating and cleaning spilled fluid of the cyst, we find another cleavage plan from another clear place of the dermoid cyst. Performing careful and meticulous dissection, we extract dermoid cyst in an endoscopic bag and suture ovarian incision with 2.0 polyglactine sutures.

Results: We use this method especially in laparoscopic trainings. All of the laparoscopic trainings and operations are performed under supervision of an advanced pelvic surgeon in our gynecologic laparo-endoscopy unit. If a resident or an assistant doctor rupture while dissecting dermoid cyst, the supervisor pelvic surgeon suture perforated site and begin dissecting with another anatomic plan. If it recurs in second operation of the trainee, then he/she proceed with suturing under supervision.

Conclusion: This is a very simple but effective and easy technique for dermoid cyst excision in laparoscopic learning curve. Laparoscopic suturing may be difficult for beginners in laparoscopy but we believe that these operations are very suitable for suture learning. Because hemorrhage risk is very low and suturing site is not in a hard place in contrast to laparoscopic myomectomies or hysterectomies.

Keywords: Dermoid cyst, laparoscopy, resident training

VP-27**Robotic surgery for large myoma**

Ümran Küçükgöz Güleç, [Ahmet Barış Güzel](#), Ghanim Khatib, Mehmet Ali Vardar

Department of Obstetrics and Gynecology, Division of Gynecologic Oncology, Çukurova University Faculty of Medicine, Adana, Turkey

We will present as a video form.

Keywords: Robot, large, myomectomy

VP-28**Laparoscopic ureter dissection**

Ghanim Khatib, Ümran Küçükgöz Güleç, [Ahmet Barış Güzel](#), Mehmet Ali Vardar

Department of Obstetrics and Gynecology, Division of Gynecologic Oncology, Çukurova University Faculty of Medicine, Adana, Turkey

We will present as video form.

Keywords: Laparoscopy, ureter, dissection

VP-29**Robotic excision of deep pelvic lymph node metastasis**

[Fatema Adel Alkhan](#), Mehmet Murat Naki, Mehmet Faruk Köse

Department of Gynecologic Oncology, Acıbadem Atakent University Hospital, İstanbul, Turkey

Patient was diagnosed with ovarian cancer. PET/CT showed recurrence of the disease deep in pelvic lymph node. Therefore, the procedure performed.

Keywords: Metastasis, pelvic lymph node, robotic

VP-30**Laparoscopic myomectomy and prophylactic abdominal cerclage operation**

[Yeliz Aykanat](#)¹, Mehmet Murat Naki², Mehmet Faruk Köse²

¹*Department of Gynecology and Obstetrics, Medipol Mega University Hospital, İstanbul, Turkey*

²*Department of Gynecologic Oncology, Acıbadem Atakent University Hospital, İstanbul, Turkey*

A 34 year-old patient married for 10 years admitted to the hospital with history of uterine fibroids and one painless second trimester pregnancy loss that was related to cervical insufficiency. She had no significant uterine abnormality in hysterosalpingography and had ovulation induction for treatment of infertility. Admission examination revealed 6 cm fibroid in the anterior wall of uterus. She was scheduled for laparoscopic myomectomy, informed about cervical insufficiency and the risk of recurrent second trimester losses. Prophylactic laparoscopic abdominal cerclage operation was recommended. She preferred an abdominal cerclage operation at the time of myomectomy. Patient underwent laparoscopic surgery. After removal of 6 cm myoma, myometrium and serosa were approximated by using 2-0 barbed sutures. The vesicouterine peritoneum was opened and dissected off the lower uterine segment, exposing the uterine vessels anteriorly on both sides. A 5-mm nonabsorbable Mersilene polyester suture was placed by passing each needle medial to the uterine vessels from posterior to anterior at the level of the internal cervical os bilaterally. The landmarks for this placement is a distance of 1.5 cm superior and 1 cm lateral to the insertion of the uterosacral ligament on the posterior uterus. The myoma retrieved with power tissue morcellation. Patient got pregnant after ovulation induction treatment 8 months after surgery and delivered a healthy baby at term.

Keywords: Abdominalcerclage, laparoscopy, habituelabortus, prophylacticcerclage

VP-31**Laparoscopic radical hysterectomy**

[Hüsnü Çelik](#), Gonca Çoban, Songül Alemdaroğlu

Department of Gynecologic Oncology, Başkent University Faculty of Medicine, Adana, Turkey

Objective: We describe laparoscopic radical hysterectomy.

Material and Methods: We performed laparoscopic radical hysterectomy for stage Ib1 squamous cell cervical cancer.

Conclusion: The laparoscopic approach, but the magnified visual field in laparoscopy may enable fine manipulation, especially for preserving autonomic nerve tracts for cervical cancer surgery.

Keywords: Laparoscopic, radical hysterectomy, cervical cancer

VP-32**Laparoscopic radical trachelectomy**

[Hüsnü Çelik](#), Gonca Çoban, Songül Alemdaroğlu, Pınar Aytaç Çağlar

Department of Gynecologic Oncology, Başkent University Faculty of Medicine, Adana, Turkey

Objective: We aim to define laparoscopic radical trachelectomy with pelvic lymphadenectomy.

Material and Methods: We operated 37 years old patient, stage Ib1 and who desire fertility.

Results: Laparoscopic radical trachelectomy and pelvic lymphadenectomy should be offered as an alternative treatment for women with early stage cervical cancer who want to preserve their fertility.

Keywords: Laparoscopic radical trachelectomy, pelvic lymphadenectomy, fertility

VP-33

Laparoscopic paraaortic lymphadenectomy

Hüsnü Çelik, Gonca Çoban, Songül Alemdaroğlu

Department of Gynecologic Oncology, Başkent University Faculty of Medicine, Adana, Turkey

Objective: We aim to describe laparoscopic paraaortic lymphadenectomy.

Material and Methods: We performed to laparoscopic paraaortic lymphadenectomy level of renal vein.

Results: Laparoscopic paraaortic lymphadenectomy is feasible and safety method for gynecologic oncology patients.

Keywords: Laparoscopic, paraaortic, lymphadenectomy

VP-34

Laparoscopic hysterectomy without ultra energy modality

Gonca Çoban, Songül Alemdaroğlu, Gülsen Durdağ, Hüsnü Çelik

Department of Gynecologic Oncology, Başkent University Faculty of Medicine, Adana, Turkey

Objective: We aim to describe laparoscopic hysterectomy without ultra energy modality.

Material and Methods: We performed laparoscopic hysterectomy with routine bipolar energy with the same practicality by the same steps.

Results: We couldn't find any difficulty from the new generation energy modalities.

Keywords: Laparoscopic hysterectomy, energy modality, bipolar

VP-35

Accurate identification and removal of invisible symptomatic deep intramural myomas by endoscopic ultrasound guidance

Ayşen Boza¹, Selim Mısırlıoğlu², Tonguç Arslan¹, Banış Ata³, Çağatay Taşkıran³, Bülent Urman³

¹*Department of Obstetrics and Gynecology, Vehbi Koç Foundation American Hospital, İstanbul, Turkey*

²*Department of Obstetrics and Gynecology, Vehbi Koç Foundation Koç University Faculty of Medicine Hospital, İstanbul, Turkey*

³*Department of Gynecologic Oncology, Vehbi Koç Foundation Koç University Faculty of Medicine and American Hospital, İstanbul, Turkey*

Objective: To describe the application of endoscopic ultrasound for identifying and accurate localization of symptomatic deep intramural myomas that are not visible to the naked eye or palpable by a laparoscopic probe.

Material and Methods: Description of the technique in an educational video. University affiliated private hospital.

Results: Intraoperative endoscopic ultrasound (IEU) can be utilized to localize deep intramural myomas that do not protrude from the serosa and thus aid in making an accurate incision that will facilitate their removal. IEU transducer has an adjustable head, which is able to move 90-degree in four directions. The technique for searching myomas is sliding the head systematically across the anterior, fundal and posterior walls of the uterus, both in top - down and side-to-side directions. The endometrial echo is used as an anatomical landmark to provide the optimal orientation of scanning array. In some cases myomas may be located at equal distance from the anterior, posterior and fundal surfaces (Video). At this time, if the surgeon cannot determine the closest serosal surface to the myoma, correct orientation can be achieved with the help of a blunt laparoscopic instrument. The instrument pushes the uterine serosa next to the transducer's head. This creates an indentation on the myometrium just above the myoma providing the evaluation of the distance between the myoma and the serosal surface (Video). The technique should be repeated for all surfaces to choose the appropriate one in the closest proximity with the myoma. The approval of the local institutional review board was obtained for this study.

Conclusion: The use of the IEU with the above mentioned technique aids in accurate identification and removal of deep intramural myomas.

Keywords: Deep intramural myomas, intraoperative ultrasonography, endoscopy

VP-36

The utility of percutaneous endoscopic instrument in total laparoscopic hysterectomy

Selim Mısırlıoğlu¹, Sertan Aksu², Ayşen Boza², Tonguç Arslan², Bülent Urman³, Çağatay Taşkıran³

¹Department of Obstetrics and Gynecology, Vehbi Koç Foundation Koç University Faculty of Medicine Hospital, İstanbul, Turkey

²Department of Obstetrics and Gynecology, Vehbi Koç Foundation American Hospital, İstanbul, Turkey

³Department of Gynecologic Oncology, Vehbi Koç Foundation Koç University Faculty of Medicine and American Hospital, İstanbul, Turkey

A 49 years old woman was admitted with irregular menstrual bleeding. Myometrial or adnexial lesions were not found on transvaginal ultrasonography. Endometrial biopsy was revealed out endometrial hyperplasia with complex atypia. Laparoscopic hysterectomy + bilateral adnexectomy was suggested. Procedure was performed under general anesthesia in dorsolithotomy position. After veress needle insertion, the abdominal cavity was insufflated with carbon dioxide and pneumoperitoneum was obtained. M-LPS was performed through one optical transumbilical 5-mm trocar, one 5-mm ancillary port on the right side, one 3-mm ancillary port on left and one 2-mm percutaneous endoscopic instrument. A 5-mm 0-degree endoscope, 3 mm laparoscopic instruments and integrated bipolar and ultrasonic technology (Thunderbeat, Olympus Medical Systems Corp, Tokyo, Japan) were used. Vaginal cuff was closed by using 2/0 V-loc suture. Intraoperative and postoperative complication was not seen. Final pathology reported no evidence of cancer.

Keywords: Percutaneous endoscopy, laparoscopy, hysterectomy

VP-37

Laparoscopic retroperitoneal paraaortic lymph node dissection

Ahmet Barış Güzel, Ümran Küçükgöz Güleç, Ghanim Khatib, Mehmet Ali Vardar

Department of Obstetrics and Gynecology, Division of Gynaecologic Oncology, Çukurova University Faculty of Medicine, Adana, Turkey

We will present as a video form.

Keywords: Laparoscopy, retroperitoneal, lymph node dissection

VP-38

A difficult laparoscopic hysterectomy in the case of densely attached uterus to the anterior abdominal wall

Başı Kaya

Department of Obstetrics and Gynecology, Near East University Hospital, Nicosia, Turkish Republic of North Cyprus

Objective: To present a laparoscopic hysterectomy in the case of uterus densely attached to the anterior abdominal wall.

Material and Methods: A 46-year-old woman suffering from severe menorrhagia who had 5.9 gr/dL Hb, is planned for total laparoscopic hysterectomy after 4 units of blood transfusion. She had a bowel surgery and a C-Section in her history. A uterine manipulator (VCare®, ConMed Endosurgery, Utica, NY) was fixed to the cervix in a lithotomy position under general anesthesia. Direct entry from the Palmer's point was preferred and 10 mm 0 degree rigid laparoscope placed 4 cm above the umbilicus via 12 mm trocar, followed by a 5 mm trocar placement in right lateral side (1 cm above the umbilical level) after providing pneumoperitoneum with CO₂. The uterus was 18w gestation week in size and densely attached to the anterior abdominal wall. Dens adhesions were lysed with bipolar coagulation and cut with laparoscopic scissors carefully which allowed mobilizing the uterus. Then the ligamentum ovarii proprium, round ligament, uterine arteries, broad, cardinal and uterosacral ligaments were dissected and cut with a 5 mm LigaSure™ (Covidien, Mansfield, MA) respectively. After removing uterus, vaginal cuff was closed with Vicryl by laparoscopic suturing technique.

Results: The left subcostal area is preferred initial access point in our case to avoid possible entry complications. Severe adhesions may cause; difficulty in finding free space for port placement, limit the traction and visualization, bleeding from the surface of the visceral organs or bowel and urinary tract injury. In our case, densely attached uterus mobilized with meticulous dissection and obeying the laparoscopic surgical rules strictly.

Conclusion: Choosing Palmer's point for access and the right trocar placements in big uterus, traction and counter-traction, working on the right anatomic planes and patience of the surgeon are the key elements for a successful procedure without conversion to open laparotomy.

Keywords: Laparoscopic hysterectomy, dens adhesion, previous surgery

VP-39

Robotic myomectomy, cystectomy and pregnancy: Case report

Hediye Dağdeviren, Murat Ekin

Department of Obstetrics and Gynecology, Bakırköy Dr. Sadi Konuk Training and Research Hospital, İstanbul, Turkey

Objective: Reproductive surgery preserves, enhances or restores fertility. The minimal access surgery offers many benefits in relation to open surgery.

Case: A 33-year-old female patient, with primary infertility of six years of evolution in who uterine myomatosis with six centimeter right entometrioma and four centimeter dermoid cyst was diagnosed and robotic surgery was indicated.

Conclusion: The advantages of robotic surgery are: lower blood loss, hospital stay and postoperative pain and faster reinstatement to normal activities, in addition to a promising reproductive outcome for the patient.

Keywords: Fertility, myomectomy, robotic surgery