

*2016 TAJEV / Video Presentation*

## [VP-001]

## Laparoscopic cerclage in the 12<sup>th</sup> week of gestation after radical trachelectomy and following IVF therapy

Gürkan Arkan, Önder Ünalın, Cengiz Sağırođlu, Ayşe Kafkaslı

*Yeni Yüzyıl University Gaziosmanpaşa Hospital, İstanbul, Turkey*

**Objective:** Trachelectomy is a surgical procedure for patients with cervical intraepithelial neoplasia and early-stage cervical carcinoma, who wish to conserve fertility. As the surgical procedure may change the shape of the cervix and cause cervical insufficiency, infertility or poor obstetric outcomes are more common. Although most patients conceive spontaneously followed by radical vaginal trachelectomy (RVT), some may require assisted reproductive technologies owing to cervical stenosis. Increased likelihood of preterm labor and delivery is another concern for subsequent pregnancies after RVT. Second trimester miscarriage and preterm labour could be caused by cervical shortening or absence of the defensive cervical mucous plug in 15% to 35% of patients and/or fetal death with pregnancies having undergone the RVT. However, the ideal obstetric standard of care for patients who have undergone RVT has not yet been established. Laparoscopic cerclage is usually performed to help prevent possible cervical incompetence right after radical trachelectomy or in the first trimester of gestation. The procedure may technically be difficult due to the increased size of the uterus and collateral veins around cervicoisthmic area during late first trimester.

**Material and Methods:** To present the technique of laparoscopy assisted cervical cerclage after radical trachelectomy in late first trimester.

**Design:** Video demonstration of the steps of the laparoscopic cerclage procedure, location of the cerclage during follow up.

**Intervention:** A 34-year-old woman was referred to the in vitro fertilisation (IVF) clinic following failure to conceive with male factor infertility. She had a history of two missed abortions, followed by a radical laparoscopic trachelectomy and bilateral laparoscopic pelvic node dissection as fertility sparing surgery for cancer of the cervix stage 1B. She remained under follow up for 4 years and was disease free at the time of IVF therapy. Following a successful ICSI and a single embryo transfer, she was offered a laparoscopic cerclage, which she approved at the end of 12th week of gestation.

The laparoscopic cerclage was performed by 5-mm mersilene tape and a blunt-tipped needle (RS21; Ethicon). The operation time was 45 minutes. There were no operative or immediate postoperative complications. The patient was discharged home on postoperative day 1. The remainder of the pregnancy was uneventful, and she delivered via scheduled cesarean section in 38th week of gestation. The vigorous newborn was 3050 g.

**Conclusion:** Laparoscopic cervical cerclage during pregnancy can be safe and effective treatment for patients after trachelectomy and eliminates the need for open laparotomy.

**Keywords:** Cervical cancer, laparoscopic radical trachelectomy, laparoscopic cerclage, IVF, invitro fertilisation

## [VP-002]

## Laparoscopic management of an ectopic pregnancy in a lower segment cesarean section scar

Gürkan Arkan, Cengiz Sağırođlu, Ayşe Kafkaslı

*Yeni Yüzyıl University Gaziosmanpaşa Hospital, İstanbul, Turkey*

**Introduction:** Pregnancy developing in a previous cesarean scar is the rarest ectopic pregnancy. An early diagnosis is crucial because of the risk of rupture that can result in severe hemorrhage. We report such a case diagnosed at 9 weeks of gestation by endovaginal ultrasound and treated through a laparoscopic approach.

**Case Presentation:** The patient, a 32-year-old gravida 2, para 1, at 9 weeks of gestation, presented to our institution complaining of slight active vaginal bleeding and lower abdominal pain. Her obstetric history revealed one delivery by low transvers cesarean section (for indication of previous uterine surgery for fibroid removal). The patient presented no sign of shock and gynecological examination revealed a normal sized uterus, a closed cervix with minor bleeding and minimal pelvic pain. Transvaginal ultrasound scan demonstrated a well encapsulated bulging mass and a gestational sac within the cesarean scar containing an 9 weeks embryo based on crown-rump length (CRL) with cardiac activity. A sagittal plane of the uterus through the gestational sac allowed a precise localization of this pregnancy, embedded at the site of previous cesarean scar and protruding toward and under the vesico-uterine space.

A diagnostic laparoscopy showed initially normal finding. However, the dissection of the vesicouterine fold revealed the uterine perforation into the vesico-uterine. Product of conception was removed by laparoscopy assisted curettage, followed by laparoscopic suturing of the defect. Total operative time was 30 minutes, blood loss was limited, and no transfusion was needed. The patient was discharged on the 2<sup>nd</sup> day following the intervention, and the follow-up was uneventful.

After three months of postoperative contraception, the patient became spontaneously pregnant and ongoing normal pregnancy was in 26th week at the time of the publication.

**Discussion:** Laparoscopic surgical management of a viable ectopic pregnancy is technically simple, and is followed by good recovery.

**Keywords:** Laparoscopy, ectopic pregnancy, cesarean section scar

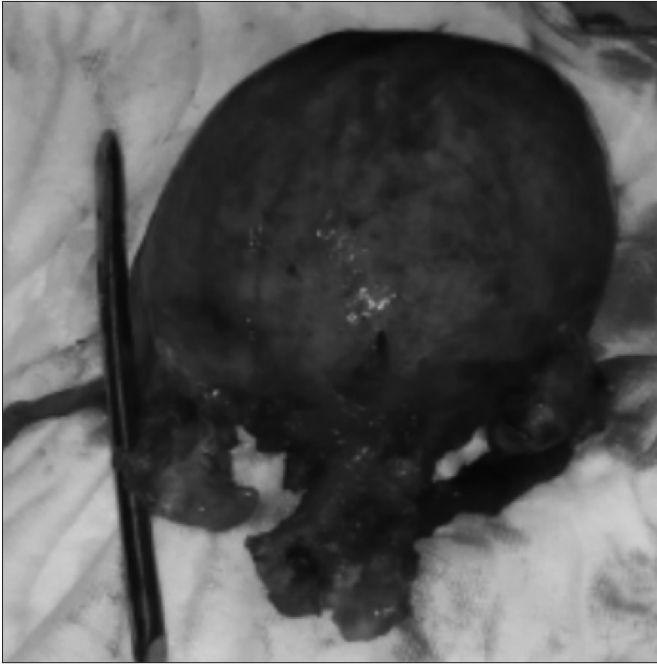
## [VP-003]

## Large uterus; single port hysterectomy

Suat Karataş, Hakan Erenel, Ayşe Ender Yumru, Meltem Tekeliođlu

*Department of Gynecology and Obstetrics, Şişli Hamidiye Etfal Training and Research Hospital, İstanbul, Turkey*

**Introduction:** Most of gynecologic procedures such as hysterectomy, salpingectomy, cystectomy and myomectomy can be done with sin-



**Figure 2. Large uterus**

gle port laparoscopic surgery instead of conventional laparoscopy. In recent years, single incision laparoscopic surgery (SILS) has become more popular and invasiveness of laparoscopy has decreased.

**Case Presentation:** A 47-year-old woman Gravida 2, Parity 2 patient was admitted with menorrhagia. Transvaginal ultrasound revealed a large, adenomyotic uterus with a 7x7 cm adenomyoma on the fundus. Decision of hysterectomy was made. Body mass index of patient was 40.7. Total hysterectomy and bilateral salpingoophorectomy was performed with multichannel access device (OCTO™ Port; DalimSurgnet, Seoul, South Korea). Uterus was removed through vagina and 5 mm accessory trocar was inserted on the left side for intracorporeal suturing and drain placement. Length of operation was 150 minutes. Surgery was carried out uneventfully; however, a consultation with general surgery was made due to feculent drainage on postoperative day 1. Laparotomy was made by general surgeon due to suspicion of intestinal injury and a full thickness defect of 0.5 cm in maximum diameter was found on jejunum. Probably, insertion and removal of instruments caused an injury. Injury was repaired primarily and patient was discharged on postoperative day 8.

**Discussion:** After selection of suitable patients, transumbilical single port laparoscopic hysterectomy is a safe and feasible operation. Silicon access orifices of Octo-port allows use of flat instruments and reduce instrument sword-fighting. Nevertheless, caution should be taken during insertion and removal of instruments through multichannel access device to prevent bowel injury.

**Keywords:** Single port, laparoscopic hysterectomy, large uterus

[VP-004]

## Laparoscopic management of cesarean scar pregnancy

Sezen Bozkurt Köseoğlu, Burak Sezgin, Aysun Camuzcuoğlu, Hakan Camuzcuoğlu

Department of Gynecology and Obstetrics, Muğla Sıtkı Koçman University Training and Research Hospital, Muğla, Turkey

Ectopic pregnancy in a previous cesarean scar occurs in about 1 in 2000 pregnancies and accounts for 6 percent of ectopic pregnancies among women with a prior cesarean delivery. The pregnancy is located in the scar and is surrounded by myometrium and connective tissue. The clinical presentation ranges from vaginal bleeding with or without pain to uterine rupture and hypovolemic shock. The diagnosis is made by sonographically visualizing an enlarged hysterotomy scar with an embedded mass, which may bulge beyond the anterior contour of the uterus.

The optimal treatment for a cesarean scar pregnancy is unclear and therapy should be tailored to the patients' clinical presentation. A patient who shows signs of hemorrhage or hemodynamic instability will require surgical intervention. This may include laparoscopy or laparotomy, or possible hysterectomy. In the stable patient, therapy may involve dilation and curettage or methotrexate therapy.

We report the case of 30 year old multiparous women at 6 weeks of gestation who presented with a pregnancy developing in the scar of a previous cesarean section. An early diagnosis was made by transvaginal ultrasound.

In this video, our aim is to present a case of laparoscopic removal of cesarean scar pregnancy.

**Keywords:** Cesarean scar pregnancy, laparoscopy

[VP-005]

## Laparoscopic surgery of a case with deep pelvic endometriosis

Burak Sezgin, Sezen Bozkurt Köseoğlu, Aysun Camuzcuoğlu, Hakan Camuzcuoğlu

Department of Obstetrics and Gynecology, Muğla Sıtkı Koçman University Training and Research Hospital, Muğla, Turkey

Adequate treatment of severe deep pelvic endometriosis requires complete excision of all implants. The purpose of this video presentation is to describe our experience with planned complete laparoscopic management of deep pelvic endometriosis. Our patient was 46 years old and had two caesarian section before. She also had a laparoscopic surgery for endometrioma 3 years ago. She had clinically chronic pelvic pain, dysmenorrhea and dyspareunia. In preoperative ultrasonography, there were bilateral ovarian cystic masses and CA 125 level was 100. In this case we performed laparoscopic hysterectomy and bilateral salpingoophorectomy, bilateral ureterolysis, excision of deep endometriotic nodule from rectovaginal septum and excision of endometriotic focus from rectum.

**Keywords:** Endometriosis, laparoscopy

[VP-006]

## Coexistence of lipoleiomyoma of the uterus and primary ovarian leiomyoma: two rare entities in same individual

Mustafa Şengül<sup>1</sup>, Serpil Aydoğmuş<sup>2</sup>, Uğur Turhan<sup>1</sup>, Elif Tekeli Yazıcı<sup>1</sup>, Öznur Bilge<sup>1</sup>, Gazanfer Mammadov<sup>2</sup>, Sefa Keleşçi<sup>2</sup>

<sup>1</sup>Clinic of Obstetrics and Gynecology, İzmir Atatürk Education and Research Hospital, İzmir, Turkey

<sup>2</sup>Department of Obstetrics and Gynecology, İzmir Katip Çelebi University School of Medicine, İzmir, Turkey

**Background:** Uterine lipoleiomyoma is a rare benign tumor that is composed of various mixtures of smooth muscle and mature fat tissue. The incidence of uterine lipoleiomyomas varies from 0.03% to 0.2%. They are typically found in postmenopausal women ranging from 50 to 70 years of age and they are associated with ordinary leiomyomas.

Primary ovarian leiomyomas are extremely rare, accounting for 0.5–1% of all benign ovarian tumors. The majority of such tumors occur in the reproductive period. Most of them are unilateral and no bilateral cases have been described in patients over the age 35. We present two cases of an ovarian leiomyoma coexisting with uterine lipoleiomyoma.

**Case 1:** A 59-year-old, gravida 4, para 3, postmenopausal woman exhibited pelvic discomfort. She experienced menopause at the age of 53 and a pelvic examination revealed a solid, tender mass on the left side that could not be clearly separated from the uterus. It was difficult to differentiate whether it is originated from the uterus or the ovary. A pelvic ultrasound revealed a normal-sized uterus and a 10×8×8 cm heterogeneous mass without vascularity. Her CA 125, CA 19-9 values were within normal limits. At laparotomy, her bilateral ovaries and tubes were normal in size but there was an 8 cm mass arising from the posterior fundocorporal region of the uterine wall. The patient had previously undergone a total abdominal hysterectomy and bilateral salpingo-oophorectomy. The postoperative period was uneventful.

**Case 2:** A 37-year-old, gravida 0, para 0, infertile woman exhibited primary infertility. Her gynecological history was normal. A pelvic examination revealed bilateral ovarian cystic masses and nodularity in Douglas. A pelvic ultrasound revealed a normal-sized uterus and bilateral anechoic cystic mass that seems like an endometrioma. CA 125 value was within normal limits. She underwent a laparoscopy with an initial diagnosis of primary infertility and bilateral endometrioma. At laparoscopy, her bilateral tubes were normal in size. Small superficial implants of endometriosis were present in Douglas. There was a 1 cm ovarian leiomyoma with 2 cm endometrioma localized, at the left ovary and 3 cm endometrioma localized at the right ovary, 0.5 cm subserosal fibroids at posterior fundocorporal region of uterine wall. Patient had undergone firstly uterine and ovarian myomectomy and subsequently to endometriotic cyst excision. No complication occurred during the post-operative period and she was discharged from the hospital at 48 hours after operation.

**Conclusions:** Ovarian leiomyomas should be differentiated from ovarian thecomas, fibromas, and uterine leiomyomas becoming parasites on the ovary. The coexistence of an ovarian leiomyoma with a uterine leiomyoma has been reported by several authors. However, to our knowledge, this is the first case of primary ovarian leiomyoma coexisting with a uterine lipoleiomyoma, two rare entities, in the same individual. This case may help and add information to clarify the pathogenesis of these lesions.

**Keywords:** Laparoscopy, ovarian leiomyoma, uterine lipoleiomyoma

[VP-007]

## Hybrid natural orificial transluminal endoscopic surgery (Hybrid-NOTES) for an ovarian mass

Cihan Kaya, Sema Çaypınar

Department of Obstetrics and Gynecology, Bakırköy Dr. Sadi Konuk Training and Research Hospital, İstanbul, Turkey

In this case we presented a forty three years old premenopausal patient, with a eight cm hypoechoic cyst in the right ovary.

Vaginal access

The patient was laid dorsal litotomy position under general anesthesia. The posterior lip of the cervix was grasped and elevated by tenaculum. A posterior culdotomy was performed five cm under lower part of the cervix by using monopolar cautery. The abdominal cavity was explored by finger from the opened window to exclude any pelvic adhesions. A Single Incision Laparoscopic Surgery trocar was inserted into the pelvic cavity. CO<sub>2</sub> gas was insufflated via this trocar to achieve pneumoperitoneum. A 10-mm rigid zero-degree telescope was then inserted for optic imaging. In exploration of the cavity there was a eight cm ovarian mass originating from the right ovary. A right salphigooophorectomy then performed via articulating tissue sealer.

Umbilical access

A ten millimeter umbilical trocar then inserted to assist visualising the pelvic mass while removing it from the vagina. A 10 mm endobag was inserted vaginally and the mass containing fatty fluid was taken out in the bag after fluid aspiration. The colpotomy defect was sutured with 2-0 vicryl. The time of the operation was around 1 hour and the operation ended with no complication. The patient was discharged postoperative 1st day with no complaints. The final pathology was reported as dermoid cyst of the ovary.

**Keywords:** Laparoscopy, natural orifice transluminal endoscopic surgery, ovary

[VP-008]

## Laparoscopic myomectomy with temporary clipping of uterine and infundibulopelvic vessels

Hakan Güraslan, Cihan Kaya, Çağlar Helvacıoğlu

Department of Obstetrics and Gynecology, Bakırköy Dr. Sadi Konuk Training and Research Hospital, İstanbul, Turkey

This video presents a laparoscopic myomectomy in a 37 year-old patient with chronic pelvic pain and excessive menstrual blood loss.

Myomectomy starts after intraoperative temporary clipping of the uterine artery and infundibulopelvic vessels. This simple method allows for the prevention of massive bleeding during the excision of the myomas.

The technique consist in opening the parietal peritoneum of the pelvic side wall in order to detect uterine artery between the ureter and the umbilical artery and to clip it temporarily.

We cut the peritoneum at the junction between the ureter and umbilical artery. and dissect surrounding tissue of the ureter, umbilical and uterine artery with small and gentle movements. We placed the clip on uterine artery just before origin of uterine and umbilical artery as shown in the case. We performed the same procedures for the left side.

Moyomectomy was performed by sharp and blunt dissections. The uterine defect was closed by two layer suturing.

We remove of the clips the left then right side after the procedure.

**Keywords:** Laparoscopy, uterine artery, uterine myomectomy

#### [VP-009]

## Laparoscopic detortion of the ovary and bilateral ligamentopexis

Hakan Güraslan, [Cihan Kaya](#), Çağlar Helvacıoğlu

*Department of Obstetrics and Gynecology, Bakırköy Dr. Sadi Konuk Training and Research Hospital, İstanbul, Turkey*

This video shows a case of 15 years old girl presenting with acute abdominal pain and tenderness. The ultrasound imaging revealed that a ten cm solid adnexal mass with no blood flow in the right pelvic side. Laparoscopy was planned due to acute abdominal pain. In the exploration of the abdominal cavity there was tortioned 10 cm ovary with its pedicle on the right side. We decided to perform detortion and waiting for the colour change of the ovary. The ovary was tortioned for fifteen times around its pedicle. The ligamentum ovarii proprium was also ruptured from the middle part. An incision was performed from the anti mesenteric part of the ovary to obtain a biopsy and to explore the presence of any ovarian cysts. A small biopsy was taken and the right ligamentum ovarii proprium was approximated by suturing. A ligamentopexis was performed for the left side to prevent any future ovarian tortion.

**Keywords:** Laparoscopy, ligaments, ovary

#### [VP-010]

## Laparoscopically managed cesarean scar pregnancy; a case report

Mete Güngör, [Özgüç Takmaz](#), Savaş Gündoğan, İbrahim Bildirici

*Department of Obstetrics and Gynecology, Acibadem University Maslak Hospital, İstanbul, Turkey*

**Introduction:** Cesarean scar pregnancy (CSP) is an ectopic pregnancy which is defined a gestational sac located in prior cesarean low segment uterine incision site within diminished myometrium tissue. Diagnosis of CSP is usually made with ultrasonography and/or MRI identifying empty uterus and cervical canal, a gestational sac under bladder wall with thin or diminished myometrium. Due to increasing numbers of cesarean deliveries, frequency of SCP cases are on the rise. It is estimated that 1 in 531 women with a prior cesarean will have CSP in later pregnancies. And 4.2% of ectopic pregnancies are CSP. Increased risk of complications like uterin rupture, life-threatening hemorrhage and hypovolemic shock make CSP treatments im-

portant. Although recently more studies have being published, the most safe and efficient clinical approach to CSP is yet to be determined. There is no consensus on treatment of CSP. There are various treatment options defined for CSP. Systemic/local methotrexate infusion with or without needle aspiration, uterin curettage, hysteroscopy, resection of CSP through transvaginal approach, uterine artery embolization, high-intensity focused ultrasound, double balloon placement into the uterus and laparoscopy. Here, we report a case of laparoscopically managed a CSP case.

**Case Presentation:** A 32 year old gravida 4, para 1 woman was admitted to our clinic complaining delay of menstruation. She had history of one previous cesarean section 5 years ago and 2 missed abortion treated with dilatation curettage 2 and 1 year ago, respectively. In ultrasonographic examination, it was revealed a gestational sac with fetal pole in the isthmic zone and diminished myometrial tissue blew the bladder in the cesarean section incision site with a normal posterior uterine wall thickness. Crown to rump length of fetal pole was 16mm and fetal cardiac activity was positive. The patient underwent laparoscopy. Bladder is dissected from isthmic area, than cesarean section scar resected within gestational sac. Than defect was repaired with barbed suture. There was no complication and estimated blood loss was 150cc. Patient was discharged the day after surgery.

**Discussion:** CSP is a rare but life threatening condition. Prevalence of CSP is rising due to increasing cesarean section deliveries worldwide. There is no consensus for treatment of CSP. Although laparoscopic management of CSP seems safe and efficient, there is need of further well designed studies to assess how to treat.

**Keywords:** Cesarean scar pregnancy, ectopic pregnancy, laparoscopy

#### [VP-011]

## A novel vaginal repair technique of apical prolapse and enterocele ensuring ureteral safety via vaginal ureteral dissection eliminating the need for intraoperative cystoscopy

[Mehmet Sakıncı](#)<sup>1</sup>, Oğuzhan Kuru<sup>2</sup>

<sup>1</sup>*Department of Obstetrics and Gynecology, Akdeniz University School of Medicine, Antalya, Turkey*

<sup>2</sup>*Department of Obstetrics and Gynecology, Hacettepe University School of Medicine, Ankara, Turkey*

**Objective:** To present a novel technique for repair of apical prolapsus and enterocele which ensures ureteral safety eliminating the need for intraoperative cystoscopy.

**Methods:** All 5 patients underwent vaginal hysterectomy (VH) and ligature assisted vaginal bilateral salpingoophorectomy (BSO) + modified high uterosacral ligament suspension (USLS) with vaginal ureter dissection. In the technique; following BSO; medial peritoneal leaflet under the infundibulopelvic ligament (IPL) is incised and ureters are dissected free vaginally of the surrounding connective tissue bilaterally up to the level of crossing point with the uterine arteries. Both ureters are visualized sufficiently and mobilized to more anterior and lateral position. Thereupon secure and strong suture bites were taken bilaterally from the uterosacral ligaments.

**Technical Description:** After completion of BSO, peritoneum under the infundibulopelvic ligament was incised and peritoneal leaves were separated. Medial peritoneal leaflet was reflected medially and dissected bluntly from the lateral attachments until the ureter is visualized. Peritoneal incision was carried downwards. The ureteric course was followed with blunt dissection upto the level of crossing point with the uterine artery. At this step, ischial spine was palpated, by blunt dissection posteriorly-medially and with medial retraction of rectum, USLs were dissected and visualized retroperitoneally. Both ureters were freed from the surrounding connective tissue by sharp and blunt dissection, displaced to more anterior (upward) and lateral position. Then one pair of proximal high uterosacral fixation sutures (number 1 polyglactin) approximately 0.5 cm proximal to the ischial spine bilaterally and two external McCall culdoplasty sutures, incorporating the peritoneum over the rectum, 0.5 cm caudally from the first suture and 0.5 cm apart from each other were placed. During suturing the proximal USL was directly visualized, mobilized ureters were retracted from the field and, large, durable and secure suture bites were passed from the ligament. All these sutures were pulled to the contralateral side strongly to control the strength and durability of the ligament and if any ureteral kinking would occur with this medial displacement of adjacent tissue. No ureteral kinking was observed with these maneuvers. The pair of high USL fixation sutures were passed through the full-thickness ipsilateral posterolateral vaginal wall corresponding to the place where original USL inserts. Two external McCall sutures were placed through the midline of the reconstructed posterior vaginal wall 1 cm apart. Midline McCall sutures were tied down, elevating the vault into the hollow of the sacrum and obliterating the cul-de-sac, and high USL fixation sutures were tied down bilaterally.

**Results:** Duration of the operations and bilateral ureteral dissections were 2.5, 2.5, 3, 2, 3 hours and 10, 35, 17, 13, 16 minutes, respectively. All patients had normal preoperative and postoperative renal pelvic-lyceal system ultrasonographic examination. Early postoperative follow-up of the patients was uneventful except urinary retention in the first two cases. With a median time of 3 months (2-5 months, range), postoperative follow-up of the patients was uneventful. No urinary, gastrointestinal or neurologic complications have occurred.

**Conclusion:** The new vaginal repair technique of apical prolapse potentially eliminates all kinds of uterine injuries and the need for intraoperative cystoscopy decreasing the additional costs, operative duration and morbidity related with ureteral complications, cystoscopy and anesthesia.

**Keywords:** Vaginal ureteral dissection, modified vaginal repair technique of apical prolapse and enterocele

#### [VP-012]

## Hysteroscopically-assisted laparoscopic excision and repair of cesarean scar defect

Taner A. Usta, Elif Cansu Gündoğdu, Erdal Kaya

*Department of Obstetrics and Gynecology, Bağcılar Research and Training Hospital, İstanbul, Turkey*

The rate of cesarean section has increased rapidly over the last several decades. Although the incidence of the disease varies considerably, cesarean scar defects are being more commonly reported. It is

associated with post menstrual uterine bleeding, secondary infertility and pelvic pain.

A 38-year-old woman, gravida 5, para 5 presented with post menstrual bleeding. Transvaginal ultrasonography revealed niches in the uterine scar. Considering the close proximity to the bladder and uterine scar defect with residual myometrium thickness of 1.8 mm, hysteroscopically assisted laparoscopic excision and repair of the cesarean scar defect was performed.

Although recently there has been growing interest in hysteroscopic resection of the isthmocele, treatment options must be individualized and carefully planned to minimize both complications and the requirement for additional treatments.

**Keywords:** Isthmocele, laparoscopic repair, abnormal uterine bleeding, hysteroscopy

#### [VP-013]

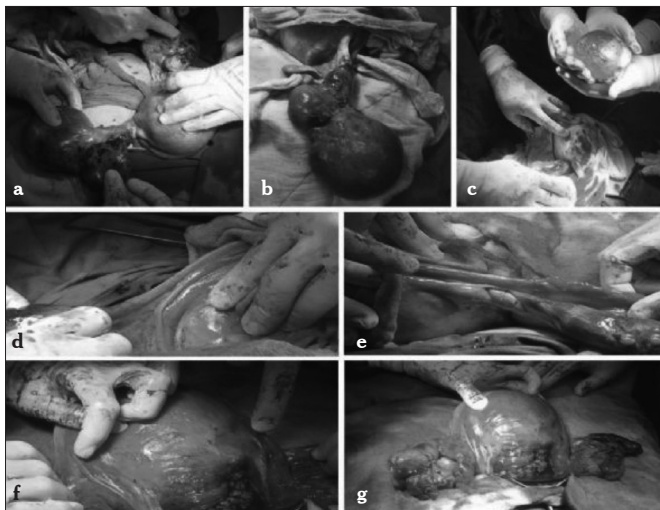
## Third trimester bilateral ovarian torsion in the presence of bilateral ovarian cysts: a case report

Ahmet Karataş, Tülay Özlü, Çağlar Çetin, Ömür Albayrak, Mehmet Ata Topçuoğlu

*Department of Obstetrics and Gynecology, Abant İzzet Baysal University School of Medicine, Bolu, Turkey*

**Introduction:** Ovarian torsion is one of the most frequent gynecologic emergencies. Presence of an ovarian mass, especially greater than 5 cm is the most important risk factor. Pregnancy, ovulation induction and prior ovarian torsion are other factors associated with increased risk. Here, we present conservative management with detorsion, cystectomy and oophorectomy in a third trimester pregnancy with bilateral ovarian cysts and bilateral ovarian torsion.

**Case Presentation:** A 27-year-old primigravida woman at her 34/7 weeks of gestation obtained after a gonadotropin intrauterine insemination cycle was admitted because of left sided abdominal pain and nausea present for the last two weeks. She had an ovarian hyperstimulation syndrome history at the beginning of pregnancy and had bilateral ovarian cysts that persisted during pregnancy. One week before her admission to our clinic her left ovarian cyst had been aspirated at another clinic. Upon admission, both ovaries contained multiple cysts the biggest of which was 8×9 cm at the left side and 6×7 cm at the right side. Radiological ultrasound reported that Doppler investigation of left ovary was suspicious for torsion. Her vital signs were normal. Her hemoglobine was 10.3 g/dL, leucocyte count was 14.400/mm<sup>3</sup>. Taking her two weeks of pain history into account, we thought it may not be torsion and initiated follow up with analgesics and IV hydration. Her symptoms regressed, she was discharged at 5th day of hospitalization, but admitted same afternoon with acute onset left lower abdominal pain, nausea and vomiting. Radiology reported that blood flow at right ovary was suspicious for torsion while left one was normal this time. Her symptoms were relapsing and remitting, therefore we continued follow up. Two days later her symptoms became more severe, her nausea and vomiting increased, pain increased in intensity, was radiating to her leg and was unresponsive to analgesics. Therefore, cesarean section was performed at 35/7 weeks of gestation. Exploration of adnexial structures revealed torsion of right ovary which had a purple to black appearance, was cystic and had a size



**Figure 1. a-g. (a, b) Right ovarian cyst about 15×10cm in size with a purple to black appearance and left ovarian cyst about 10×12 cm in size with patchy echymotic, necrotic areas (c), right ovarian cystectomy material (d, e), right oophoropexy suture front and rear views (f, g), bilateral oophoropexy by fixing the uteroovarian ligament, mesosalpinx and round ligament to each other**

of about 15×10 cm (Figure 1a, b). Left ovary was in normal position, contained several cysts, was about 10×12 cm but there were patchy echymotic, necrotic areas on it probably associated with previous torsion and detorsion (Figure 1a). Immediate right ovarian detorsion was performed before closing uterine incision. Within 5 minutes, color of the ovary got better. Bilateral ovarian cystectomy was performed (10×8 cm from right ovary (Figure 1c) (was reported to be a serous cystadenoma), 6×6 cm left ovary) and ovarian defects were sutured. Then, to prevent recurrent torsion, bilateral oophoropexy was performed by fixing the uteroovarian ligament, mesosalpinx and round ligament to each other (Figure 1d-g). The postoperative course of the patient was uneventful and she was discharged 3 days after surgery. She also had a normal course one month after surgery.

**Discussion:** Ovarian torsion should be considered among differential diagnoses in pregnant women with acute onset abdominal pain. Pregnancy and presence of ovarian masses increases risk of ovarian torsion. Ovarian conservation may be possible even in necrotic appearing ovaries. Oophoropexy may be considered after detorsion to prevent recurrent torsion.

**Keywords:** Ovarian torsion, bilateral ovarian torsion, oophoropexy

[VP-014]

## Robotic resection of vascular mesometrium in an early-stage cervical cancer patient

Tayfun Toptaş<sup>1</sup>, Aysel Uysal<sup>2</sup>, Işın Üreyen<sup>1</sup>, Onur Erol<sup>2</sup>, Tayup Şimşek<sup>3</sup>

<sup>1</sup>Department of Gynecologic Oncological Surgery, Antalya Research and Training Hospital, Antalya, Turkey

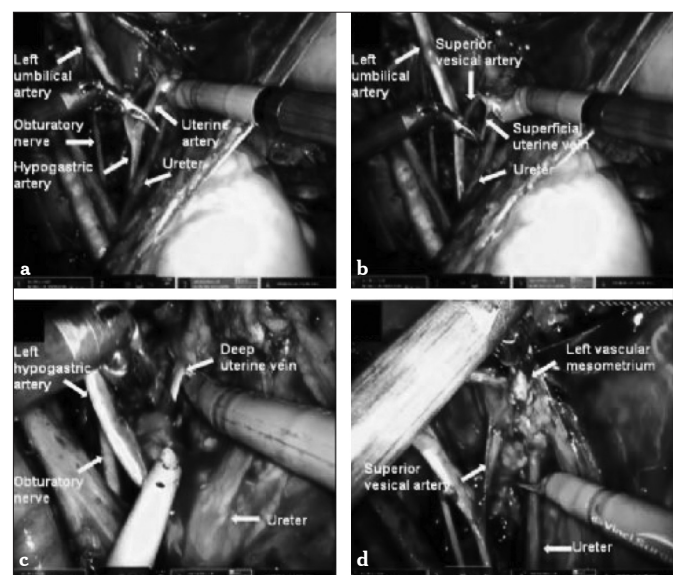
<sup>2</sup>Department of Obstetrics and Gynecology, Antalya Research and Training Hospital, Antalya, Turkey

<sup>3</sup>Department of Gynecologic Oncological Surgery, Akdeniz University School of Medicine, Antalya, Turkey

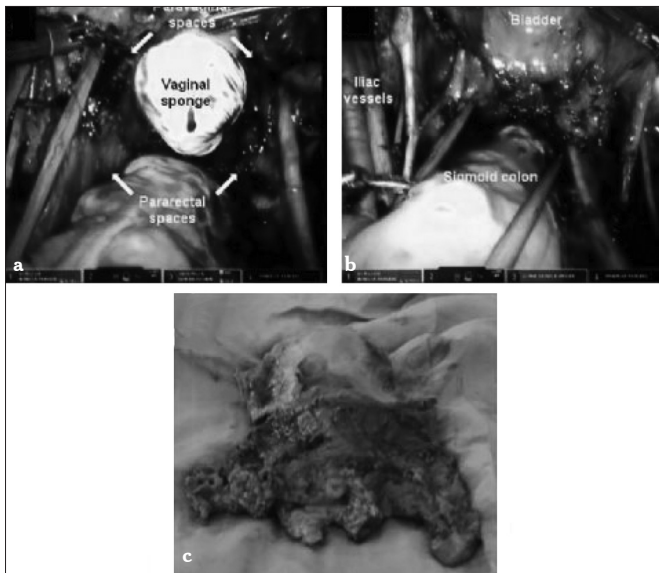
**Objective:** A radical hysterectomy is the recommended treatment option in patients with early-stage cervical cancer (CC). Although various classifications were developed in order to define the resection margins of this operation, no clear standardization could be achieved both in the nomenclature and the extent of the surgery. Total mesometrial resection (TMMR) is a recently described procedure which aims to remove the compartment formed by Müllerian duct in which female reproductive organs develop. TMMR differs from the other radical hysterectomy techniques in that its surgical philosophy, terminology and partly resection borders are different. In this video presentation we aimed to show the surgical steps of the vascular mesometrial resection part of the TMMR operation that we performed using daVinci®XI robotic system in a stage IA2 CC patient.

**Material and Methods: Patient characteristics;** A 34-year-old, gravidity and parity one, woman admitted to our clinic with a co-testing result of HSIL with HPV type 16 positivity. She was 48kg in weight with a body mass index of 21 kg/m<sup>2</sup>. Colposcopically directed biopsy was consistent with CIN3. She underwent cold knife conization. Histopathological examination revealed a squamous cell carcinoma with a stromal invasion 4 mm in depth and 6 mm in horizontal spread.

**Surgical technique:** Patient-side cart of the robotic system was approached to the patient from the right side and docked. The monopolar scissors was inserted through the right robotic trocar; a Maryland bipolar forceps, through the left trocar; and a ProGrasp™ forceps, through the fourth trocar. The operation was carried out in three stages: First, bilateral ovarian transposition was applied; pelvic lymphadenectomy was performed in the second stage; and Müllerian compartment resection was performed in the third stage. The resection of the Müllerian compartment was completed in two steps being the resection of the vascular mesometrium and ligamentous mesometrium. In the resection of vascular mesometrium, first the lateral connections (lateral parametrium) including uterine artery, su-



**Figure 1. a-d. Resection of the lateral part of the vascular mesometrium (left side) (a), resection of the uterine artery (b), resection of the superficial uterine vein (c), resection of the deep uterine vein (d), the view of the resected mesometrial bundle**



**Figure 2. a-c. (a, b) Final view of the pelvis after total mesometrial resection (c), surgical specimen**

perforial uterine vein, parametrial LNs and the deep uterine vein were cauterized and cut at their origin from the hypogastric vessels, in the vertical plane, respectively. The lateral mesometrial bundle that was resected was elevated towards the ureter using ProGrasp™ forceps (Figure 1). Subsequently, the anterior connections (ventral parametrium) of the vascular mesometrium were incised in such a way to ensure the lateral borders were superior vesical artery and the ureterovesical junction. Thus, the ureteric tunnel was opened, the ureter was separated from the Müllerian compartment, and the resection of the vascular mesometrium was completed. Final view of the pelvis after total mesometrial resection was shown in (Figure 2).

**Results:** In total, 200 mL of bleeding occurred. On the second day, a regular diet was started and the urinary catheter was removed. The amount of residual urine volume that was measured by re-catheterization on the third day was 50 mL. She had an uneventful postoperative course and was discharged home on postoperative day five.

**Conclusion:** Robotic TMMR is a minimally invasive treatment option for the patients with early-stage CC that can be easily adopted into clinical practice.

**Keywords:** Robotik surgery, cervical cancer, mesometrial resection