

# Angiomyxoma: a rare tumor of the umbilical cord

## *Anjiyomiksoma: Umbilikal kordun nadir bir tümörü*

Hale Göksever<sup>1</sup>, Murat Celiloğlu<sup>1</sup>, Ali Küpelioglu<sup>2</sup>

<sup>1</sup>Dokuz Eylül University Faculty of Medicine, Gynecology and Obstetrics, İzmir, Turkey

<sup>2</sup>Dokuz Eylül University Faculty of Medicine, Pathology (retired prof), İzmir, Turkey

### Abstract

Tumors of the umbilical cord are rare anomalies and should be considered when using prenatal ultrasound for detection of cystic lesions. Differential diagnosis of umbilical cord tumors should comprise umbilical cord teratoma, hemangioma and angiomyxoma. It can also be an umbilical cord polyp, umbilical cord cyst, hernia into the cord and omphalocele, which are mostly isolated findings, except omphalocele. Angiomyxoma is a rare tumor of the umbilical cord and is associated with increased perinatal morbidity and mortality. We present a 22-year-old woman with a large umbilical cord tumor who underwent a caesarean section. As in our case, neither chromosomal aberrations nor elevated alphafetoprotein were found after amniocentesis or chordocentesis. Macroscopical and microscopical pathological examinations of the mass after delivery revealed an angiomyxoma with cystic degenerations in myxoid stroma.

(J Turkish-German Gynecol Assoc 2010; 11: 58-60)

**Key words:** Umbilical cord, angiomyxoma

**Received:** 13 May, 2009

**Accepted:** 3 August, 2009

### Özet

Umbilikal kord tümörleri nadir anomalilerdir ve kistik lezyonların araştırılması için prenatal ultrason kullanıldığında düşünülmelidir. Umbilikal kord tümörlerinin ayırıcı tanısı umbilikal kord teratomları, hemanjiyoma ve anjiyomiksomalara kapsamalıdır. Ayrıca omfalosel dışında çoğunlukla izole bulgular olarak izlenen umbilikal kord polipi, umbilikal kord kisti, kord içine herniasyon ve omfalosel olabilir. Anjiyomiksoma, umbilikal kordun nadir bir tümürüdür ve artmış perinatal morbidite ve mortaliteyle ilişkili bulunmuştur. 22 yaşında sezaryan ile doğum yapan geniş umbilikal kord tümörü olan olgu sunumu yapılmaktadır. Olgumuzda olduğu gibi, umbilikal kord tümörlerinde amniyosentez veya kordosentez ile kromozomal bozukluk veya yüksek alfa-fetoprotein değerleri bulunmayabilir. Doğumdan sonra kitlenin mikroskopik ve makroskopik patolojik incelemesinde miksoid stromada kistik dejenerasyon ile birlikte anjiyomiksoma izlenmiştir.

(J Turkish-German Gynecol Assoc 2010; 11: 58-60)

**Anahtar kelimeler:** Umbilikal kord, anjiyomiksoma

**Geliş Tarihi:** 13 Mayıs 2009

**Kabul Tarihi:** 03 Ağustos 2009

### Introduction

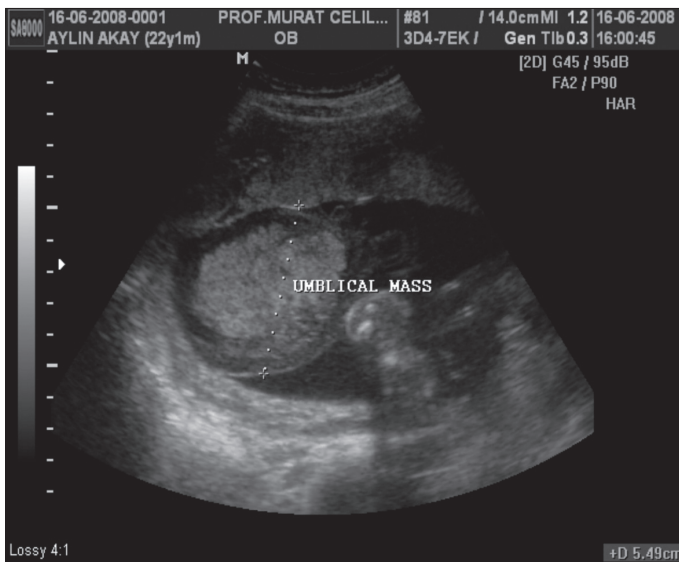A tumor of the umbilical cord is a rare event that can be diagnosed prenatally by ultrasound examination. Only two true tumors occur in the umbilical cord: angiomas and, more rarely, teratomas. Angiomyxoma is associated with increased perinatal morbidity and mortality. However, the management of these pregnancies in the third trimester is not clearly defined. Close follow-up is needed because some of the fetuses and newborns have fatal outcomes.

We present a 22-year-old woman with a large umbilical cord tumor who underwent a caesarean section. Serial ultrasound examinations showed an increase in the size of the mass without deterioration of the fetal condition. Macroscopical and microscopical pathological examinations of the mass after delivery revealed an angiomyxoma with cystic degenerations in myxoid stroma. Therefore, these rare umbilical cord tumors should be considered when using prenatal ultrasound for detection of cystic lesions of umbilical cord.

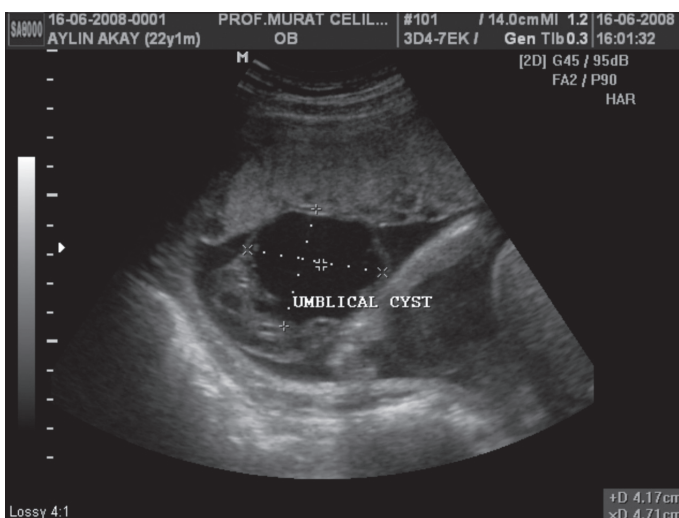
### Case report

A 22-year-old woman, gravida 1 para 0, was referred to our clinics for routine prenatal assessment at 24 weeks

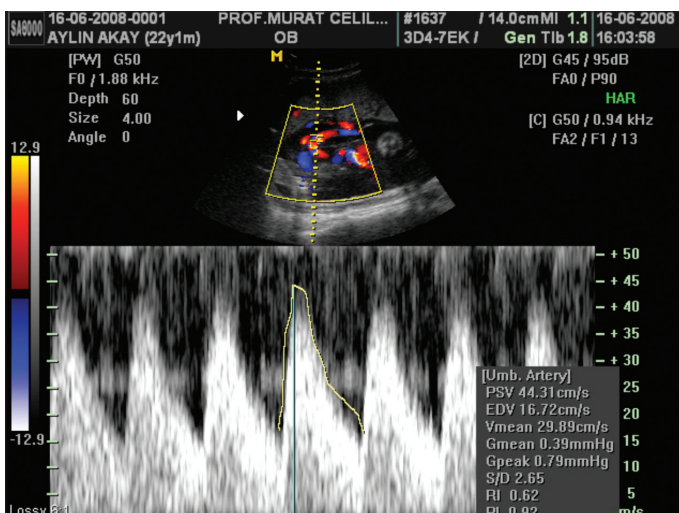
of gestation. Detailed ultrasound examination showed a single live anatomically normal fetus. The pregnancy was uncomplicated regarding maternal health problems, vaginal bleeding or exposure to teratogens except that she had epileptic seizures. Because of this, she was using Trileptal treatment per oral. She and her 23-year-old nonconsanguineous spouse had an unremarkable family history. The fetal movements were normal and assessment demonstrated growth parameters appropriate for the gestational age and amnion fluid index was normal. The placenta was located at the right on the fundus. Ultrasound examination demonstrated a mass arising from the umbilical cord (Figure 1). This abnormal structure was heterogenous and composed of solid and cystic areas (Figure 2). The diameter was about 5 cm. On high-resolution ultrasound and color Doppler examination, one venous and two arterial structures were observed and Doppler indexes of umbilical arteries were normal (Figure 3). The fetal abdomen wall was intact. Chordocentesis and fetal magnetic resonance imaging were advised. At 25 weeks of gestation, chordocentesis was performed. It revealed a normal 46, XX karyotype. Magnetic resonance imaging (MRI) demonstrated a non-homogenous lesion that was clearly demarcated and located on the fundus associated with the umbilical cord and measuring about 6x5 cm in diameter. It was thought to be



**Figure 1. Umbilical mass**



**Figure 2. Umbilical cyst**



**Figure 3. Doppler indexes of umbilical artery**

either an angiomyxoma or hemangioma which were tumors arising from the umbilical cord.

Sequential ultrasound examination from 25 weeks to the end of pregnancy demonstrated progressive expansion of the mass. The fetal growth pattern remained normal.

At 38 weeks of gestation, a girl was delivered by caesarean section weighing 3100 gram with a length of 49 cm. Neither dysmorphism nor external malformation was observed. In the formaldehyde solution, an umbilical cord tumor of 3.5 cm was attached to the abdominal wall in a normal position. Macroscopical and microscopical pathological examinations of the mass after delivery revealed an angiomyxoma with cystic degenerations in myxoid stroma (Figure 4, 5). On the umbilical cord wall, green gelatinous and white myxoid areas were seen. On microscopic examination, one venous and one arterial structure was observed instead of one venous and two arterial structure. Around these vessels, there was expanded and degenerated myxoid stroma. The macroscopical and microscopical placental examination revealed no abnormality. The placenta weighed 272 grams and measured 9.5x6x3.5 cm. There were no clinical findings other than the umbilical tumor. The infant was discharged from hospital in a stable condition. At present, after 5 months, the infant is in good health.

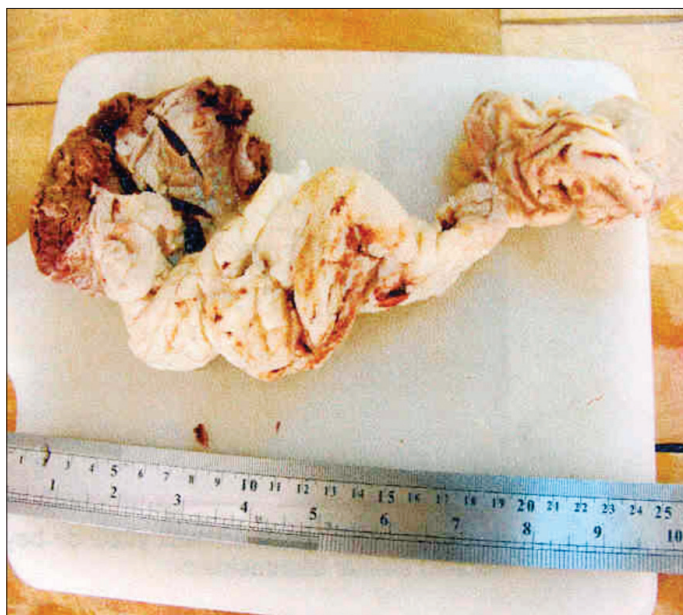
## Discussion

Tumors of the umbilical cord are rare anomalies and should be considered when using prenatal ultrasound for detection of cystic lesions. Nodular bulges of the umbilical cord are rare entities of polymorphous presentation that can be detected prenatally by ultrasound examination. The clinical significance common to all anomalies is determined by their size, which can potentially cause vascular compromise and affect fetal growth. After birth, referral of the newborn to a pediatric surgery clinic for revision and correction is mandatory, but not an emergency, because there may be an abdominal wall defect or any other anomalies simultaneously.

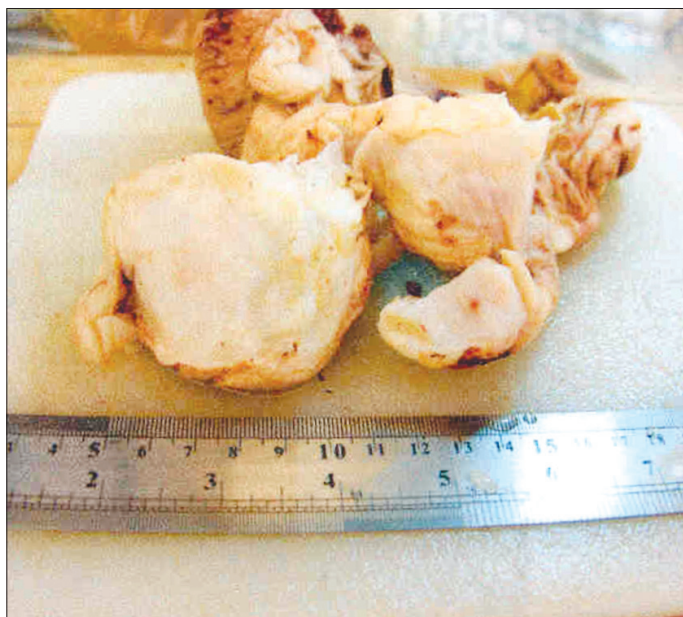Differential diagnosis of umbilical cord tumors should comprise umbilical cord teratoma, hemangioma and angiomyxoma. It can also be an umbilical cord polyp, umbilical cord cyst, hernia into the cord and omphalocele, which are mostly isolated findings, except for omphalocele (1).

Umbilical cord teratomas have a very polymorphic presentation. They are observed along the whole length of the cord. They are frequently covered with skin and can be solid and cystic. At the histological level, there are tissues from the three germinal layers. Associated anomalies can be observed in nearly half of the cases. Despite the large volume of some tumors, few obstetrical complications have been reported (2).

With advancing technology and use of ultrasound and maternal serum alpha-fetoprotein evaluation in the second trimester, it may be possible to diagnose hemangiomas of the umbilical cord in early gestation. The umbilical cord hemangiomas consist of an angiomatous nodule encompassed by edema and myxomatous degeneration of Wharton's jelly. They are



**Figure 4.** Increase in the size of the umbilical cord



**Figure 5.** White myxoid areas on the macroscopic section of the umbilical cord

located toward the placental end of the cord. These tumors originate from the umbilical artery, rarely from the vein or both. Morbidity and mortality rate of umbilical cord hemangiomas have been reported to be about 35% (3). They are attributed to the presence of coexisting factors, such as non-immune hydrops fetalis, intrauterine growth retardation, severe fetal hemorrhage and intrauterine fetal death as well as maternal obstetrical complications. To avoid the intrauterine and

postnatal complications, an early diagnosis of umbilical cord hemangioma is necessary. A close follow-up by ultrasound examination and color Doppler is recommended to elucidate the nature of placental masses (4, 5).

Angiomyxoma is a rare tumor of the umbilical cord and is associated with increased perinatal morbidity and mortality. Therefore, it should be considered when using prenatal ultrasound for detection of cystic lesion. Color Doppler imaging can easily detect perfusion through the umbilical vessels (6), so using high-resolution ultrasound and color Doppler, the umbilical cord tumor can be suspected to be an angiomyxoma without malformations in the fetus. As in our case, neither chromosomal aberrations nor elevated alphafetoprotein were found after amniocentesis or chordocentesis (7). Fetal MRI may be advised to diagnose any other associated anomalies. In our case, fetal MRI demonstrated an exact lesion about the umbilical cord. On pathologic examinations, an angiomyxoma of the umbilical cord with massive degeneration of Wharton's jelly was revealed (8). This tumor can allow uncomplicated spontaneous vaginal delivery (9). However, we performed a caesarean section because of the size of the umbilical mass. Rarely, umbilical cord tumor is recognized in a macerated stillbirth (10). Therefore, prenatal ultrasound and Doppler ultrasound should be used for detection of umbilical cord tumors.

#### Conflict of interest

None declared

#### References

1. Your diagnosis? Umbilical cord tumor. Natalucci G, Wisser J, Weil R, Stallmach T, Bucher U. *Eur J Pediatr*; 2007; 166: 753-6.
2. An umbilical cord teratoma in a 17-week-old fetus. Satge DCL, Laumond MA, Desfarges F, Chenard MPR. *Prenat Diagn* 2001; 21: 284-8.
3. Hemangioma of the umbilical cord. Sondergaard G. *Acta Obstet Gynecol Scand* 1994; 73: 434-6.
4. Hemangioma of the umbilical cord: Stenotic change of the umbilical vessels. Kamitomo M, Sueyoshi K, Matsukita S, Matsuda Y, Hatae M, Ikenoue T. *Fetal Diagn and Therapy*. Nov/Dec 1999; 14: 328-31.
5. Hemangioma of the umbilical cord: Report of a case. Caldarella A, Buccoliero AM, Taddei A, Savino L, Taddei GL. *Pathol Res Pract*. 2003; 199: 51-5.
6. Angiomyxoma of the umbilical cord. Cheng HP, Hsu CY, Chen CP, Su TH. *Taiwan J Obstet Gynecol*. 2006; 4: 360-2.
7. Angiomyxoma of the umbilical cord in one twin with cystic degeneration of Wharton's jelly. A case report. Tennstedt C, Chaoui R, Bollmann R, Dietel M. *Pathol Res Pract*. 1998; 194: 55-8.
8. Angiomyxoma of the umbilical cord with massive cystic degeneration of Wharton's jelly. Yavner DL, Redline RW. *Arch Pathol Lab Med*. 1989; 113: 935-7.
9. In utero decompression of umbilical cord angiomyxoma followed by vaginal delivery. Wilson Rd, Magee JF, Sorensen PH, Johnson A. *Am J Obstet Gynecol*. 1994; 171: 1383-5.
10. Angiomyxomas of the umbilical cord. Fortune DW, Ostör AG. *Obstet Gynecol*. 1980; 55: 375-8.