

Huge solitary primary pelvic hydatid cyst presenting as an ovarian malignancy: case report

Over kaynaklı tümör ile karışan büyük bir pelvik hidatik kist: vaka sunumu

Aysun Aybatlı¹, Petek Balkanlı Kaplan¹, Mehmet Ali Yüce¹, Ömer Yalçın²

¹Department of Obstetrics and Gynecology, Trakya University, Edirne, Turkey

²Department of Pathology, Trakya University, Edirne, Turkey

Abstract

Hydatid disease is a zoonotic parasitic infection caused by *Echinococcus granulosus*. *Echinococcus* cysts are found mostly in the liver (60%) and lung (15%), but they can be located in any part of the body. However pelvic echinococcosis as the primary site is rarely seen. We report the case of a large echinococcal cyst localized in the lower pelvis. A 76-year-old woman was admitted to an emergency department with urinary retention for ten days. Ultrasonography and other imaging modalities revealed a mass with solid and cystic components in pelvic localization. This unusual presentation in an elderly postmenopausal woman was initially considered as an ovarian malignancy until surgical exploration and microscopic studies confirmed the diagnosis of echinococcosis. Antihelminthics were administered postoperatively and the patient is now being closely followed up. Gynecologists should be aware of the possibility of a primary hydatid cyst of the pelvic cavity and should be considered in the differential diagnosis of cystic pelvic masses, especially in areas where the disease is endemic.

(J Turkish-German Gynecol Assoc 2009; 10: 181-3)

Key words: Hydatid cyst, echinococcal, pelvis

Received: 17 February, 2009 **Accepted:** 20 April, 2009

Özet

Hidatik kist *Ekinokokkus granulosus* tarafından oluşturulan bir parazitik kisttir. Çoğunlukla karaciğer (%60) ve akciğerde (%15) yerleşir. Fakat vücudun herhangi bir bölgesinde de olabilirler. Pelvik hidatik kist oldukça nadir görülür. Burda 76 yaşındaki pelvik hidatik kisti olan bir vaka sunuldu. Hasta acile 10 gündür idrar yapamama yakınması ile müracaat etti. Hasta cerrahi yapıp histopatolojik inceleme yapılan kadar over tümörü olarak değerlendirilmişti. Cerrahi sonrası antihelmintik tedavi başlandı. Jinekologlar özellikle de hastalığın endemik olduğu yörelerden gelen hastalardaki pelvik kitlelerde hidatik kisti de ayrıca tanıda düşünmelidirler.

(J Turkish-German Gynecol Assoc 2009; 10: 181-3)

Anahtar kelimeler: Hidatik kist, ekinokokus, pelvis

Geliş Tarihi: 17 Şubat 2009 **Kabul Tarihi:** 20 Nisan 2009

Introduction

Hydatid disease, or echinococcosis, is a parasitic infection caused by *Echinococcus* larvae. *Echinococcus granulosus* is the most common type and is endemic in the Mediterranean, Middle East, Eastern Europe and South America. Although it may attack all the organs, primary involvement of the pelvic cavity is a very rare entity and patients usually present with pressure symptoms affecting the adjacent organs (1). Nearly 80% of all pelvic cases involve the genital area, the ovary being the most frequent location (2). These cases are usually secondary to the accidental rupture of a cyst in other areas of the body (2). In this case report, we present the rare occurrence of a primary pelvic hydatid cyst which manifested itself with urinary problems and mimicking an ovarian malignancy.

Case report

A 76-year-old, gravida 2, para 2 woman was admitted to our emergency department with urinary retention. She had been

in menopause for 36 years. On bimanual examination, an intrapelvic adnexial mass extending anteriorly to the superior vaginal margins, approximately 100x120 mm in diameter, was palpated. Speculum examination was normal. Laboratory investigations including blood sugar, blood urea nitrogen, creatinine, liver enzymes, and urinalysis were normal. Chest radiograph was also normal. Although she had no previous history of hydatid disease, an indirect hemagglutination (IHA) test was found to be positive at a low dilution 1:160.

She was referred to radiology for an abdominal ultrasound (US) examination, which revealed a 104x71 mm round, heterogeneous mass with solid and cystic components located anterolaterally to the bladder in the pelvis. For further delineation of the mass and disease extension in the pelvic cavity, a computed tomography (CT) scan was performed that revealed a multiloculated, heterogeneous mass lesion approximately 126 x 104 x 89 mm in diameter in the pelvic cavity, extending to the right obturator space. It also revealed obliteration of the fatty tissue plane between the mass and bladder, right pubic wall and obturator canal. The liver and

other abdominal organs were completely normal, both on US and CT examinations. The patient underwent pelvic magnetic resonance imaging (MRI) which demonstrated that the mass was a multiloculated cystic lesion originating close to the arm of the right ischium bone and reaching to the ischiorectalis, ischianalis and obturator spaces (Figure 1).

The patient underwent an exploratory laparotomy under general anesthesia for further diagnosis of the mass and to rule out genitourinary malignancy after obtaining informed consent. At operation, a cystic mass 110x105 mm in size was identified retroperitoneally, anterior to the bladder, extending to the right obturator area and adhering to the right pelvic side wall. Both uterus and bilateral ovaries were seen normal. The cyst ruptured during exploration due to adhesions. All the contents were removed. The cystic cavity was irrigated with 3% sodium chloride solution to kill any remaining alive scolexes and aspirated. The wall of the cystic sac was then totally excised.

The pathology report confirmed the diagnosis of cyst hydatid (Figure 2). The patient recovered uneventfully and was discharged on the 9th postoperative day. Albendazole (per oral 800 mg per day) as adjuvant therapy was administered for six months postoperatively. The patient was kept under regular follow-up.

Discussion

Echinococcus granulosus is a 5-mm long worm, with a lifespan of 5-20 month within the jejunum of dogs. When eggs are ingested, they enter the portal circulation, and are then trapped in the liver (3). If they escape the hepatic filter, the embryos enter the systemic circulation and settle in the lungs or, unusually, in other organs.

Hydatid disease located in the pelvis is very rare. In most cases, coexistent cysts are detected elsewhere, usually in the liver.

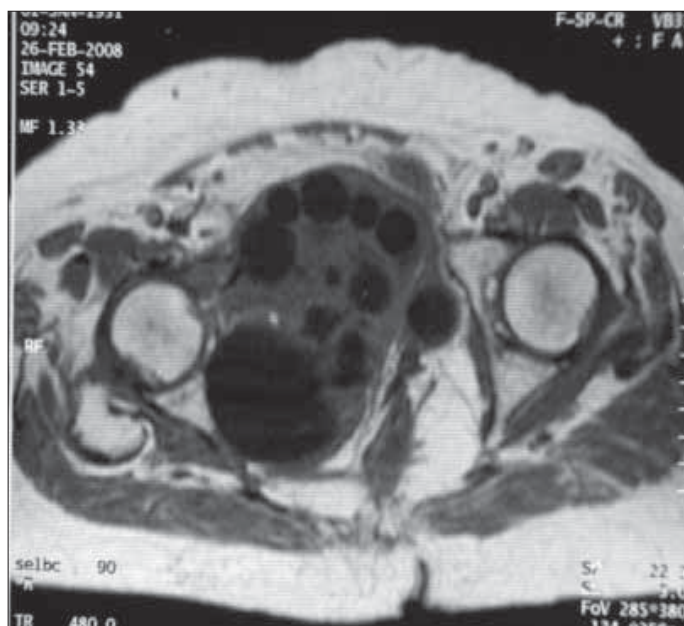


Figure 1. Sagittal MRI demonstrates lesion with solid and cystic components




Figure 2. The wall of the hydatid cyst. Note the fibrolamellar membrane and the inner germinative layer. HE, X50

Only a few cases of primary pelvic hydatid cyst have been reported (1, 4-7) and primary pelvic involvement is exceedingly rare. In the presented case, the absence of cysts in other organs was clearly demonstrated by exploration of the abdomen and imaging techniques, and isolated pelvic hydatid cyst was confirmed. Additionally, in our case, as a unique finding, the patient was 76 years of age, older than the previously reported cases in the literature.

The symptoms of pelvic echinococcosis are not specific and may involve abdominal pain, swelling, menstrual irregularities, infertility, obstruction of labor and pressure symptoms from adjacent organs including the bladder and rectum (8). In our patient, the primary complaint was urinary retention.

Pelvic echinococcosis may simulate malignancies and mimic a multicystic ovary (9). In our case, the solid component of the cyst and the patient's advanced age also raised the possibility of malignancy. Also, the present case underlines the possibility of resemblance between the clinical and radiological manifestation of the hydatid cyst and malignant disease of the reproductive organs.

Ultrasound (US) is an important imaging modality for hydatid disease and may clearly demonstrate the floating membranes, and daughter cysts characteristically seen in purely cystic lesions. The ultrasonographic findings range from purely cystic lesions to a completely solid appearance (9). CT also confirms the diagnosis by revealing the presence of daughter cysts and plaque-like calcifications in the cystic wall.

Surgical intervention is the treatment for pelvic hydatid disease. Laparotomy should be the choice in order to avoid intraoperative rupture of the cyst. Surgical treatment can be either radical or conservative. Total cystectomy, whenever possible, is the gold standard (3). In other cases of pelvic hydatid cyst in the literature, cyst extirpation and aspiration with saline or other agents have been performed. It is very important to use a scolicidal agent in the operating field such as a NaCl solution

or a povidone-iodine solution. Mebendazole or albendazole should be used as an adjunct to surgery (3). In many studies the efficacy of preoperative administration of albendazole have been evaluated and these studies showed that the rates of recurrence decreased with antihelminthic therapy (10, 11). Use of albendazole preoperatively for 3 months and should be continued for at least 1 month after surgical treatment (11).

In our case, in order to eradicate the disease, total cystectomy was carried out with dissection of the bladder from the cyst wall and in this way the bladder was freed from compression, and urination was greatly improved postoperatively. Since the diagnosis of the pelvic lesion could only be made during the exploratory laparotomy in our case, we had no opportunity to use albendazole therapy in the preoperative period.

In conclusion, since hydatid disease can occur in various organs or systems, we believe that in cases such as our patient, the most important factor in diagnosis of hydatid disease of the pelvic cavity is the high index of suspicion about its possibility. The optimal treatment is total cystectomy regardless of the location or, when impossible, unroofing and drainage followed by adjuvant antihelminthic therapy is the suboptimal treatment of choice.

References

1. M. Başaranoğlu, A. Sonsuz, A. Perek, S. Perek, and P. Akin. Primary pelvic hydatid cyst. *Journal of Clinical Gastroenterology*, 1998; 26: 157-8.
2. Rahman MS, Rahman J, Lysikiewicz A. Obstetric and gynecological presentations of hydatid disease. *Br J Obstet Gynaecol* 1982; 89: 665-70.
3. Hamamci EO, Besim H, Korkmaz A. Unusual locations of hydatid disease and surgical approach. *ANZ J Surg* 2004; 74: 356-60
4. Bounaim A, Sakit F, Janati IM. Primary pelvic hydatid cyst: a case report. *Med Trop* 2006; 66: 279-81.
5. Safioleas M, Stamatakos M, Zervas A, Aqapitos E. Solitary hydatid cyst in the pelvis: a case report. *Int Urol Nephrol* 2006; 38: 491-2.
6. Unal S, Kayhan B, Balos F, Gorgul A. Primary pelvic hydatid cyst. *J Clin Gastroenterol* 1996; 23: 303-4.
7. Aksu MF, Budak E, Ince U, Aksu C. Hydatid cyst of the ovary. *Arch Gynecol Obstet* 1997; 261: 51-5.
8. Dede S, Dede H, Caliskan E, Demir B. Recurrent pelvic hydatid cyst obstructing labor, with a concomitant hepatic primary. A case report. *J Reprod Med* 2002; 47: 164-6.
9. Pekindil G, Tenekeci N. Solid appearing pelvic hydatid cyst: transabdominal and transvaginal sonographic diagnosis. *Utrasound Obstet Gynecol* 1997; 9: 289-91.
10. Aktan O, Yalin R. Preoperative albendazole treatment for liver hydatid disease decreases the viability of cyst. *Eur J Gastroenterol Hepatol*. 1996; 8: 977-9.
11. Bildik N, Cevik A, Altıntaş M, Ekinci H, Canberk M, Gülmen M. Efficacy of preoperative albendazole use according to months in hydatid cyst of the liver. *J Clin Gastroenterol*. 2007; 41: 312-6.