

Prenatal diagnosis of fetal diastematomyelia: presentation of two cases

Fetal diastematomiyelinin prenatal tanısı: iki olgu sunumu

Oluş Api, Aybala Akıl, Orhan Ünal

Dr Lutfi Kırdar Education and Research Hospital, Department of Obstetrics and Gynecology, Istanbul, Turkey

Abstract

Objective: To present clinical and ultrasonographic features of two fetal diastematomyelia cases diagnosed prenatally.

Cases: The first presented case was a 19 years old, gravida 1, para 0 woman and was admitted to our perinatology clinic at 21 weeks of gestation. She was referred with a prediagnosis of spina bifida at the level of the fifth lumbar vertebra. A widening of the spinal canal, echogenic bony spur traversing the spinal canal, intact skin and soft tissues overlying the affected spinal segment were detected upon detailed ultrasonographic examination. There were no associated spinal anomalies and maternal serum alfafetoprotein level was within normal ranges. The patient was counseled about the malformation and its favourable prognosis. The baby girl was delivered at 38 weeks of gestation and she underwent an operation for correction of the tethered cord at 3 months of age. Currently, she is 8 months old having no neurological sequelae.

The second case was 22 years old, gravida 1, para 0 woman referred to our perinatology clinic at 19 weeks of gestation. Upon detailed ultrasonographic evaluation, an abnormal appearance of spinal curvature, intact skin overlying the spine and a bony spur traversing the spinal cord were detected whereas there were no cranial signs of open spina bifida. Magnetic resonance imaging (MRI) revealed diastematomyelia and severe kyphoscoliosis. Fetal karyotype, maternal serum alfafetoprotein and amniotic fluid acetylcholinesterase (AF-AChE) analyses were normal. The pregnancy was terminated at 20 weeks of gestation.

Conclusion: Diastematomyelia is a rare abnormality of the spinal canal which may be associated with other spinal anomalies. The ultrasonographic findings of diastematomyelia are a widening of the spinal canal and a bony spur traversing the spinal canal. Isolated cases of diastematomyelia have an excellent prognosis with surgical repair.

(J Turkish-German Gynecol Assoc 2009; 10: 124-7)

Key words: Prenatal diagnosis, fetal, ultrasonography, diastematomyelia

Received: 27 January, 2009 **Accepted:** 18 March, 2009

Introduction

Diastematomyelia is a rare form of spinal dysraphism in which the spinal cord is divided into two columns by a cartilaginous or osseous spur. Diastematomyelia may be isolated or it may be associated with other spinal anomalies such as spina bifida, kyphoscoliosis, butterfly vertebra or hemivertebra. In isolated diastematomyelia, the skin is intact and the prognosis is favourable. Diastematomyelia can be diagnosed

Özet

Amaç: Prenatal olarak tanılanan iki fetal diastematomiyeli olgusunun klinik ve ultrasonografik özelliklerinin sunumu.

Olgular: Sunulan ilk olgu 19 yaşında, gravida 1, para 0 idi, perinatoloji kliniğimize 21. gebelik haftasında başvurdu. Kliniğimize refere edilme nedeni, beşinci lomber vertebra seviyesinde spina bifida öntanısı idi. Detaylı ultrasonografik incelemede spinal kanalda genişleme, spinal kanalı çaprazlayan ekojenik kemik çıkıntı, etkilenen spinal segmentin üzerindeki cilt ve yumuşak dokuların intakt olduğu saptandı. Beraberinde spinal anomali yoktu ve maternal serum alfafetoprotein seviyeleri normal sınırlardaydı. Hasta bu malformasyon ve olumlu prognozu hakkında bilgilendirildi. Otuzsekizinci gebelik haftasında doğan kız bebek, üç aylıkken 'tethered' spinal kord nedeniyle operasyon geçirmiştir. Bebek şu anda sekiz aylık olup, herhangi bir nörolojik sekel kalmamıştır. İkinci olgu, 22 yaşında, gravida 1, para 0 idi ve perinatoloji kliniğimize 19. gebelik haftasında refere edildi. Detaylı ultrasonografik incelemede spinal kurvaturda anormal görünüm, omurganın üzerinde intakt cilt ve spinal kordu çaprazlayan kemik çıkıntı saptanırken, açık spina bifidaya ait kraniyal bulgu saptanmadı. Manyetik rezonans görüntüleme (MRG) diastematomiyeli ve şiddetli kifoskolyoz saptandı. Fetal karyotip, maternal serum alfafetoprotein ve amniyotik sıvı asetilkolinesteraz (AF-AChE) analizleri normaldi. Gebelik, 20. gebelik haftasında sonlandırıldı.

Sonuç: Diastematomiyeli, spinal kanalın, başka spinal anomalilerle birlikte görülebilecek olan nadir bir bozukluğudur. Diastematomiyelinin ultrasonografik bulguları spinal kanalda genişleme ve spinal kanalı çaprazlayan bir kemik çıkıntı bulunmasıdır. İzole diastematomiyeli olgularının olumlu bir prognoza sahip olduğu bilinmektedir. İzole diastematomiyeli vakaların cerrahi onarım sonrası çok iyi bir prognoza sahiptir.

(J Turkish-German Gynecol Assoc 2009; 10: 124-7)

Anahtar kelimeler: Prenatal tanı, fetal, ultrasonografi, diastematomiyeli

Geliş Tarihi: 27 Ocak 2009 **Kabul Tarihi:** 18 Mart 2009

on prenatal sonograms by detecting widening of the spinal canal in the coronal plane and an echogenic spur traversing the spinal canal in the axial plane (1). The management of pregnancy depends on whether the diastematomyelia is isolated, the skin is intact, or is in association with more serious neural tube defects (2). Herein, we present the sonographic features and outcomes of two cases of diastematomyelia diagnosed prenatally in our institution.

Case 1

A 19 year old, gravida 1, para 0 woman was referred to our perinatology clinic at 21 weeks of gestation due to a presumed diagnosis of spina bifida at the level of fifth lumbar vertebra during routine obstetric ultrasonographic evaluation. On detailed ultrasonographic examination, a widening of spinal canal in the coronal view, additional echogenic bony spur traversing the spinal canal in the axial plane, intact skin and soft tissues overlying the affected spinal segment were found (Figure 1). There were no cranial signs of open spina bifida such as ventriculomegaly, lemon or banana signs (Figure 2). There were no associated spinal anomalies such as spina bifida, kyphoscoliosis, butterfly vertebra or hemivertebra and the maternal serum alphafetoprotein level was within normal ranges. No associated major or minor fetal abnormalities were detected on ultrasonography and the final diagnosis was isolated diastematomyelia. The parents-to-be decided to continue with the pregnancy.

A 2.980 gram baby girl was delivered by cesarean section at 38 weeks of gestation. On neonatal physical examination, the skin overlying the vertebral column was intact and there was hair

on the affected segment. The baby underwent an operation for correction of the tethered cord at the age of three months. Currently, she is eight months old having no neurological sequelae.

Case 2

A 22 year old, gravida 1, para 0 woman was referred to our perinatology clinic at 19 weeks of gestation due to a presumed diagnosis of spina bifida. There was an abnormal appearance of spinal curvature (kyphoscoliosis), intact skin overlying the spine, a bony spur traversing the spinal cord whereas there were no cranial signs of open spina bifida upon detailed ultrasonographic examination (Figure 3, 4). Magnetic resonance imaging (MRI) further confirmed the diagnosis (Figure 5, 6). Neither other vertebral abnormalities such as hemivertebra, butterfly vertebra nor spina bifida were detected. Karyotype, maternal serum alphafetoprotein, amniotic fluid alphafetoprotein and acetylcholinesterase (AF-AChE) analyses were all normal.

After the counseling, the parents opted for termination of pregnancy. The pregnancy was terminated at 20 weeks of gestation. Postmortem examination could not be performed due to the

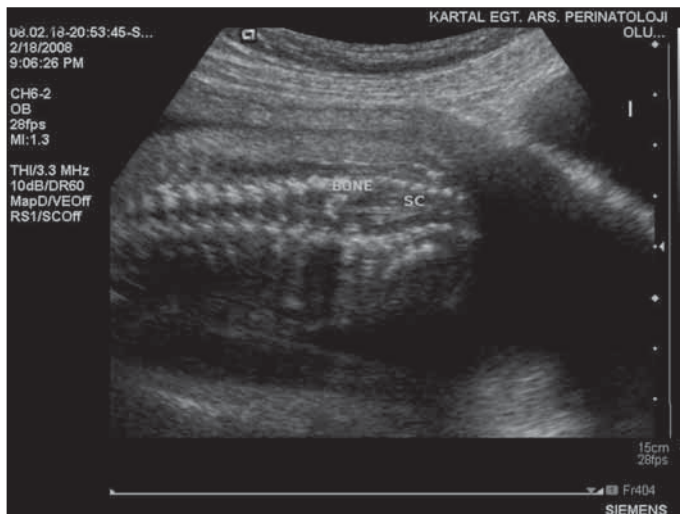


Figure 1. Coronal view of the fetal spine with the bony spur

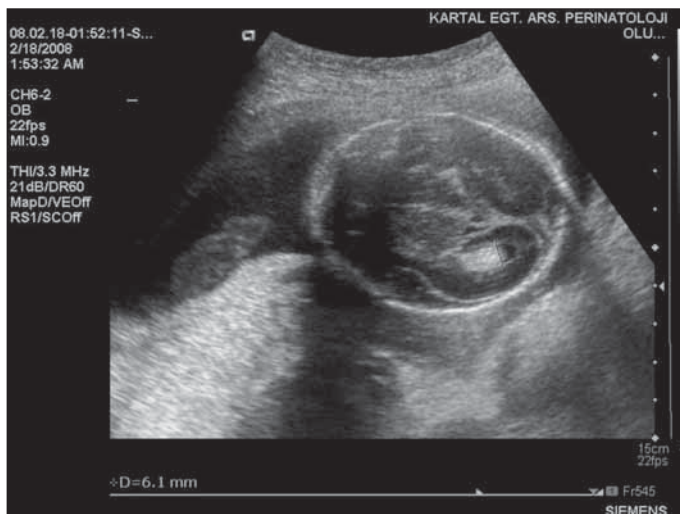


Figure 2. Ultrasonographic appearance of the fetal cranium in Case 1

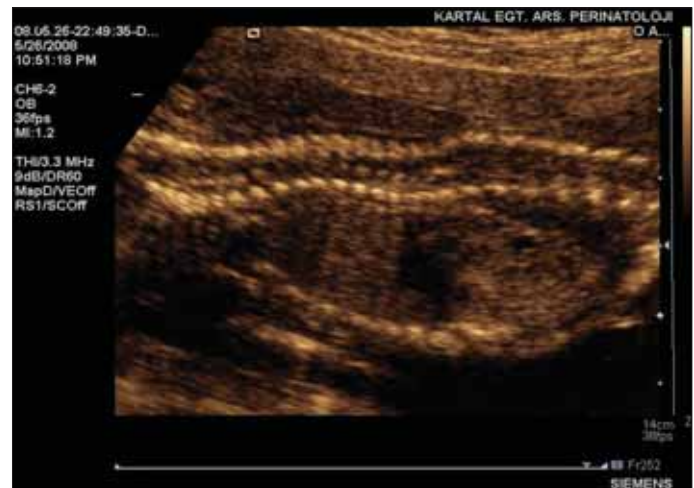

Figure 3. Sagittal view of the fetal spine with the bony spur and kyphoscoliosis

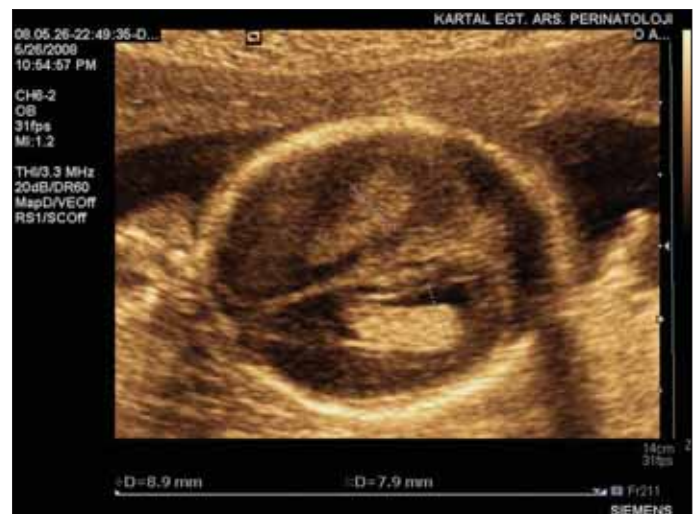

Figure 4. Ultrasonographic appearance of the fetal cranium in Case 2

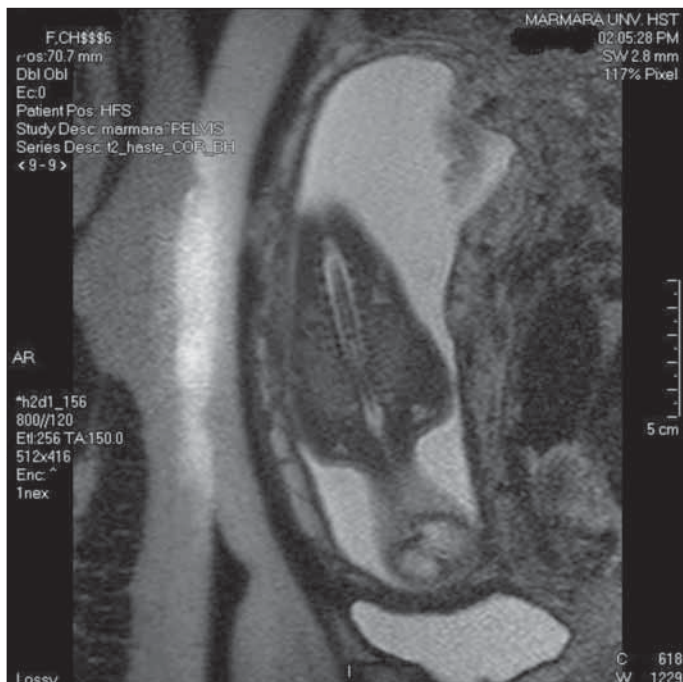


Figure 5. MRI of the fetal spine in Case 2. Two hemicords are seen separately ending as a single conus medullaris

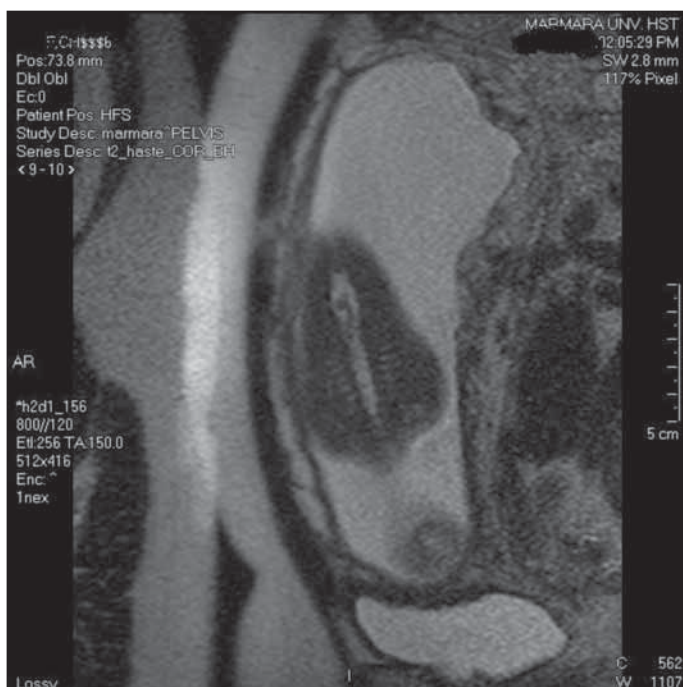


Figure 6. MRI of the fetal spine in Case 2. The bony spur in the lumbosacral junction

diastematomyelia. Fetal MRI was not further performed since the diagnosis of open spina bifida was excluded due to the abovementioned ultrasonographic criteria and normal maternal serum AFP levels.

In the second case, abnormal spinal curvature was the most striking sonographic abnormality. Detailed sonographic examination and the fetal MRI revealed an extra echogenic focus at

the lower thoracal spinal level. The spinal canal was dilated below the level of the bony spur. The diagnosis was kyphoscoliosis and diastematomyelia. In diastematomyelia of the fetus, the most important factor in terms of prognosis is the presence of associated spinal abnormality, and fetal MRI is another diagnostic tool for detecting them (1). However, fetal MRI did not change the diagnosis or add any information to our initial sonographic findings in this case, which was also pointed out by other authors (12, 13).

Both of our cases were referred to our clinic with the prediagnosis of spina bifida. The fetal spinal widening of diastematomyelia and distorted spinal curvature seem to have caused the impression of spina bifida. Since the prognosis and counseling issues differ widely in these two separate forms of spinal dysraphism, confident antenatal diagnosis has the utmost importance. Therefore, any fetus with spinal widening and abnormal spinal curvature should be carefully evaluated further with detailed fetal sonography in order to reach accurate diagnosis and proper management. The other adjunctive tools for accurate diagnosis of diastematomyelia are maternal AFP, amniotic fluid AFP (AF-AFP) and acetylcholinesterase (AChE). In our second case, all of these studies were performed in order to exclude a possible open spina bifida accompanying the abnormal spinal curvature. However, in the first case, AF-AFP and AChE were not analyzed due to normal maternal serum AFP levels and normal spinal curvature on ultrasonography.

The gestational age for diagnosis of our two cases were 21 and 19 weeks. This finding is similar to the mean gestational age reported by Has et al (1). In their review of the literature, the mean gestational age at diagnosis for diastematomyelia was 20.9±4.3 weeks. The first diagnosis made during first-trimester ultrasound screening (at 13 weeks) was reported by Has et al. which was the earliest diagnosis of diastematomyelia (1).

Isolated diastematomyelia has an excellent prognosis with surgical repair, whereas cases with associated neural tube abnormalities such as kyphoscoliosis have a prognosis more dependent on the severity of the associated abnormality (14). Surgical management is necessary to prevent loss of neurologic function and is usually performed electively within the first year of life. In the first case studied here, isolated diastematomyelia was surgically repaired successfully at three months of age. In the second case, the pregnancy was terminated due to the possible significant neurologic dysfunction which can be associated with severe kyphoscoliosis. Even though the ultimate functional outcome is dependent on early diagnosis and intervention in kyphoscoliosis, patients usually need repetitive surgical corrections and use of braces throughout their lives. The limitations imposed by these treatments are often emotionally difficult and may threaten self-image (15). After detailed counseling about these facts, the parents opted for termination of pregnancy.

In conclusion, prenatal diagnosis of diastematomyelia is possible with the use of proper diagnostic tools (e.g. ultrasonography, fetal MRI, maternal serum AFP, AF-AFP and AChE) and is necessary to prevent progressive neurologic sequelae.

References

1. Has R, Yuksel A, Buyukkurt S, Kalelioglu I, Tatli B. Prenatal diagnosis of diastematomyelia: presentation of eight cases and review of the literature. *Ultrasound in Obstetrics and Gynecology* 2007; 6:845-9.

2. Sepulveda W, Kyle PM, Hassan J, Weiner E. Prenatal diagnosis of diastematomyelia: case reports and review of the literature. *Prenat Diagn* 1997; 17: 161-5.
3. Miller A, Guille JT, Bowen JR. Evaluation and treatment of diastematomyelia. *J Bone Joint Surg Am* 1993; 75: 1308-17.
4. Suma V, Marini A, Panagopoulos P, Catapano P, Carollo C. Diastematomyelia. www.TheFetus.net. 1994-06-07-23. <http://www.thefetus.net/page.php?id=108>.
5. NG Anderson, S Jordan, MR MacFarlane, M Lovell-Smith. Diastematomyelia: diagnosis by prenatal sonography. *American Journal of Roentgenology* 1994; 163: 911-4.
6. Raghavendra BN, Epstein FJ, Pinto RS, Genieser NB, Horli SC. Sonographic diagnosis of diastematomyelia. *J Ultrasound Med* 1988; 7: 111-3.
7. Winter RK, McKnight L, Byrne RA, Wright CH. Diastematomyelia: prenatal ultrasonic features. *Clin Radio* 1989; 40: 291-4.
8. Williams RA, Barth RA. In utero sonographic recognition of diastematomyelia. *AJR* 1985; 144: 87-8.
9. Pachi A, Maggi E, Giacotti A, et al. Prenatal sonographic diagnosis of diastematomyelia in a diabetic woman. *Prenat Diagn* 1992; 12: 535-9.
10. Boulot P, Ferran JL, Charlier C, et al. Prenatal diagnosis of diastematomyelia. *Pediatr Radio* 1993; 23: 67-8.
11. Caspi B, Gorbacz S, Appeiman Z, Elchaial U. Antenatal diagnosis of diastematomyelia. *J Clin Ultrasound* 1990; 18: 721-5.
12. Cherif A, Oueslati B, Marrakchi Z, Chaouachi S, Chaabouni M, Abassi M, Dammak M, Chaabouni H, Boukef-Largueche S. Diastematomyelia. A propos de deux observations antenatales et revue de la littérature. *J Gynecol Obstet Biol Reprod* 2003; 32 : 476-80.
13. Sonigo-Cohen P, Schmit P, Zerah M, Chat L, Simon I, Aubry MC, Gonzales M, Pierre-Kahn A, Brunelle F. Prenatal diagnosis of diastematomyelia. *Childs Nerv Syst* 2003; 19: 555-60.
14. Sanders RC, Blackmon LR, Hogge WA, Spevak P, Wulfsberg EA. Diastematomyelia. In: *Structural fetal abnormalities: the total picture*. 2nd Ed. Missouri: Mosby; 2000. p42-44.
15. Hedequist DJ. Surgical treatment of congenital scoliosis. *Orthop Clin North Am*. 2007;38(4):497-509