

# Giant pedunculated aggressive angiomyxoma of the vulva: report of a case

*Olgu Sunumu: vulva'nın saplı, dev, agresif anjiyomiksomu*

Aykut Barut<sup>1</sup>, Mehmet Harma<sup>1</sup>, Müge Harma<sup>1</sup>, İlyas Özardalı<sup>2</sup>

<sup>1</sup>Department of Obstetrics and Gynecology, Faculty of Medicine, Zonguldak Karaelmas University, Zonguldak, Turkey

<sup>2</sup>Department of Pathology, Faculty of Medicine, Harran University, Şanlıurfa, Turkey

## Abstract

Aggressive angiomyxoma is a rare, slow-growing neoplasm of female pelvic soft tissues occurring almost exclusively in women of reproductive age. It is non-malignant but can be locally aggressive and frequently recurs. Misdiagnosis is frequent. Wide excision is the preferred method of treatment but the challenge is to perform the degree of extirpation necessary to prevent recurrence without causing unnecessary morbidity.

We present a case of a 45-year-old woman who presented with a non-painful mass in the right labium majus which was causing her difficulty in walking. The resected tumour weighed 4210 g. Details of the operative procedure are given. Diagnosis was by microscopy and immunochemistry.

Though rare, aggressive angiomyxoma should be considered in any young woman presenting with a well-defined mass arising from the perineum, vulva or lower pelvis.

(J Turkish-German Gynecol Assoc 2009; 10: 52-4)

**Key words:** Aggressive angiomyxoma, operative technique, pelvic neoplasm, soft tissue tumour, vulva

## Özet

Agresif anjiyomiksom, hemen daima reproduktif dönemde ortaya çıkan, kadın pelvik yumuşak dokularının nadir görülen ve yavaş gelişen neoplazisidir. Malign değildir ancak lokal agresif olup çoğunlukla nükseder. Yanlış tanı sıklıdır. Tedavide geniş eksizyon tercih edilir ancak gereksiz morbiditeye yol açmadan nüksü önleyecek derecede ekstirpasyon yapılmalıdır.

45 yaşında, sağ labium majör'den köken almış, hastanın yürütmesinde güçlük yaratan, ağrısız olguyu sunuyoruz. Rezeke edilen tümör 4210 gr tartıldı. Cerrahi işlemin ayrıntıları sunuldu. Tanı mikroskopi ve immünokimya ile konuldu.

Perine, vulva veya alt pelvis kaynaklı, iyi sınırlı kitlesi olan bir genç kadında, nadir olmasına rağmen anjiyomiksom düşünülmelidir.

(J Turkish-German Gynecol Assoc 2009; 10: 52-4)

**Anahtar kelimeler:** Agresif anjiyomiksom, ameliyat tekniği, pelvik neoplazi, yumuşak doku tümörü, vulva

## Introduction

Aggressive angiomyxoma (AAM) is a distinctive, slow growing soft tissue tumour that preferentially involves the vulval and perineal regions and is characterized by frequent local recurrences and infiltrative behaviour with extremely low metastatic potential (1). AAM was first described by Steeper and Rosai in 1983 (2). Since then, approximately 150 cases have been reported. However, its rarity, its frequent misdiagnosis, and issues in its management probably merit reporting of every case. We present a case of AAM of the vulva in a 45-year-old woman, review the literature and discuss the diagnosis and management.

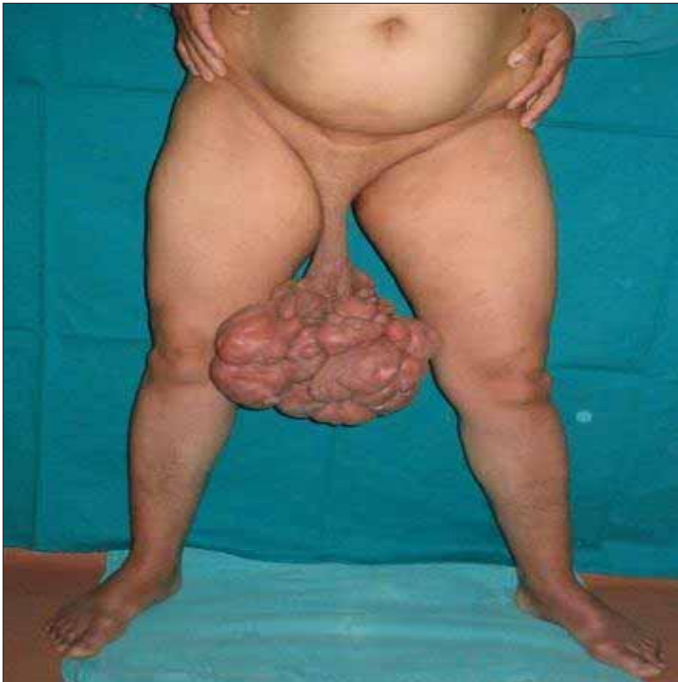## Case Report

A 45-year-old woman, gravida 5 para 5, presented with a non-painful mass in the right labium majus, which was causing her difficulty in walking and restricting her free movement. It had arisen a year before and had enlarged considerably over the past four months.

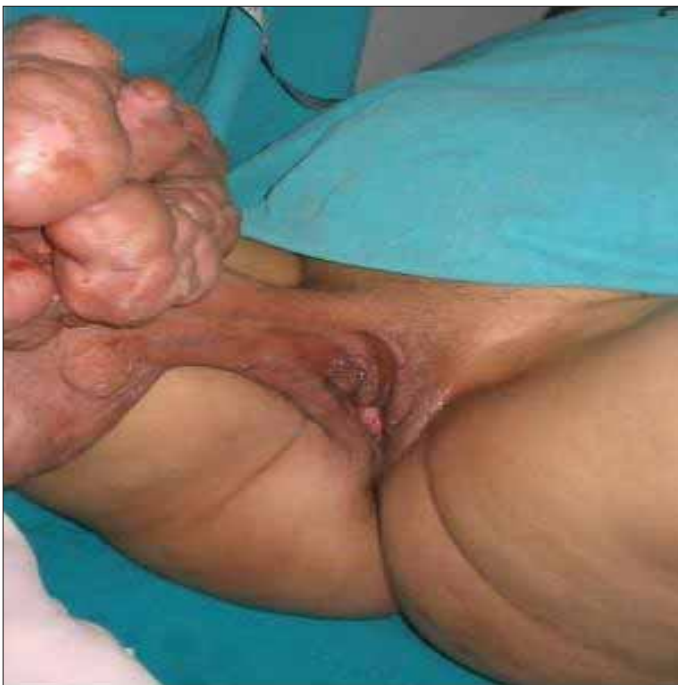Physical examination revealed a globular, semisolid, rubbery mass, measuring 25 x 25 x 30 cm and hanging from a thick 12 cm long pedicle, arising from the right labium majus. It was non-tender, covered with normal skin and had rough protuberances on its surface (Figures 1 and 2).

CT scans showed a mass of soft tissue originating from the right side of the vulva, without infiltration. Laboratory tests for tumour markers were negative.

The tumour was excised using a modified, combined technique (Figure 3), in order to preserve as much of the external genitalia as possible. Figure 3 shows that the standard elliptic incision would have required the right labia and the right distal opening of the vagina to be extirpated (blue lines). Using an inverted Y incision with a smaller elliptic incision (red lines) allowed the surgeon to reach the pedicle more proximal and more distant than would have been possible using the standard approach. Excision was then achieved simply by clamping the thick pedicle bite by bite. The resected tumour weighed 4210 g. After extirpation, the inverted Y incision was closed by separated mattress sutures with 3/0 Vicryl suture material. No drain

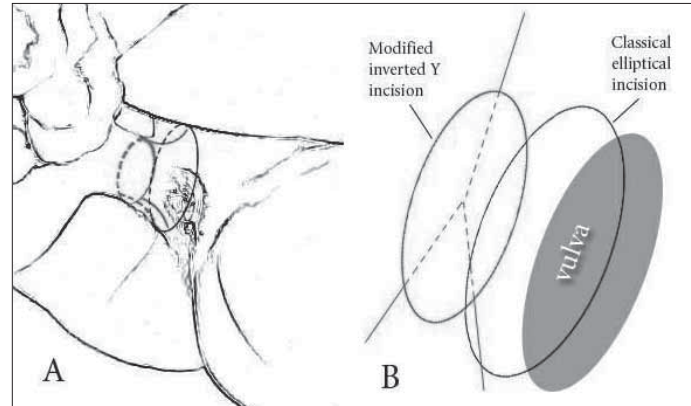


**Figure 1.** Patient at presentation, showing large mass hanging from thick pedicle and impeding walking



**Figure 2.** Pedunculated mass arising from right labium majus

was used, no wound contracture or dehiscence occurred and recovery was complete without any complication. The cut surface of the resected tumour had a grey, diffuse gelatinous, myxoid, semitranslucent gross appearance, with small hemorrhagic focuses but no cystic spaces. The surgical borders of the pedicle were negative for tumour. On microscopic examination, neoplastic mesenchymal cells ranged from stellate to spindle-shaped fibroblasts, without any significant nuclear atypia



**Figure 3.** Details of operative technique (modified, combined technique -an inverted Y incision with a smaller elliptic incision)

**A.** Blue lines indicate where the standard elliptical incision would have been made. Red lines show actual incision. Dotted lines are posterior to the pedicle.

**B.** Topographical projections of the incisions

or mitotic figures, infiltrating the surrounding adipose tissue and lying on a loosely textured myxoid to collagenous background. Clusters of blood vessels varying in size from tiny to large were arranged in the myxomatous stromal background, a characteristic feature of aggressive angiomyxoma. Some of vascular structures were congested. The tumour cells were diffusely staining for vimentin, negative for cytokeratin and S-100 protein, focally positive for actin and positive for oestrogen and progesterone receptors by immunohistochemistry. The endothelium of the blood vessels stained positively for CD34 antigens. These histological and immunohistochemical findings established the diagnosis of aggressive angiomyxoma. Written informed consent was obtained from the patient.

The patient is free of recurrence on a follow up after 57 months.

### Discussion

All of the reported cases of AAM of the vulva have presented as painless, slow-growing, polypoid, cyst-like masses in females between the ages of 15 and 77 years. The peak incidence of AAM is at 31-35 years of age (3). Our case extends this age range.

Most AAM of the vulva are >10 cm in their maximal dimension on presentation (4). While the AAM in our case is considerably larger than this, it is by no means the largest. Chen et al reported an AAM, arising from the right labium majus and extending into the retroperitoneum, which weighed 19.8 kg (5).

Misdiagnosis occurs in 82% of cases (6). Clinically, the differential diagnosis includes vulval abscess, Bartholin abscess, Gartner's duct cyst, vaginal cyst, vaginal mass or polyp, vaginal prolapse, pelvic floor hernia, obturator and levator hernia, vulval lipoma, pedunculated vulval leiomyoma, and vulvar hypertrophy with lymphedema.

Computed tomography (CT) may help to delineate AAM, but CT appearances are not as characteristic as magnetic resonance (MR) images (7).

Histomorphologically, the differential diagnosis includes fibroma, myxoid fibrosarcoma, lymphangioma, neurofibroma, malignant mesenchymoma, mixed mesodermal tumour, sclerosing hemangioma, botryoid pseudosarcoma, fibroangioma, embryo-

nal rhabdomyosarcoma, angiomyofibroblastoma, and cellular angiofibroma (8). However, AAM is the only myxoid tumour with a prominent vascular component (9).

Immunohistochemically, AAM cells may stain for actin, desmin, vimentin, oestrogen receptor and progesterone receptor, but are negative for S-100 protein, carcinoembryonic antigen and keratin (10). It has recently been suggested that special staining detecting abnormal architectural chromatin protein-high mobility group protein HMGA2 expression may be useful in the diagnosis of AAM, as well as identifying residual disease (11).

Removal of AAM is sometimes difficult because of its infiltrative nature. Perhaps for this reason, recurrence occurs in 70% of cases, but even patients with clear resection margins can develop recurrence (7). Nonetheless, excision (multiple in the case of recurrences) with wide tumour-free margins, as advocated by Elchalal et al in 1992 (12), is still the most common treatment. However, it is now considered that incomplete resection is acceptable when high operative morbidity is anticipated and preservation of fertility is an issue (3). In any case, long-term follow-up with MRI or CT scans is necessary (13, 14, 15). Since recurrence after 14 years has been reported (3), this needs to continue for some years.

A possible alternative means of treating recurrences is with a gonadotrophin-releasing hormone agonist (16). Similarly, Nakamura et al advocate antihormonal therapy (tamoxifen) as an adjuvant to prevent recurrences (17). Radiation therapy and chemotherapy are considered less suitable options due to low mitotic activity (18).

## References

- Blandamura S, Cruz J, Faure Vergara L, Machado Puerto I, Ninfo V. Aggressive angiomyxoma: a second case of metastasis with patient's death. *Hum Pathol* 2003; 34: 1072-4.
- Steeper TA, Rosai J. Aggressive angiomyxoma of the female pelvis and perineum: Report of nine cases of a distinctive type of gynecologic soft-tissue neoplasm. *Am J Surg Pathol* 1983; 7: 463-75.
- Chan YM, Hon E, Ngai SW, Ng TY, Wong LC. Aggressive angiomyxoma in females: is radical resection the only option? *Acta Obstet Gynecol Scand* 2000; 79: 216-20.
- Behranwala KA, Thomas JM. 'Aggressive' angiomyxoma: a distinct clinical entity. *Eur J Surg Oncol* 2003; 29: 559-63.
- Chen L, Schink JC, Panares BN, Barbuto D, Lagasse LD. Resection of a giant aggressive angiomyxoma in the Philippines. *Gynecol Oncol* 1998; 70: 435-9.
- Smith HO, Worrell RV, Smith AY, Dorin MH, Rosenberg RD, Bartow SA. Aggressive angiomyxoma of the female pelvis and perineum: review of the literature. *Gynecol Oncol* 1991; 42: 79-85.
- Jeyadevan NN, Sohaib SA, Thomas JM, Jeyarajah A, Shepherd JH, Fisher C. Imaging features of aggressive angiomyxoma. *Clin Radiol*, 2003; 58: 157-62.
- Fetsch JF, Laskin WB, Lefkowitz M, Kindblom LG, Meis-Kindblom JM. Aggressive angiomyxoma: a clinicopathologic study of 29 female patients. *Cancer* 1996; 78: 79-90.
- Mittal S, Kumar S, Baurasi P, Sharma MC. Aggressive angiomyxoma of the vulva-a case report. *Eur J Obstet Gynecol Reprod Biol* 1998; 81: 111-3.
- McCluggage WG, Patterson A, Maxwell P. Aggressive angiomyxoma of pelvic parts exhibits oestrogen and progesterone receptor positivity. *J Clin Pathol* 2000; 53: 603-5.
- Nucci MR, Castrillon DH, Bai H, Quade BJ, Ince TA, Genest DR, Lee KR, Mutter GL, Crum CP. Biomarkers in diagnostic obstetric and gynecologic pathology: a review. *Adv Anat Pathol* 2003; 10: 55-68.
- Elchalal U, Lifschitz-Mercer B, Dgani R, Zalel Y. Aggressive angiomyxoma of the vulva. *Gynecol Oncol* 1992; 47: 260-2.
- Corson SL, Rosato EL, Rosato FE, Eschelmann DJ. Aggressive angiomyxoma of the pelvis: case report and review. *Int J Fertil Womens Med* 2002; 47: 248-52.
- Alobaid A, Goffin F, Lussier C, Drouin P. Aggressive angiomyxoma of the vulva or perineum: report of three patients. *J Obstet Gynaecol Can* 2005; 27: 1023-6.
- Micheletti AM, Silva AC, Nascimento AG, Da Silva CS, Murta EF, Adad SJ. Cellular angiofibroma of the vulva: case report with clinicopathological and immunohistochemistry study. *Sao Paulo Med J* 2005; 123: 250-2.
- Fine BA, Munoz AK, Litz CE, Gershenson DM. Primary medical management of recurrent aggressive angiomyxoma of the vulva with a gonadotropin-releasing hormone agonist. *Gynecol Oncol* 2001; 81: 120-2.
- Nakamura T, Miura K, Maruo Y, Sunayama K, Maruyama K, Kashiwabara H, Ohata K, Fukazawa A, Nakamura S. Aggressive angiomyxoma of the perineum originating from the rectal wall. *J Gastroenterol* 2002; 37: 303-8.
- Bagga R, Keepanasseril A, Suri V, Nijhavan R. Aggressive angiomyxoma of the vulva in pregnancy: a case report and review of management options. *MedGenMed* 2007; 24: 9-16.