

Synchronous renal oncocyoma, endometrioid ovarian and endometrial carcinoma: a case report

Renal onkositom ile eş zamanlı endometrioid over ve endometrium kanseri

İncim Bezircioğlu¹, Ali Baloğlu¹, Levent Karıcı¹, Burcu Çetinkaya¹, Seyran Yiğit²

¹1st Department of Obstetric and Gynecology, Izmir Atatürk Training and Research Hospital, Izmir, Turkey

²Department of Pathology, Izmir Atatürk Training and Research Hospital, Izmir, Turkey

Abstract

The simultaneous presentations of endometrial and ovarian carcinomas are well-recognized. Oncocyoma is a benign renal tumor. In this presentation, it was purposed that the simultaneous presentations of endometrial, ovarian and renal tumors are reviewed. A 48-year-old woman presented with abdominal distention was found to have stage IB endometrioid cell carcinoma of the ovary, stage IC endometrial carcinoma of endometrioid type, and oncocyoma of the right kidney. Radical hysterectomy, bilateral salpingoopherectomy, retroperitoneal lymph node dissection, and right nephrectomy were performed. The present case is the first case of simultaneous presentation of renal oncocyoma, endometrioid type endometrial and ovarian carcinomas. (J Turkish-German Gynecol Assoc 2009; 10: 43-6)

Key words: Endometrial carcinoma, ovarian carcinoma, renal oncocyoma, synchronous carcinoma, renal tumor

Introduction

Oncocyoma is a non-frequent renal neoplasm. Oncocyoma is a benign tumor, and accounts for approximately 3-7% of all renal neoplasm's (1). A few cases of local invasion and metastases have been reported in the literature, but these probably represent chromophobe renal cell carcinoma, rather than oncocytomas. The preoperative distinction between benign oncocyoma and renal cell carcinoma is important because a correct diagnosis could allow patients to avoid aggressive surgical procedures. For distinction between renal oncocyoma and renal cell carcinoma, ultrasonography, magnetic resonance imaging, and computerized tomography scan can be performed, but the accurate diagnosis is not possible before surgery and histologic examinations of the specimens. The consensus for the treatment of oncocyoma is surgical excision. In patient with definite preoperative diagnosis, nephron sparing surgery or laparoscopic surgery could be performed (2).

The simultaneous presentations of endometrial and ovarian carcinomas are a well-recognized phenomenon. Most of them are metastatic lesions arising from either endometrial or ovarian carcinomas. Cancers occurring primarily and simultaneously in endometrium and ovary are relatively rare (3). These synchronous tumors occur in 5% of women with endometrial

Özet

Endometrium ve overin eş zamanlı kanserleri iyi tanımlanmıştır. Onkositom iyi huylu böbrek tümörüdür. Bu sunumda endometrium, over ve bôbreğin eş zamanlı tümörlerinin gözden geçirilmesi amaçlandı. Karnı şişkinliği ile başvuran 45 yaşındaki kadında evre IB endometrioid hücreli over kanseri, evre IC endometrium kanseri ve sağ bôbrekte onkositom saptandı. Radikal histerektomi, bilateral salpingoopherektomi, retroperitoneal lenf nodu diseksiyonu ve sağ nefrektomi yapıldı. Bu olgu yayınlanan ilk renal onkositom ile eş zamanlı endometrium ve overin endometrioid tip kanseridir.

(J Turkish-German Gynecol Assoc 2009; 10: 43-6)

Anahtar kelimeler: Endometrium kanseri, over kanseri, renal onkositom, eşzamanlı kanser, renal tümör

and 10% of women with ovarian cancers. The most frequent histological subtype of synchronous endometrial and ovarian cancer is endometrioid/endometrioid adenocarcinoma. These carcinomas account for 0.58% of all female genital cancer (4). Synchronous primary carcinomas of endometrium and ovary are seen in younger women, with lower parity, and they are more differentiated, at earlier stages, have lower invasion, and better prognosis than single carcinomas of endometrium and ovary (5).

In this paper, the first case of coexistence of renal oncocyoma, endometrioid type endometrial and ovarian carcinomas was presented.

Case Report

A 48-year-old (gravida 1, para 1) woman presented with abdominal distention and vaginal bleeding was found to have bilateral pelvic and right renal mass. There were hypertension and seizures in medical history. Family history of ovary and endometrium cancer was absent. Abdominal examination demonstrated a right flank and pelvic mass. The values of hemoglobin, creatinine, urea, and electrolytes were normal. Chest X-ray revealed few atelectatic slits on right bottom of lungs. Abdominal ultrasound showed an 8.5 cm mass in the right up-

per pole of kidney, 53x45x12mm measured uterus, 5mm thick endometrium, a pelvic solid mass of 125x75mm in diameter at right adnexial site, and ascites. Computerized tomography and magnetic resonance imaging confirmed these findings.

Ca125 and Ca199 levels were 1282 IU/ml, and 386 IU/ml, respectively. Preoperative endometrial biopsy revealed endometrioid type adenocarcinoma. Radical hysterectomy and bilateral salpingo-oophorectomy were performed. After intraoperative urology and pathology consultations, right nephrectomy, surgical staging including omentectomy, bilateral pelvic, para-aortic lymph node dissections were performed. Peritoneal washing fluid was collected for cytologic evaluation.

On macroscopic examination the specimen was composed of a 9x7x3cm measured uterus, normal fallopian tubes and ovaries measured 17cm on the right side, and 20cm on left side. Endometrial mass measured 6x3,5cm bulged into the endometrial cavity. The cross sections of both ovaries were solid, off white, and partially cystic. The microscopic appearance of the endometrial mass exhibited the features of moderately differentiated histological grade II, with >1/2 myometrial invasion (Figure 1). The sections of the ovaries showed histological grade II, malignant endometrioid tumor, and both of the capsules were intact (Figure 2).

Omentum and dissected lymph nodes from bilateral pelvic and para-aortic regions were negative for any metastatic neoplasm. The right nephrectomy specimen was measured 16x9x3cm. On sectioning, in the upper pole of the kidney, there was a well circumscribed, tan colored tumor, with a large central area of hemorrhage, measuring 9x9cm in diameter. The tumor was composed of cells with abundant granular eosinophilic cytoplasm growing in a tubular manner. The nuclei were small, round, and regular with a centrally placed nucleolus (Figure 3).

The surgical-pathologic stage of ovarian endometrioid adenocarcinoma was IB and of endometrial carcinoma was IC. Pathologic diagnosis of renal mass was oncocytoma. She underwent postoperative radiotherapy. Seventeen months after surgery, she remained well without evidence of recurrence.

Because of our inadequate laboratory circumstances, the genetic investigation of BRCA1 and BRCA2 germline mutation couldn't be done.

Discussion

Synchronous multiple primary tumors are relatively rare. While the etiology and pathogenesis of these tumors remain unclear, it has been proposed that embryologically similar tissues, when simultaneously subjected to either hormonal influences or carcinogens, may develop synchronous neoplasms (6). The most common synchronous gynecological neoplasms are ovarian and endometrial cancers in the literature. Patients suffering from primary genital malignancies are sometimes co-afflicted with other primary cancers (7,8).

On the other hand, many cases of histological distinct renal tumors occurring coincidentally in the same patient and cases of urologic cancers associated with colorectal and endometrial cancer have been reported (9,10). The cases with familial cancer syndromes like the Lynch syndrome are at high risk for cancer, including cancers of the upper urologic tract, ovary, colorectal and endometrial cancers (11).

However renal oncocytoma which is categorized as benign neoplasm has several features that overlap with other renal neoplasms

such as chromophobe, granular, and papillary renal cell carcinomas. Lack of knowledge of this entire spectrum of eosinophilic renal cell neoplasms has led to several misconceptions in the literature regarding renal oncocytoma. It is frequently difficult to distinguish renal cell carcinoma from benign renal oncocytoma on clinical or radiologic grounds. The accurate diagnosis of renal tumors can only be made histologically. In

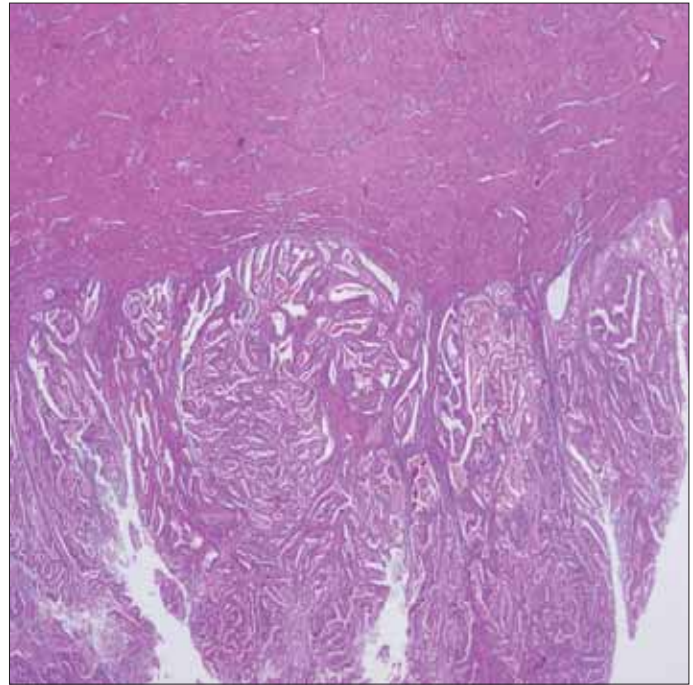


Figure 1. The microscopic appearance of the endometrial carcinoma (H&E x100)

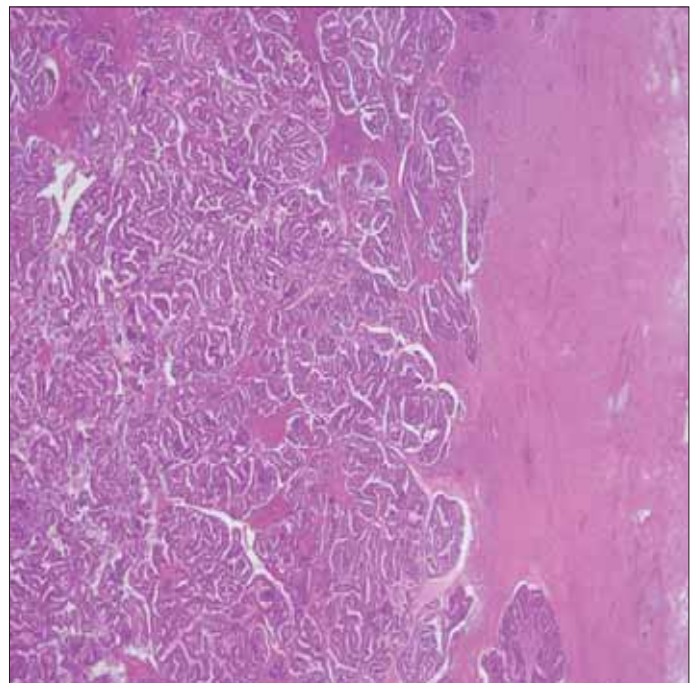


Figure 2. The microscopic appearance of malignant ovarian endometrioid tumor (H&E x100)

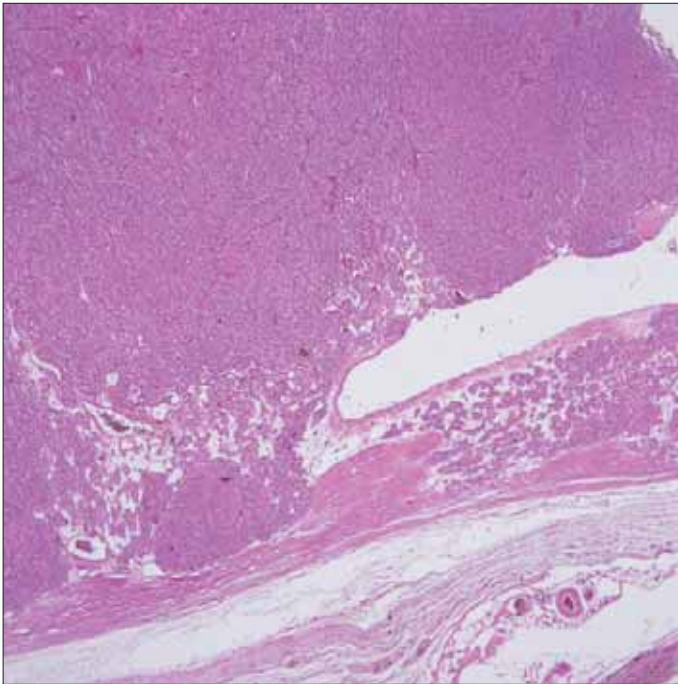


Figure 3. The microscopic appearance of oncocytoma (H&Ex100)

addition, in 10% of cases, multiple, distinct renal tumors occurring synchronously have been reported (12). It's accepted that oncocytomas and renal cell carcinomas has a common pathogenic denominator (13). Renal oncocytomas which might be sporadic and familial are generally encountered in seventh and eighth decades (14,15).

Because of difficulties of preoperative distinguishing of renal cell carcinoma from renal oncocytoma, the treatment of solid renal mass is preferred as nephrectomy (10). Nephron sparing surgery is recommended for renal oncocytoma wherever possible.

Synchronous ovarian and endometrial cancer constitutes the most common synchronous gynecological neoplasms (6). The most frequent histological subtype is endometrioid adenocarcinoma on both tissues. The synchronous primary cancers of endometrium and ovary are generally encountered in younger women then separately developed endometrium and ovary carcinomas. The median ages of women with synchronous primary cancers of endometrium and ovary are 49-50 years (4,16). Most of cases are premenopausal (4,5). The histological types of endometrial and ovarian carcinomas were endometrioid/endometrioid in presented case. The case was 45 years old and premenopausal.

The incidence of poorly differentiated carcinoma is significantly lower in women with endometrioid/endometrioid subtype. Soliman et al found lymph-vascular space invasion in 31% and >50% myometrial invasion in %66 of their cases (5). In our patient histological grade of both tumors were grade II and there was no lymph-vascular space invasion and no myometrial invasion more than 50%.

92-95% of synchronous primary cancers of endometrium and ovary have FIGO stage I-II endometrial cancer, and 37-39% of the cases have FIGO stage I ovarian cancer (4,5). Our patient was found to have FIGO stage IB endometrioid cell carcinoma of the ovary and stage IC endometrial carcinoma of endometrioid

type. The patient with endometrioid/endometrioid synchronous primary cancers of endometrium and ovary has better overall survival (4,5,17,18). Our patient was well without the evidence of any disease during 14 months of postoperative period.

Primary ovarian carcinoma is followed by an increased risk of developing endometrial carcinoma. The risks of developing many other malignancies including intestinal malignancies, renal cell carcinoma, bladder carcinoma, squamous cell skin carcinoma, connective tissue malignancies, and leukemia are also increased in women with endometrial carcinoma (7). The 5-year survival rates for patients with endometrial carcinoma and ovarian carcinoma were >80%, and >40%, respectively. Some subsequent neoplasms can develop after the treatment of endometrial and ovarian carcinomas. According to the Swedish Family-cancer Database, after primary ovarian and endometrial carcinomas the incidence of subsequent malignancies at genitalia, bladder, and kidney increases. Familial cancer syndromes, radiotherapy, and chemotherapy also may contribute to the increased occurrence of secondary primer malignancies (8).

Familial cancer syndromes frequently account for diagnoses of multiple cancers in patients, or for the development of cancers at a young age in other patients. Distinct renal tumors occurring coincidentally in the same patient, sporadic and familial renal tumors, concurrent urothelial cancer and colorectal cancer, and coexistence of urothelial cancer with the Lynch syndrome have been reported. Like these findings, the coexistence of oncocytoma, endometrium, and ovarian cancer and the younger age of cases support a possible common pathogenetic mechanism among these tumors.

No case has been documented with the coexistence of oncocytoma, endometrium, and ovarian cancer in the related literatures. This is the first presented case of synchronous renal oncocytoma, endometrioid ovarian, and endometrial cancer.

References

1. Debby HC, Amnon Z, Allan P, Stephen F, Jonathan W. Said and Arie S. Changing concepts in the management of renal oncocytoma. *Urology* 2002; 59: 635-642.
2. Bilen H, Akçay MN, Erdoğan F, Akçay G. Coexisting simple renal cyst, renal oncocytoma, and pheochromocytoma. *J Dial Endocrinol* 2004; 1: 108-112.
3. Ree YS, Cho SH, Kim SR, Cho SH, Kim KT, Park MH. Synchronous primary endometrial and ovarian cancer with three different histologic patterns: A case report *Int J Gynecol Cancer* 2003; 13: 678-682.
4. Natee J, Kietpeerakool C, Srisomboon J, Khunamornpong S, Suprasert P, Phongnarisorn C, Cheewakriangkrai C, Charoenkwan K, Siritree S, Pantusart A. Clinicopathologic analysis of women with synchronous primary carcinomas of the endometrium and ovary: 10-year experience from Chiang Mai University Hospital. *Asian Pac J Cancer Prev* 2006; 7: 234-238.
5. Soliman PT, Slomovitz BM, Broaddus RR, Sun CC, Oh JC, Eifel PJ, Gershenson DM, Lu KH. Synchronous primary cancers of the endometrium and ovary: a single institution review of 84 cases. *Gynecol Oncol* 2004; 94: 456-462.
6. Tong SY, Lee YS, Park JS, Bae SN, Lee JM, Namkoong SE. Clinical analysis of synchronous primary neoplasms of female reproductive tract. *Eur J Obstet Gynecol Reprod Biol* 2008; 136: 78-82.
7. Bergfeldt K, Einhorn s, Rosendahl I, Hall P. Increased risk of second primary malignancies in patients with gynecological cancer. A Swedish record-linkage study. *Acta Oncol* 1995; 34: 771-777.

8. Hemminki K, Aaltonen L, Li X. Subsequent primary malignancies after endometrial and ovarian carcinoma. *Cancer* 2003; 97: 2432-2439.
9. Lam SK, Chung TK, Mackenzie TM, To KF, Wong YF, Cheung TH, Chang AM. Coincidental renal cell and endometrial carcinoma: a case report. *Gynecol Oncol* 1996; 60: 319-24.
10. Calderwood AH, Huo D, Rubin D. Association between colorectal cancer and urologic cancers. *Arch Intern Med* 2008; 168: 1003-9.
11. Watson P, Vasen HF, Mecklin JP, Bernstein I, Aarnio M, Järvinen HJ, Myrthøj T, Sunde L, Wijnen JT, Lynch HT. The risk of extra-colonic, extra-endometrial cancer in the Lynch syndrome. *Int J Cancer* 2008; 123: 444-9.
12. Dechet CB, Bostwick DG, Blute ML, Bryant SC, Zincke H. Renal oncocytoma: Multifocality, bilateralism, metachronous development and coexistent renal carcinoma. *J Urol* 1999; 162: 40-42.
13. Burger M, Denzinger S, Filbeck T, Hartmann A, Rössler W, Hammerschmied C. A metachronous, atypical, multifocal renal oncocytoma with a concomitant renal cell carcinoma of the contralateral side and bilateral multifocal oncocytomas: two case reports and review of literature. *Scientific World J* 2005; 5: 545-9.
14. Gudbjartsson T, Hardarson S, Petursdottir V, Thoroddsen A, Magnússon J, Einarrson GV. Renal oncocytoma: a clinicopathological analysis of 45 consecutive cases. *BJU Int* 2005; 96: 1275-9.
15. Fan YH, Chang YH, Huang WJ, Chung HJ, Chen KK. Renal oncocytoma: clinical experience of Taipei Veterans General Hospital. *J Chin Med Assoc* 2008; 71: 254-8.
16. Zaino R, Whitney C, Brady MF, Degeest K, Burger R, Buller R. Simultaneously detected endometrial and ovarian carcinomas- a prospective clinicopathologic study of 74 cases: a Gynecologic Oncology Group study. *Gynecol Oncol* 2001; 83: 355-362.
17. Ayhan A, Guvenal T, Coskun F, Basaran M, Salman MC. Survival and prognostic factors in patients with synchronous ovarian and endometrial cancers and endometrial cancers metastatic to the ovaries. *Eur J Gynecol Oncol* 2003; 24: 171-174.
18. Nishimura N, Hachisuga t, Yokoyama M, Iwasaka T, Kawarabayashi T. Clinicopathologic analysis of the prognostic factors in women coexistence ovary and endometrioid adenocarcinoma in the endometrium and ovary. *J Obstet Gynaecol Res* 2005; 31: 120-126.