

Validity of P57^{kip2} immunohistochemical marker in differential diagnosis of molar pregnancy

Molar gebeliklerin ayırıcı tanısında P57^{kip2} immünohistokimyasal belirtecinin geçerliliği

Nourieh Sharifi¹, Mohammad Hadi Sadeghian¹, Hossein Ayatollahi¹, Mohammad Khajeh Daluei²,
Ali Reza Rezaea¹, Mohammad Reza Keramati¹

¹Pathology Department, Mashhad University Of Medical Sciences, Mashhad, Iran

²Social Medicine Department, Mashhad University Of Medical Sciences, Mashhad, Iran

Abstract

Objective: The differentiation of complete mole from partial mole and hydropic abortion is very important for patient management.

The aim of this study was to determine the validity of p57^{kip2} in the diagnosis of hydatidiform mole

Material and Method: Immunohistochemistry with the P57^{kip2} antibody was done in formalin-fixed paraffin-embedded samples of hydropic abortion (n=20), simple abortion (n=20), partial hydatidiform mole (n=20) and complete hydatidiform mole (n=20). Immunoreactivity was recorded separately in the different cellular components, such as villous cytotrophoblast, extravillous trophoblast, syncytiotrophoblast, stromal cells, and decidual cells. Then data were analyzed with suitable statistical test.

Results: In partial hydatiform mole and also in simple and hydropic abortion, nuclear P57^{kip2} expression was observed at high frequency in cytotrophoblast, villous stromal cells and maternal decidua, but was absent in syncytiotrophoblast. Absent of nuclear immunoreactivity of cytotrophoblasts was detected in the majority (95%) of complete hydatiform mole. Significant difference was seen for P57^{kip2} expression in complete hydatiform mole in comparison with hydropic abortion (P=0.001) and partial hydatiform mole (P=0.001).

Conclusions: This study confirms that P57^{kip2} immunohistochemistry can reliably identify most cases of complete hydatidiform mole and distinguishes it from hydropic abortions and partial hydatidiform mole.

(J Turkish-German Gynecol Assoc 2009; 10: 39-42)

Key words: Complete mole, Partial mole; Hydropic abortus; P57^{kip2}

Introduction

Gestational trophoblastic disease (GTD) encompasses a heterogeneous group of neoplastic conditions arising from the placenta. The lesions include the hydatidiform mole (complete, partial), the invasive mole, choriocarcinoma and placental site trophoblastic tumor (1).

Hydatidiform mole is classified into partial and complete subtypes according to histological and genetic criteria. In complete hydatiform mole (CHM), all or most of the villi are edematous and there is diffuse trophoblast hyperplasia. It is well known that most CHMs have a 46, XX (diploid) karyotype with both X chromosomes being of paternal origin and all derived from

Özet

Amaç: Hasta yönetiminde hidropik abortus ve parsiyel molen komplet molün ayrımı çok önemlidir. Bu çalışmanın amacı hidatiform molün teşhisinde P57^{kip2}'nin geçerliliğini belirlemektir.

Gereç ve Yöntemler: Hidropik abortus (n=20), basit abortus (n=20), parsiyel hidatiform mol (n=20) ve komplet molen (n=20) oluşan örneklem formalin ile fikse edilmiş paraffinle kaplanmış P57^{kip2} antikoruna ile immünohistokimyasal inceleme yapıldı. İmmünoreaktif inceleme farklı hücresel komponentler için ayrı ayrı (örneğin villos sitotrofoblast, ekstravillos trofoblast, sinsiyotrofoblast, stromal hücreler ve decidual hücreler) kayıt altına alındı.

Bulgular: Parsiyel hidatiform mol ve aynı zamanda basit ve hidropik abortus da nükleer P57^{kip2} eliminasyonu sitotrofoblast, villos stromal hücreler ve maternal desidua da yüksek orandayken, sinsiyotrofoblastta eliminasyon yoktur. Sitotrofoblastlarda nükleer immünoreaktivite yokluğu komplet hidatiform molün çoğunluğunda (95%) saptandı. P57^{kip2} eliminasyonunda komplet hidatiform ile hidropik abortus (P=0.001) ve parsiyel hidatiform (P=0.001) mol kıyaslanıldığında anlamlı bir farklılık olduğu saptandı.

Sonuç: Bu çalışmada P57^{kip2} immünohistokimyasal marker'in güvenilir şekilde komplet hidatiform mol vakalarının çoğunluğunun tanımlanabileceği ve komplet hidatiform molün hidropik abortus ile parsiyel hidatiform molen ayrımını yapılabileceği doğrulanmaktadır.

(J Turkish-German Gynecol Assoc 2009; 10: 39-42)

Anahtar kelimeler: Komplet mol, parsiyel mol, hidropik abortus, P57^{kip2}

the sperm. They are presumed to result from fertilization by a single sperm of an egg that has lost its chromosomes or from the fertilization of such an empty egg by two sperm (2).

Approximately 15% to 35% of all moles are of the partial type. Partial hydatiform moles (PHM) have defined villous abnormalities and are usually triploid. Their diagnosis often can be made by morphology alone, without confirmation of ploidy. Partial moles should be distinguished on one hand from complete moles and on the other from the hydropic villi seen in 15% to 40% of spontaneous abortions (3).

Because unattended complete hydatiform mole may persist and recur, distinction of these moles from non-molar hydropic abortion and PHM is important. Whereas hydropic abortion

(HA) is completely benign, hydatidiform moles carry a significant risk for developing persistent GTD and the most important reason for the correct recognition of true moles is that they may precede choriocarcinoma. It was reported that 17% of CHMs developed into invasive moles and 2.5% of complete moles evolved into choriocarcinoma. In contrast to CHMs, partial moles are rarely followed by choriocarcinoma (3-5).

Although genetic studies are important in recognizing subtypes of hydatidiform mole but most cases of hydatidiform mole can be identified correctly by histologic analysis if adequate tissue is submitted and appropriate criteria are used (6-7). Recent studies suggested that P57^{kip2} (also known as KIP2) can be used in the differential diagnosis of molar pregnancies (8-9).

The P57^{kip2} protein is a cell cycle inhibitor and tumor suppressor encoded by a paternally imprinted gene. Cyclins and cyclin-dependent kinases (CDKs), determine a cell's progress through the cell cycle. The activity of cyclin-CDK complexes is tightly regulated by inhibitors, called CDK inhibitors. There are two groups of CDK inhibitors: the CIP/KIP and the INK4/ARF families. CDK inhibitors are instrumental in prevention of tumor formation, so they are known as tumor suppressors. The CIP/KIP family includes the genes p21, p27 and p57, which bind to and inactivate the complexes formed between cyclins and CDKs. Lack of p57^{kip2} activity leads to loss of cell cycle control and contributes in trophoblastic hyperplasia. Because P57^{kip2} is paternally imprinted, and both the X chromosomes in complete moles are derived from the father, it is expected that reduced or absent expression of P57^{kip2} protein in complete moles (4, 9-10).

Although there is not accurate report for prevalence and incidence of Molar pregnancy in Iran but according to one study in Tehran, the incidence of disease is 6.7/1000 live deliveries (11). Therefore hydatidiform mole is partially common in Iran and it is important for us to know the utility of p57^{kip2} immunohistochemical marker in differential diagnosis of molar pregnancy.

The goal of this study was to determine the validity of immunohistochemistry (IHC) technique in the identification of CHM in comparison with PHM and hydropic abortions.

Materials and Methods

A total of 80 formalin fixed paraffin embedded (FFPE) of placental tissue were retrieved from the files of the department of pathology of our hospital since February 2002 to February 2008. The criterion for selection was based on the histopathologic diagnosis. Tissue sections stained with hematoxylin and eosin were reviewed by two pathologists for tissue adequacy, confirmation of diagnosis and selection of the best region for IHC. The cases were selected to represent nonmolar (n=40) and molar pregnancy tissue (n=40). Nonmolar pregnancy tissues were consist of hydropic abortion (n=20) and the same number of simple abortion (not hydropic), also molar pregnancy tissues were included partial hydatidiform mole (n=20) and complete hydatidiform mole (n=20). All the cases presented mean of gestational age between 11 and 12 weeks. None of them had been received chemotherapy before the samples, which were used for diagnosis.

Immunohistochemistry study was performed on 4 micrometer FFPE tissue sections using the avidin-biotin-peroxidase complex method (12) by monoclonal primary antibody against P57^{kip2}

protein (Mouse Monoclonal antibody, P57^{kip2} protein, Visiobiosystem, United Kingdom, clone: 25B2).

After deparaffinization & rehydration through a graded series of alcohol solutions, sections were incubated at room temperature for 24 hours, then different steps of IHC staining performed regarding to the manufacturer instructions and finally counterstaining with hematoxylin were done.

Normal placenta tissue was used as positive control of P57^{kip2} marker and negative controls were prepared by omission of the primary antibody. IHC slides were examined by two pathologists for immunoreactivity in cells nuclei while they did not know about the slide diagnosis. Therefore the analysis was double-blind.

Positive reactivity was interpreted only when distinct nuclear staining was identified. Cells with only cytoplasmic granular staining were regarded as negative. Immunoreactivity was recorded separately in the different cellular components, such as villous cytotrophoblast, extravillous trophoblast, syncytiotrophoblast, stromal cells, and decidual cells. The staining of equal or more than 10% of total cytotrophoblast cells were presumed positive and results below of this threshold considered negative.

Immunoreactivity results in two groups of nonmolar and molar pregnancy were analyzed with SPSS (Statistical software for social analysis – Version 11.5) by a specialist of statistics and using T test and chi-square test. A P-value under 0.05 ($P \leq 0.05$) was considered significant.

Results

The age range in nonmolar pregnancy group or control group was from 17 to 40 years with 26.20 ± 5.08 years for mean \pm standard deviation (SD) and in molar pregnancy group (case group) was from 15 to 46 years with 23.82 ± 6.77 years for mean \pm SD and T test showed no significant differences between case and control group ($P=0.08$).

P57^{kip2} was strongly expressed in villous cytotrophoblast and villous mesenchyme in simple abortion, partial hydatidiform moles and spontaneous losses with hydropic changes (figure 1). In contrast, P57^{kip2} expression in villous cytotrophoblast, villous stromal cells and extravillous trophoblast was absent or markedly decreased in CHMs (figure 2).

Nuclear immunoreactivity in cytotrophoblasts for P57^{kip2} was detected in all cases with simple abortion (100%), 17(85%) cases of HA, 18 (90%) cases of PHM and one (5%) cases of CHM (Table 1). Fisher exact test showed significant difference ($P < 0.001$) for P57^{kip2} between two groups of nonmolar pregnancy and molar pregnancy.

There was no significant difference ($P=0.23$) for P57^{kip2} expression in HA and normal placental tissue but significant difference (Table 2) were seen for P57^{kip2} expression in CHM in comparison with simple abortion ($P < 0.001$), HA ($P < 0.001$) and PHM ($P < 0.001$).

Although all nonmolar pregnancy tissue had nuclear immunoreactivity in cytotrophoblasts for P57^{kip2} but five of them were weakly positive that defined for nuclear immunoreactivity in 0-10% of total cytotrophoblasts. Weakly positive results in cytotrophoblasts also were seen in six cases of HA and one case of PHM.

Extravillous trophoblast and decidual cells showed positivity in some cases (molar and nonmolar pregnancies) and Syncytiotrophoblast was negative in all cases.

Table 1. Summary results of nuclear immunoreactivity for P57^{kip2}

	SA Versus HA	SA Versus PHM	SA Versus CHM	HA Versus PHM	HA Versus CHM	PHM Versus CHM
Cytotrophoblast	P=0.23	P=0.48	P<0.001	P=1.00	P<0.001	P<0.001
stromal cells	P=1.00	P=1.00	P<0.001	P=1.00	P<0.001	P<0.001
Extravillous trophoblast	P=0.34	P=1.00	P=0.34	P=0.18	P=1.00	P=0.18
decidual cells	P=0.09	P=1.00	P=0.23	P=0.09	P=1.00	P=0.23

SA: Simple abortion; HA: Hydropic abortion; PHM: Partial hydatiform moles; CHM: Complete hydatiform mole

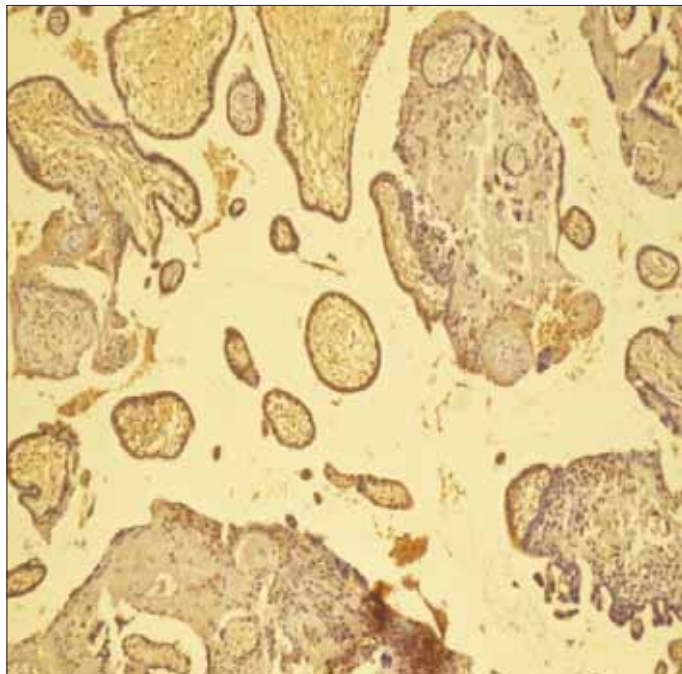


Figure 1. P57^{KIP2} expression in villous cytotrophoblasts in simple abortion

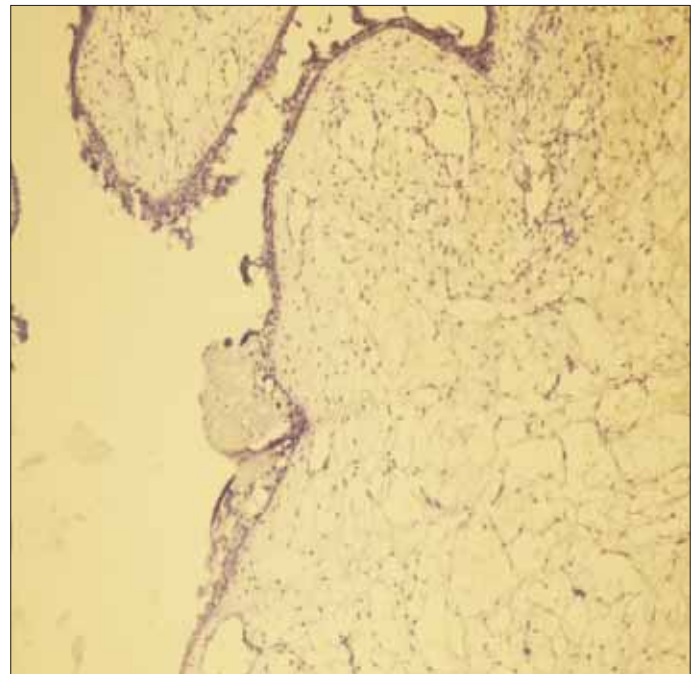


Figure 2. Lack of P57^{kip2} expression in villous cytotrophoblasts in complete hydatiform mole

Discussion

Hydropic villi in products of conception could be a diagnostic problem for the pathologist. It occurs in a spectrum of pathologic conditions including hydropic abortion, PHM, and CHM. The distinction between these entities is clinically important because partial and complete hydatidiform moles have some risk of developing persistent gestational trophoblastic disease whereas HAs do not. Detailed histopathologic examination remains to be the basis for the diagnosis of hydatidiform mole. However, poor sampling, necrosis, and earlier uterine evacuation can lead to uncertainty in the diagnosis. Also, the criteria are subjective, resulting in considerable interobserver variability (1;13-15). It is implicated immunoreactivity for p57^{KIP2} can be helpful in accurate diagnosis of CHM (16-17).

In Jun et al. study the immunohistochemical expression of P57^{kip2} protein was investigated to determine by using tissue sections of CHM (n=51), PHM (n=7), invasive mole (n=1), and hydropic miscarriage (n=2). They reported absent expression of P57^{kip2} in cytotrophoblasts covering the villous stroma (51/52) as well as villous stromal cells (51/52) in complete and invasive

moles and also strongly and continuously expression in both villous cytotrophoblast and stromal cells in all cases of PHM and hydropic miscarriage (17).

We also found almost no immunoreactivity (95%) in cytotrophoblasts for p57^{kip2} in CHM that is concordance with 98.3% in Castrillon et al., 90.9% in Crisp et al., 98.1% in Jun et al. and 86.6% in Fukunaga M. study (8;16-19).

Immunoreactivity of extravillous trophoblast at the implantation site in the CHMs has varied among different authors. It seems immunoreactivity in cytotrophoblast covering the villous stroma is more valuable than other cells. Merchant et al. reported immunoreactivity for extravillous trophoblast and decidual cells in all of 68 his patients but Chilosi et al. demonstrated complete negativity for p57^{kip2} in the extravillous trophoblast. In our study, however, extravillous trophoblast in CHMs showed a variable expression and the same result has been observed by Castrillon et al. (8-9, 20).

Immunoreactivity for P57^{kip2} in cytotrophoblasts in HA and PHM was 85% and 95% in our study, 80% and 95% in Fukunaga M. study respectively and also in all cases of Jun et al. study(17;18).

In our study although all (100%) normal placental tissue had nuclear immunoreactivity in cytotrophoblasts for P57^{kip2} but five (25%) of them were weakly positive. Weakly positive immunoreactivity for P57^{kip2} in cytotrophoblasts of normal tissue, HA, PHM and CHM was reported in 3/10(30%), 3/20(6.66), 0(0%) and 7/44(15.9%) respectively in Fukunaga M. study (19). Syncytiotrophoblast was negative in all cases of our study and also in other similar previous article (9; 15; 20).

There are some new techniques including in situ hybridization, polymerase chain reaction, DNA microsatellite polymorphisms and DNA flowcytometry that use of DNA content for discrimination between CHM and PHM (21-24). However, these techniques are technically difficult and relatively expensive, and unlikely to become routine in all laboratories. In addition, ploidy analysis does not differentiate between CHM and HA. IHC is a rapid, technically easy, and cost-effective method and can be useful adjuncts to morphological diagnosis in molar disease. Immunomarkers of cell proliferation, such as PCNA and Ki67, have been examined and have been reported to be of little practical use in differentiating between HA, CM, and PM (25-26). It seems P57^{kip2} can be the most useful immunohistochemical marker for this discrimination.

Therefore P57^{kip2} expression in cytotrophoblast and villous mesenchyme is markedly reduced or absent in CHM compared with strong expression in both PHM and HA may be useful in the cases in which the main differential diagnosis is between CM and PM.

Conclusion: In summary, P57^{kip2} immunostaining results correlated well with morphological features of molar pregnancies. In addition, IHC analysis with P57^{kip2} could provide a useful diagnostic marker in difficult cases.

Acknowledgements

This work was financially supported by the Research council of Mashhad University of Medical Sciences. Authors are thankful of them and also Mrs. Behnaz Barazandeh for her kind assistance that helped us to stain the samples.

References

- Shin IM, Mazur MT, Kurman RJ. Gestational trophoblastic disease. In: Sternberg S: Diagnostic surgical pathology, third ed, Lippincott Williams and Wilkins, 2004;P:2276;2282.
- Sebire NJ, Fisher RA, Rees HC. Histopathological diagnosis of partial and complete hydatidiform mole in the first trimester of pregnancy. *Pediatr Dev Pathol.* 2003;6:69-77.
- Rosai J. Rosai and Ackerman's surgical pathology, 9th ed, Edinburg: Mosby; 2004; P:1741.
- Crum CP. The female genital tract. In: Kumar V, Abbas AK, Fausto N: Robbins and cotran pathologic basis of disease. 7th edi. Pennsylvania: Elsevier Saunders; 2005. P:1110.
- Feltmate CM, Growdon WB, Wolfberg AJ, Goldstein DP, Genest DR, Chinchilla ME, Lieberman ES, Berkowitz RS. Clinical characteristics of persistent gestational trophoblastic neoplasia after partial hydatidiform molar pregnancy. *J Reprod Med.* 2006.;51:902-6.
- Paradinas FJ. The histological diagnosis of hydatidiform moles, *Curr Diagn Pathol* 1994;1;P:24-31.
- Chew SH, Perlman EJ, Williams R, Kurman RJ, Ronnett BM. Morphology and DNA content analysis in the evaluation of first trimester placentas for partial hydatidiform mole (PHM). *Hum Pathol.* 2000;31:914-24.
- Castrillon DH, Sun D, Weremowicz S, Fisher RA, Crum CP, Genest DR: Discrimination of complete hydatidiform mole from its mimics by immunohistochemistry of the paternally imprinted gene product P57^{kip2}. *Am J Surg Pathol.* 2001; 25:1225.
- Merchant SH, Amin MB, Viswanatha DS, Malhotra RK, Moehlenkamp C, Joste NE. P57^{kip2} immunohistochemistry in early molar pregnancies: emphasis on its complementary role in the differential diagnosis of hydropic abortuses. *Hum Pathol.* 2005;36:180-6.
- Jacobs PA, Wilson CM, Sprenkle JA, Rosenshein NB, Migeon BR. Mechanism of origin of complete hydatidiform moles, *Nature.* 1980; 14; 286:714-6.
- Azari S, Majd A, Mahmoodi M. Incidence of Molar pregnancy in a university hospital in Tehran: Age and birth order. *Medical journal of the Islamic republic of Iran.* 1992;3: 191-189.
- Sadeghian MH, Katebi M, Ayatollahi H, Keramati MR. Immunohistochemical study association between human herpesvirus 8 and multiple myeloma. *Int J Hematol.* 2008;88: 283-6.
- Cheung AN. Pathology of gestational trophoblastic diseases. *Best Pract Res Clin Obstet Gynaecol.* 2003;17:849-68.
- Berkowitz RS, Goldstein DP. Current management of gestational trophoblastic diseases. *Gynecol Oncol.* 2008 Oct 11. [Epub ahead of print]
- Messerli ML, Parmley T, Woodruff JD, Lilienfeld AM, Bevilacqua L, Rosenshein NB. Inter- and intra-pathologist variability in the diagnosis of gestational trophoblastic neoplasia. *Obstet Gynecol.* 1987;69:622-6.
- Crisp H, Burton JL, Stewart R, Wells M. Refining the diagnosis of hydatidiform mole: image ploidy analysis and P57^{kip2} immunohistochemistry. *Histopathology.* 2003;43:363-73.
- Jun SY, Ro JY, Kim KR. P57^{kip2} is useful in the classification and differential diagnosis of complete and partial hydatidiform moles. *Histopathology.* 2003;43:17-25.
- Fukunaga M. Immunohistochemical characterization of P57^{kip2} expression in tetraploid hydropic placentas. *Arch Pathol Lab Med.* 2004; 128:897-900.
- Fukunaga M. Immunohistochemical characterization of P57^{kip2} expression in early hydatidiform moles. *Human Pathology,* 2002;33.P1188-1192.
- Chilosi M, Piazzola E, Lestani M, Benedetti A, Guasparri I, Granchelli G, Aldovini D, Leonardi E, Pizzolo G, Doglioni C, Menestrina F, Mariuzzi GM. Differential expression of P57^{kip2}, a maternally imprinted cdk inhibitor, in normal human placenta and gestational trophoblastic disease. *Lab Invest.* 1998;78:269-76.
- Lai CY, Chan KY, Khoo US, Ngan HY, Xue WC, Chiu PM, Tsao SW, Cheung AN. Analysis of gestational trophoblastic disease by genotyping and chromosome in situ hybridization. *Mod Pathol.* 2004;17:40-8.
- Fisher RA, Newlands ES. Rapid diagnosis and classification of hydatidiform moles using the polymerase chain reaction. *Am J Obstet Gynecol* 1993; 168:563-569.
- Popiolek DA, Yee H, Mittal K, Chiriboga L, Prinz MK, Caragine TA, Budimilija ZM. Multiplex short tandem repeat DNA analysis confirms the accuracy of p57(KIP2) immunostaining in the diagnosis of complete hydatidiform mole. *Hum Pathol.* 2006;37:1426-34.
- Paradinas FJ, Browne P, Fisher RA, Foskett M, Bagshawe KD, Newlands E. A clinical, histopathological and flow cytometric study of 149 complete moles, 146 partial moles and 107 non-molar hydropic abortions. *Histopathology.* 1996;28:101-10.
- Cheung AN, Ngan HY, Chen WZ, Loke SL, Collins RJ. The significance of proliferating cell nuclear antigen in human trophoblastic disease: an immunohistochemical study. *Histopathology.* 1993;22:565-8.
- Suresh UR, Hale RJ, Fox H, Buckley CH. Use of proliferation cell nuclear antigen immunoreactivity for distinguishing hydropic abortions from partial hydatidiform moles. *J Clin Pathol.* 1993;46:48-50.