

# Complicated Vesico-Urethrovaginal Fistula

Evrım ERDEMOĞLU<sup>1</sup>, Ekrem ÖZMAN<sup>2</sup>

<sup>1</sup>Department of Obstetrics and Gynecology, Faculty of Medicine, Yüzüncü Yıl University, Van, Turkey

<sup>2</sup>Department of Urology, Faculty of Medicine, Yüzüncü Yıl University, Van, Turkey

Received 15 January 2008; received in revised form 07 February 2008; accepted 20 July 2008;  
published online 18 November 2008

## Abstract

We report a case of complicated urethrovaginal fistula of 15 years. A 50 year old woman presented with continuous urine leakage after her last delivery 15 years previously and carried out at home. She had a small and contracted bladder with a urethrovaginal fistula. We developed a vaginal flap which was constructed as a tube to make a new urethra. The new urethra from vaginal tube was anastomosed to the repaired bladder base and the external urethral meatus. The reconstruction was supported by Martius flap. Simple anatomic repair of complicated fistulas are not promising and should be avoided. Vaginal flaps and labial flaps are useful for reconstructing urethra and bladder base.

**Keywords:** complicated fistula, vaginal flap, martius flap, reconstruction

## Özet

### Komplike Veziko-Üretravajinal Fistül

On beş yıldır bulunan veziko-üretravajinal fistül olgusu takdim edilmiştir. Elli yaşında kadın hasta on beş yıl önce evde doğumdan sonra gelişmiş sürekli idrar kaçağı ile kliniğimize başvurdu. Küçük kontrakte bir mesane ve üretravajinal fistül olan hastaya vajinal fleple yeni üretra yapıldı. Oluşturulan yeni üretra mesane tabanına ve eksternal meatusa anastomoz edildi. Onarım martius flepiyle desteklendi. Komplike üriner sistem fistüllerinin basit onarımı iyi sonuçlar vermemektedir ve bunlardan kaçınmak gerekir. Üretra ve mesane tabanı rekonstrüksiyonunda vajinal ve labial flepler faydalı uygulanabilir yöntemlerdendir.

**Anahtar sözcükler:** komplike fistül, vajinal flep, martius flep, rekonstrüksiyon

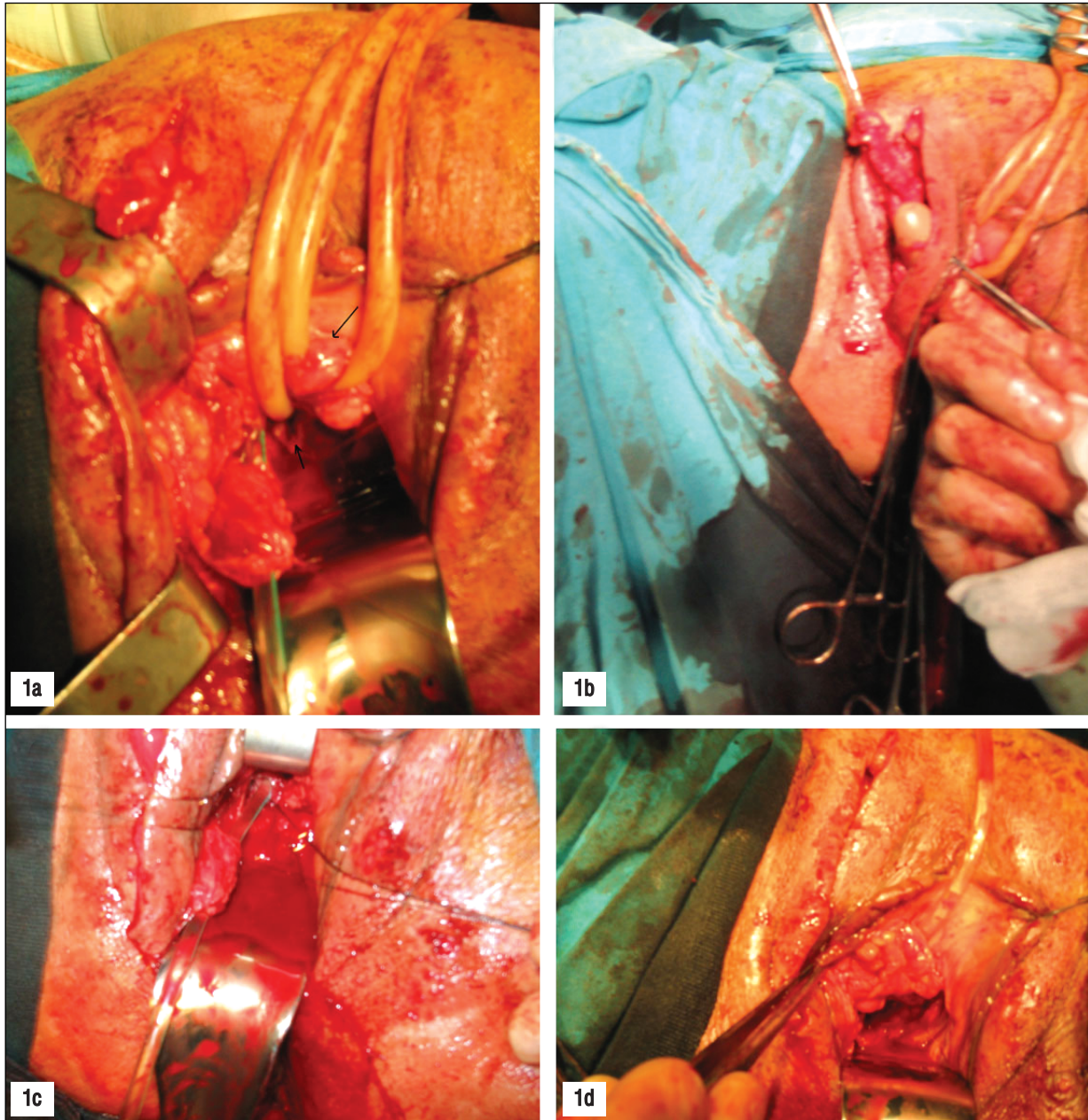
## Introduction

Management of urethrovaginal fistulas and complicated vesicovaginal fistulas represents a great challenge. Urethrovaginal fistulas (UVF) and complicated vesicovaginal fistulas are rarely encountered in developed countries. Fistulas greater than 3 cm, fistulas associated with radiotherapy or malignancy, fistulas that involve the trigone, bladder neck and urethra are complicated fistulas (1). Simple anatomic repair of these fistulas are not promising and should be avoided. We present a case of large urethrovaginal fistula that has been for 15 years that is reconstructed by excision of fistula repaired by lateral vaginal wall flap and reinforced with Martius flap.

## Case Report

A 50 years old woman, gravid 5, para 4 was admitted by complaints of continuous urine leakage. Her births took place at home which then she had urinary leakage. On physical examination, she had a fistula involving bladder neck and almost all of the urethra, with a few millimeters of external urethral meatus left. Laboratory examination was unremarkable. Intravenous pyelography revealed a very small, contracted bladder and the fistula. Upper urinary system involving ureters were normal. The patient was undertaken to surgical correction under general anesthesia. A Foley catheter was introduced to the defect in the base of bladder and the balloon was filled with 15 ml of serum physiologic. Another catheter was passed through the left external meatus (Figure 1a). A vaginal flap with vascular pedicle was prepared at the right side and the fistula tract was incised with curved lancet. Bladder base was repaired with interrupted sutures. Incision over the right labium majus for preparation of Martius flap was made and the tunnel was prepared from subcutaneous tissue to the vagina (Figure 1b). Tunneling was performed cautiously in order to protect the

**Corresponding Author:** Dr. Evrim Erdemoğlu  
Süleyman Demirel Üniversitesi Tıp Fakültesi,  
Kadın Hastalıkları ve Doğum AD, Çünür 32260 Isparta, Türkiye  
**Phone** : +90 212 272 43 44; +90 246 211 21 44  
**GSM** : +90 505 272 43 44  
**E-mail** : evrimmd@yahoo.com



**Figure 1.** a) Arrows shows the remaining urethra (mainly of external urethral meatus) and the defect in the base of bladder. A tube of the vaginal wall is prepared from a vaginal wall flap with vascular supply. b) Incision over left labium majus is made for preparation of Martius flap, latter in the operation. c) Anastomosis of tubular vaginal flap. d) Martius flap over the anastomosis at the end of operation.

vascular supply of vaginal flap. A catheter was used to make a tube of vaginal flap (Figure 1a). Catheter in the vaginal flap was proceeded into the base of bladder. Anastomosis of the bladder base, vaginal flap and the external meatus was performed by 6 polyglactin sutures (Figure 1c). Previously prepared Martius flap was turned over the anastomosis (Figure 1d). The catheter was left in place for 1 month. Postoperative course was uneventful. The patient was lost to follow up.

### Discussion

Although urethrovaginal fistulas are rare in developed countries, they are the frequent complications of obstetric

trauma in developing countries. They can also occur after the operations that involve the urethra and vagina such as urethral diverticulectomy or anterior vaginal repair, pelvic fractures, vaginal or urethral malignancies (especially after radiotherapy), and radical operations such as Wertheim operation (1).

The conventional approach to the repair of urethrovaginal fistulas is transvaginally, and a Martius labial fat pad graft is frequently used to buttress the repair (2,3). When the defect is large, alternative treatment modalities are limited. McKinney used a full-thickness free graft of labium minus to successfully treat a large urethrovaginal fistula that could not

be bridged otherwise (4). The role of buccal mucosa autografts is limited to urethral reconstruction and the possibility of using that in UVF management is not evident yet (5). It is reported that complex urethrovaginal fistulas can be repaired by pedicled rectus abdominis muscle flap (6).

Fistulas inaccessible from the vagina may require abdominal repair. Laparoscopic treatment of vesicovaginal fistulas is another modality which is feasible, efficacious and minimal invasive (7). Recently, robotic-assisted laparoscopic approach is reported to be a viable option for successful repair of a vesicovaginal fistula (8). However, robotic surgery is a new entity and long term follow up results are not available for robotic surgery (9).

Reports of results of repair urethrovaginal fistula are limited in the literature. Blaivas reviewed the results in 24 women with bladder-neck and urethral defects with a 79% success rate after primary surgery (10). Lee similarly reported a 92% correction rate of UVF after one surgery and 100% success after secondary surgery (11). Goodwin and Scardino reported a 70% success rate following one operation in patients and 92% following second operation (1).

Every fistula is unique and requires an individualized approach; it is difficult to describe a standard fistula repair. However, key to successful repair in any technique is tension-free and delicate surgical technique. The authors believe continence procedures might be evaluated and planned after correction of the complex fistulas; although there is not an evidence of decreased success and increased

complication when interposition graft is combined with other surgical procedures. Large defects involving the bladder base can be repaired by the technique we described above. Martius flap over the anastomosis reinforces the anastomosis and may contribute to the continence of the patient (12).

## References

1. Goodwin WE, Scardino PT. Vesicovaginal and ureterovaginal fistula: a summary of 25 years of experience. *J Urol* 1980;123:370-4.
2. Davis RS, Linke CA, Kraemer GK. Use of labial tissue in repair of urethrovaginal fistula and injury. *Arch Surg* 1980;115:628-30.
3. Leach GE. Urethrovaginal fistula repair with Martius labial fat pad graft. *Urol Clin North Am* 1991;18:409-13.
4. Gerstenbluth RE, Goldman HB. Simultaneous urethral erosion of tension-free vaginal tape and woven polyester pubovaginal sling. *J Urol* 2003;170:525-6.
5. Berglund RK, Vasavada S, Angermeier K, Rackley R. Buccal mucosa graft urethroplasty for recurrent stricture of female urethra. *Urology* 2006;67:1069-71.
6. Bruce RG, El-Galley RE, Galloway NT. Use of rectus abdominis muscle flap for the treatment of complex and refractory urethrovaginal fistulas. *J Urol* 2000;163:1212-5.
7. Sotelo R, Mariano MB, García-Segui A et al. Laparoscopic repair of vesicovaginal fistula. *J Urol* 2005;173(5):1615-8.
8. Schimpf MO, Morgenstern JH, Tulikangas PK, Wagner JR. Vesicovaginal fistula repair without intentional cystotomy using the laparoscopic robotic approach: a case report. *JSLs*. 2007;11(3):378-80.
9. Melamud O, Eichel L, Turbow B, Shanberg A. Laparoscopic vesicovaginal fistula repair with robotic reconstruction. *Urology* 2005;65(1):163-6.
10. Blaivas JG. Treatment of female incontinence secondary to urethral damage or loss. *Urol Clin North Am* 1991;18:355-63.
11. Lee RA. Current status of genitourinary fistula. *Obstet Gynecol* 1988; 72:313-9.
12. Baskin D, Tatlıdede S, Karsıdag SH. Martius repair in urethrovaginal defects. *J Pediatr Surg* 2005;40:1489-91.



www.journalagent.com

Online manuscript  
submissions  
and peer review  
(JournalAgent)

Available at  
J Turkish German Gynecol Assoc  
www.jtgga.org