

Antenatal Diagnosis of Iniencephaly: Contribution of Real Time 3-D Ultrasound

Talat Umut Kutlu **DİLEK**, Filiz **ÇAYAN**, Arzu **DORUK**, Saffet **DİLEK**

Department of Obstetrics and Gynecology, School of Medicine, Mersin University, Mersin, Turkey

**Received 09 June 2008; received in revised form 16 August 2008; accepted 17 August 2008;
published online 18 November 2008**

Abstract

Iniencephaly is the rarest form of neural closure defects. It is characterized by incomplete closure of vertebral arches and/or bodies; significant shortening of the spinal column, rotation and retroflexion of head. It can be detected at the end of the first trimester by careful ultrasonographic examination of the fetus. Although, the diagnostic merit of the real time 3 dimensional (3-D) ultrasonography is unclear, it could be utilized by for differential diagnosis to eliminate other neural tube defects and Klippel-Feil Syndrome. In this manuscript, we report two cases of iniencephaly diagnosed at late first and early second trimester with the contribution of the real time 3-D scan.

Keywords: iniencephaly, craniorachischisis, prenatal diagnosis, real time 3-D scan

Özet

İniensefalinin Antenatal Tanısı: Gerçek Zamanlı 3 Boyutlu Ultrasonografinin Katkısı

İniensefali nöral tüp kapanma defektlerinin en nadir izlenen şeklidir. Vertebral ark ve gövdenin tam olmayan kapanması sonucunda, spinal kolonda ciddi derecede kısalma, rotasyon ve başın retrofleksiyonu ile karakterizedir. Fetüsün dikkatli değerlendirilmesi ile iniensefali olguları ilk trimesterin sonlarında saptanabilir. Tanıda gerçek zamanlı (real-time) 3-D ultrasonografinin rolü açık olmamakla beraber, diğer nöral tüp defektlerinin ve Klippel Feil Sendromu'nun ayırıcı tanısında yararlanılabilir. Bu yazıda geç birinci, erken ikinci trimesterde gerçek zamanlı 3-D ultrasonografinin de katkısı ile tanı alan 2 iniensefali olgusunu sunduk.

Anahtar sözcükler: iniensefali, kraniyörakizis, prenatal tanı, gerçek zamanlı 3-D tarama

Introduction

Iniencephaly is a rare neural closure defect involving the occiput and inion combined with rachischisis of the cervical and thoracic spine and retroflexion of the head. It is the rarest form of the neural closure defects and almost invariably fatal (1). Ultrasound has been applicable to early second trimester diagnosis of iniencephaly. Newer ultrasound techniques, such as real time 3-D ultrasound give better definition of fusion defects and the external surfaces of the cranial, cervical and upper thoracic regions. In this article we reported two cases of iniencephaly diagnosed at early second trimester by conventional and real time 3-D ultrasound scanning.

Case 1

A 25 year old primigravid woman was referred to our hospital for an abnormal ultrasound scan at 16 weeks' of gestation. She had no any consanguine relationship with her husband. There was no history of teratogen exposure or folic acid deficiency. Ultrasonographic examination was performed by Philips HD 11 using a broad band 2-5 MHz convex transducer and 4-8 MHz convex volume transducer. Conventional gray scale scan revealed hyperextension and lateral deviation of the head (Figure 1), cervical and thoracic spine vertebral fusion defect. Retroflexion and the lateral deviation of the head was seen by the real time three dimensional examination (Stargaze) (Figure 2). Following amniocentesis, pregnancy was terminated by prostaglandin E2 vaginal insert at 17 weeks of gestation. On the post-mortem examination, occipital bone defect, retroflexion of the head, cervical-upper thoracic and lumbar fusion defect (Figure 3a), low set ears and bilateral clubfoot (Figure 3b) were observed. Fetal karyotype was determined to be 46 XX.

Corresponding Author: Dr. Talat Umut Kutlu Dilek
Çamtepe Sitesi 28, Kuyuluk 33450 Mersin, Türkiye
Phone : +90 533 384 42 64
E-mail : umutdilek@gmail.com

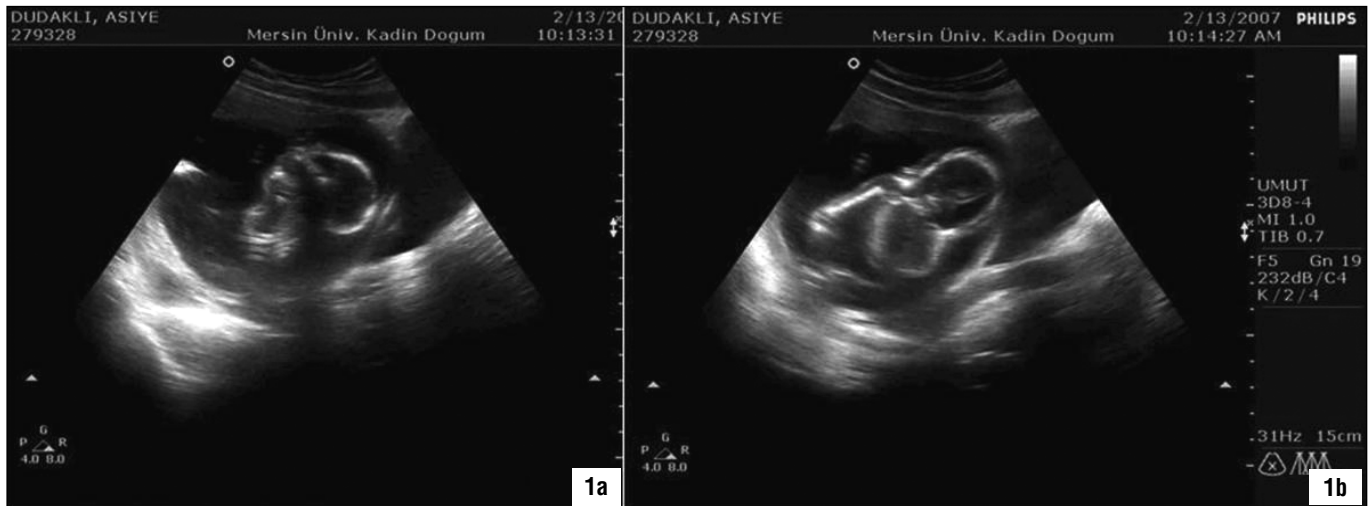


Figure 1. Ultrasound image at 16th weeks' gestation with retroflexed head and microcephaly (Figure 1a) and lateral deviation (Figure 1b).

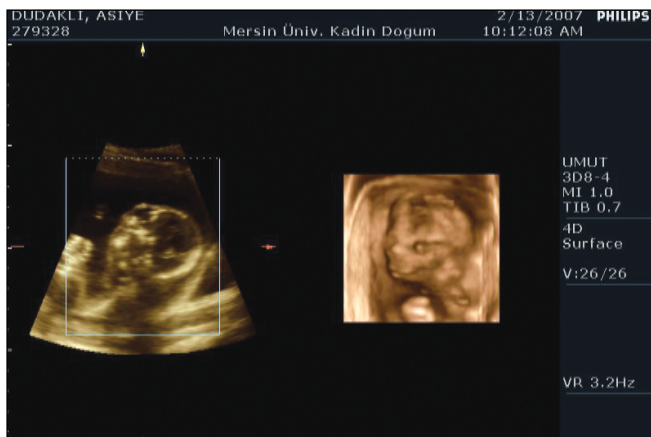

Figure 2. Typical stargaze posture with retroflexed head in surface rendering mode.

obstetrics history did not include any risk factors like teratogene exposure and history of adverse pregnancy outcome. Also, folic acid supplementation had been prescribed at the first visit. Ultrasonographic examination revealed a CRL (Crown-Rump Length) 70 mm fetus which had occipital bone defect and retroflexed head. Also ventriculomegaly was seen. These findings were confirmed by real time 3-dimensional ultrasound (Figure 4). After chorion villus sampling, pregnancy was terminated by oral and vaginal misoprostol tablets (Searle, USA). Thoracolumbal meningocele, occipital bone defect retroflexion of head were observed during the autopsy. Fetal karyotype was 46 XX.

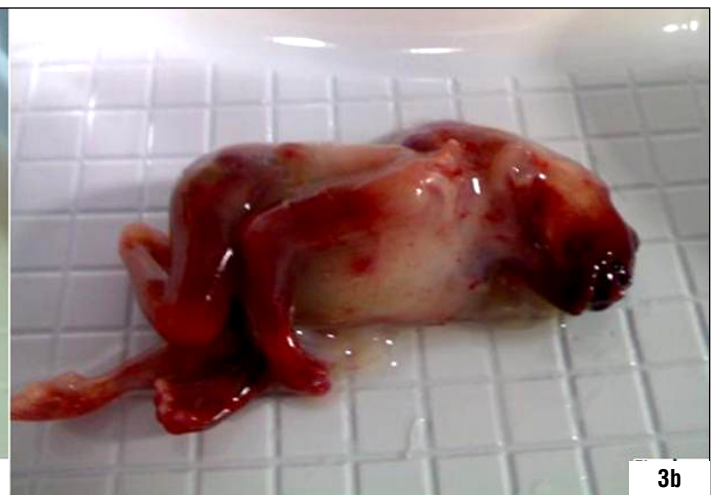
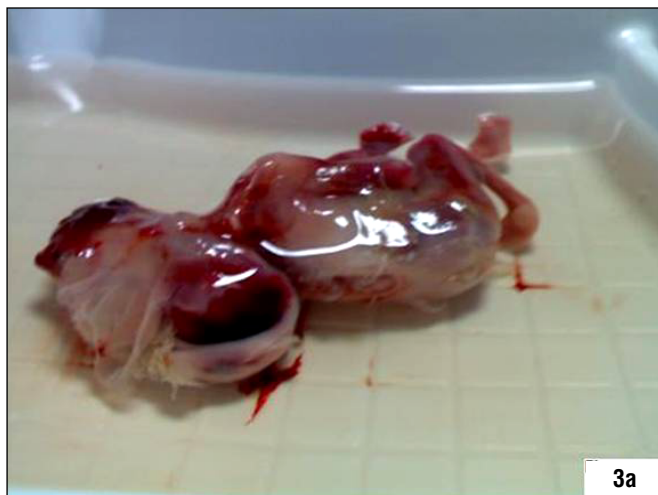
Figure 3. External appearance of fetus, dorsolateral view, showing retroflexed head with thoracal and lumbal fusion defect (3a). On ventrolateral view, low set ears and bilateral clubfoot were seen (3b).

Case 2

A 42 years old, multigravida (gravida 3, para 2) was admitted for routine antenatal visit at 13 weeks of gestation. She had no consanguine relationship with her husband. Her

Discussion

Iniencephaly is the rarest among the neural tube defects. Overall incidence and the developmental pathogenesis is

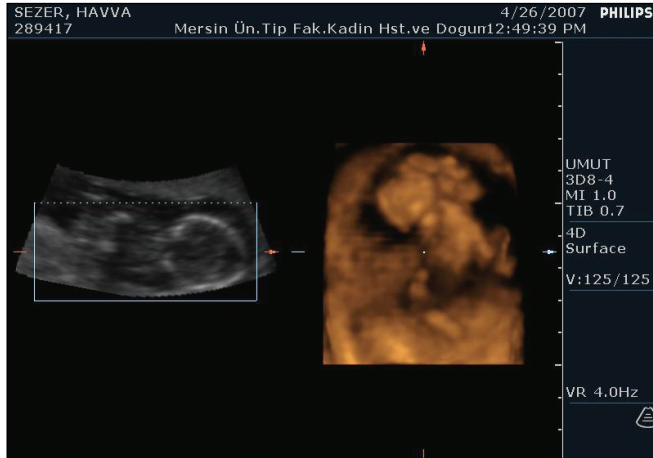


Figure 4. Case 2. Real time 3-D scan shows typical body posture with retroflexed head.


not known. It has been described as a consequence of congenital syphilis and has been induced in animal models given teratogenic compounds such as triparanol, streptonigrin (2). However, most cases are sporadic and probably secondary to polygenic inheritance (3). Females are nine times more affected than males. Main pathologic features of iniencephaly are occipital bone defect and vertebral fusion defects which causes enlarged foramen magnum, shortened neck, and retroflexion and, sometimes lateral deviation of the head. Also several major congenital anomalies including cardiac defects, single umbilical artery, polyhydramnios, and pulmonary hypoplasia, absence of the mandible, cleft palate, low set ears, diaphragmatic hernia, abdominal closure defects, and clubfoot can be detected co-incidentally (4). In Case 1, we detected bilateral clubfoot and lumbar spina bifida. The prognosis is poor: almost all live born cases die within a few hours of birth (5). Iniencephaly has been reported to be associated with trisomy 18, partial monosomy 6p, and partial trisomy 11q (6).

First trimester screening, especially during the nuchal translucency measurement is a good candidate to detect iniencephaly and other complex craniospinal malformations. Anatomic details are better visualized by the new equipments. Early diagnosis of iniencephaly as early as 9 weeks' of gestation is possible by transvaginal ultrasound (7). Although the diagnostic role of the real time 3-D (4-D) ultrasound is not clear, 3-D scan delineates external surface of the fetus and posture anomalies including open neural tube defects, abdominal wall defects, clubfoot, cleft palate, low set ears by surface rendering mode. In both the cases reported here, we showed the retroflexion and lateral deviation of the head at star-gazing position by real time 3-D scan. MR scan has been rarely indicated (8).

Although, fixed retroflexion of the head is highly suggestive of iniencephaly, anencephaly and Klippel-Feil syndrome should be excluded by differential diagnosis (1) which is successfully achievable by the real time 3-D scan as in the cases presented here.

References

1. Sahid S, Sepulveda W, Dezerega V et al. Iniencephaly: prenatal diagnosis and management. *Prenat Diagn* 2000;20:202-5.
2. Romero R, Pihu G, Jeanty P et al. Prenatal diagnosis of congenital anomalies. Appleton and Lange, Norwalk, CT 1988;65-6.
3. Csabay L, Szabo I, Papp C et al. Central nervous system anomalies. *Ann NY Acad Sci* 1998;847:21-45.
4. Tuğrul S, Uludoğan M, Pekin O et al. Iniencephaly: Prenatal diagnosis with post-mortem findings. *J Obstet Gynaecol Res* 2007;33:566-9.
5. Foderaro AE, Abu-Yousef MM, Benda JA et al. Antenatal diagnosis of iniencephaly. *J Clin Ultrasound* 1988;15:550-4.
6. Chen CP. Prenatal diagnosis of iniencephaly. *Taiwan J Obstet Gynecol* 2007;46:199-208.
7. Cullier F, Koenig P, Lagarde L, Cartault JF. Transvaginal sonographic diagnosis of iniencephaly apertus and cranioraschischisis at 9 weeks' gestation (Letters). *Ultrasound Obstet Gynecol* 2003;22:656-8.
8. Pungavkar SA, Sainani NI, Kamik AS et al. Antenatal diagnosis of iniencephaly: Sonographic and MR correlation: A case report. *Korean J Radiol* 2007;8:351-5.



www.journalagent.com

**Online manuscript
submissions
and peer review
(JournalAgent)**

Available at
J Turkish German Gynecol Assoc
www.jtgga.org