

Ultrasound in Trisomy 18 and 13

Ali GEDİKBAŞI, Ahmet GÜL, Akif SARGIN, Taner GÜNAY, Yavuz CEYLAN

*Bakırköy Maternity and Children Diseases Hospital, Department of Obstetrics and Gynecology,
Perinatology Unit, İstanbul, Turkey*

Received 14 August 2007; received in revised form 19 December 2007; accepted 15 February 2008;
published online 28 August 2008

Abstract

Objective: To evaluate the sonographic characteristics of fetuses with trisomy 18 and trisomy 13.

Materials and Methods: From March 2002 to December 2006, we reviewed the database and medical records of 25 cases with trisomy 18 and trisomy 13. The subjects were recruited from pregnant women undergoing prenatal sonographic examinations at 13-28 weeks of gestation and subsequently proven trisomy 18 or 13. The results of ultrasound findings were reviewed in these cases with chromosomes confirmed as trisomy 18 and/or 13.

Results: All cases had at least one abnormal sonographic finding. The common sonographic findings included choroid plexus cysts, abnormal head shape, cardiac anomalies, holoprosencephaly with associated facial anomalies, abnormal feet and/or hands, especially polydactyly, clenched hand, omphalocele. Non-structural abnormal findings such as polyhydramnios or fetal growth restriction were seen in less than one third of the fetuses.

Discussion: Nearly all fetuses with trisomy 18 or 13 had characteristic sonographic patterns of abnormalities demonstrated at midpregnancy. Detailed ultrasound at midpregnancy could effectively screen fetuses with trisomy 18 or 13 for further genetic testing.

Keywords: genetic ultrasound, trisomy 18, trisomy 13

Özet

Trizomi 18 ve 13'te Ultrason

Amaç: Trizomi 18 ve trizomi 13 tanısı almış fetüslerde sonografik bulguları değerlendirmek.

Materyal ve Metot: Mart 2002 ile Aralık 2006 arasında veritabanımızda kayıtlı bulunan 25 trizomi 18 ve trizomi 13 olgusu değerlendirildi. Olgular 13-28. gebelik haftalarında prenatal ultrasonografik muayeneleri yapılmış ve trizomi 18 veya 13 olarak tanı almıştır. Trizomi 18 ve/veya trizomi 13 tanısını almış bu olguların ultrason bulguları değerlendirildi.

Sonuçlar: Tüm olguların en az iki patolojik ultrason görüntüsü vardı. En sık gözlenen bulgular koroid pleksus kisti, patolojik kafa şekli, kardiyak patolojiler, holoprozensefali ile ilişkili yüz anomalileri, anormal el ve ayak şekli, polidaktili ve pençe el idi. Yapısal anatomik bulguların dışında polihidroamnios ve gelişme geriliği gibi sonuçlar da saptandı.

Tartışma: İkinci trimesterde neredeyse trizomi 18 veya 13 olgularının tümünün karakteristik ultrason bulguları vardı. Ayrıntılı ultrason taraması ile 2. trimesterde etkin trizomi 18 veya 13 taraması yapmak olasıdır.

Anahtar sözcükler: genetik ultrason, trizomi 18, trizomi 13

Introduction

Trisomy 18 or Edwards' syndrome, a lethal chromosomal abnormality, after Down syndrome, is the second most common autosomal trisomy and has a reported incidence varying from one in 3000 to 1 in 8000. It was first recognized as a specific entity in 1960 by Edwards et al.

and Jones (1,2). Different severe congenital malformations, intense mental retardation, as well as high rate of infant mortality are typical features of trisomy 18. The condition is incompatible with long-term survival, and the singular cases that do survive have an extremely low quality of life. The mortality *in utero* is high and death in those fetuses which are live born occurs within the first few weeks of life, with a median survival period of <1 month (3). Its sonographic features in the second and third trimesters have been well-described (4). These include strawberry-shaped head, ventriculomegaly, choroid plexus cyst, posterior fossa cyst, facial cleft, micrognathia, nuchal edema, diaphragmatic hernia, heart defects, exomphalos,

Corresponding Author: Dr. Ali Gedikbaşı
Bakırköy Kadın Doğum ve Çocuk Hastalıkları Hastanesi,
İstanbul, Türkiye
GSM : +90 0532 213 51 40
E-mail : alged_1971@yahoo.com

esophageal atresia, renal defects, abnormal extremities, and intrauterine growth restriction. However, in the first trimester, the sonographic abnormalities are less well documented; the features reported include increased nuchal translucency, heart defects, and exomphalos (5,6).

Patau first discovered trisomy 13 in 1960 (7). This syndrome occurs in one of 5000 births, and is the most seen third autosomal anomaly (2). Common characteristic features of the syndrome consist of central nervous system (CNS) anomalies, especially holoprosencephaly, facial and ocular anomalies, polydactyly, clubbed or rocker-bottom feet, heart defects, renal anomalies, and a single umbilical artery. The median survival is 2.5 days (2). Eighty-two percent of newborns with trisomy 13 die in the first month and only 5% survive the first 6 months (2). Survivors have severe mental defects, often have seizures, and they fail to thrive. Because the prognosis of the syndrome is very poor, early prenatal diagnosis is important. In the past, prenatal diagnosis by amniocentesis was performed only because of maternal age. In the last decade, ultrasonography has been increasingly used for prenatal diagnosis. The prenatal sonographic characteristics of trisomy 13 have been published, but most studies included fetuses at all stages of pregnancy.

Advances in ultrasound prenatal diagnostics have significantly improved the option of early detection of congenital anomalies, leading to improvement of perinatal care and giving the opportunity for pregnancy termination in the cases of lethal disorders (7-9). Accurate and actual knowledge of survival rate, disease course, and methods of treatment is therefore very important for clinicians and family members who take care of children and fetuses with trisomy 18, in making correct but also ethically very difficult decisions. In this article, we describe our ultrasound experience from the last 5 years in managing fetuses with Edwards and Patau syndrome. The objective of this study was to evaluate the efficacy of sonographic screening for trisomy 18 and 13 at midpregnancy.

Materials and Methods

This descriptive analysis was undertaken at İstanbul Bakırköy Maternity and Children Diseases Hospital, Department of Obstetrics and Gynecology, Perinatology Unit. Women with abnormal ultrasonographic findings or an abnormal triple test were offered genetic ultrasonography and a chromosomal study. The subjects were recruited from pregnant women who underwent prenatal sonographic examinations with various indications at midpregnancy (13-28 weeks of gestation). The inclusion criteria were fetuses' proven trisomy 18 by amniocentesis, chordocentesis, or chorion villus biopsy with abnormal ultrasound scan. The gestational age was estimated by either last menstrual period, crown-rump length in first trimester or biparietal diameter with femur length in second trimester. Ultrasonographic examinations were performed

transabdominally from March 2002 to November 2006 by one of four experienced maternal-fetal medicine physician sonographers using Sonoline-G50 TM, Siemens, Issaquah, WA, USA and Voluson 730 Expert TM, GE Healthcare, Milwaukee, WI, USA; multifrequency convex transducer 2.0-7.0 MHz.

All ultrasound findings were prospectively identified at the time of first scanning before knowledge of cytogenetic diagnosis. Reason for referral to our ultrasound unit were small-for dates uterus (n=1), positive screening test (n=2), suspected or unexplained abnormal structural findings by ultrasound (n=22).

Ultrasonographic imaging included standard biometry measurements of BPD (biparietal diameter), HC (head circumference), AC (abdominal circumference), and FL (femur length) as well as fetal anatomic evaluation of the cerebral ventricles, posterior fossa, spine, four-chamber view of the heart, stomach, kidneys, and bladder in accordance with ACOG and AIUM criteria (11,12). In addition to these anatomic structures, we attempted to evaluate the following structures in the second trimester scan in all cases; nuchal skin fold area, cerebellum, right and left ventricular outflow tracts, renal pelvis, and extremities. Color flow imaging of the fetal heart was used when a heart defect was suspected on the basis of the four-chamber view and imaging of the outflow tracts. Intrauterine growth retardation (IUGR) was defined as a difference of at least 14 days between the mean gestational age by ultrasonography and last menstrual period (LMP) dating. In cases of omphalocele, the mean gestational age was calculated from the BPD and FL, and in cases of intracranial abnormalities, it was calculated from the AC and FL.

All 25 cases were confirmed as having trisomy 18 or trisomy 13 by genetic study – amniocentesis (18), chordocentesis (4), chorionic villus sampling (2) and one cardiocentesis.

The hospital ethics committee made the decision for termination of pregnancy (TOP), after counseling and approval of the parents. Autopsy was offered to all patients after termination of pregnancy.

Results

A computerized search identified 21 trisomy 18 fetuses and 4 trisomy 13 fetuses from 13-28 weeks' gestation that had comprehensive ultrasound scans and multiple-marker screening tests before genetic karyotyping from 2002-2006.

The mean maternal age for trisomy 18 groups was 31 (18-42) years. Fourteen of them were under 35 years of age. Sixteen women (76.2%) were multiparous, and 5 (23.8%) were nulliparous. Comprehensive ultrasound examinations were abnormal in 21 of 21 (100%) fetuses. Mean gestational age when abnormalities were detected was 19 (13-24) weeks.

Table 1. Sonographic abnormalities in 21 fetuses with trisomy 18 and 4 fetuses with trisomy 13

Abnormality	Trisomy 18; n (%)	Trisomy 13; n (%)
Cranium/Brain	In 14/21 (66.6%) of cases	In 4/4 (100%) of cases
- Choroid plexus cysts	9 (42.8)	-
- Strawberry-shaped cranium	8 (38.1)	-
- Vermis hypoplasia/agenesis	4 (19.0)	2 (50.0)
- Ventriculomegaly	3 (14.3)	-
- Holoprosencephaly	1 (4.8)	2 (50.0)
- Dandy-Walker malformation	1 (4.8)	1 (25.0)
- Corpus callosum agenesis	1 (4.8)	-
- Enlarged cisterna magna	-	1 (25.0)
Face/Neck	In 6/21 (28.6%) of cases	In 4/4 (100%) of cases
- Cystic hygroma	4 (19.0)	-
- Facial cleft	2 (9.5)	2 (50.0)
- Micrognathia	2 (9.5)	-
- Cyclopes	-	1 (25.0)
- Nuchal edema	-	1 (25.0)
Cardiac	In 15/21 (71.4%) of cases	In 2/4 (50%) of cases
- Ventricular septal defect (VSD)	9 (42.8)	1 (25.0)
- Atrioventricular septal defect (AVSD)	4 (19.0)	1 (25.0)
- Tetralogy of Fallot (TOF)	3 (14.3)	-
- Double outlet right ventricle (DORV)	2 (9.5)	-
- Pulmonary stenosis	2 (9.5)	-
- Single AV valve	3 (14.3)	-
- Hypoplastic left ventricle and arcus aorta	1 (4.8)	-
Thorax/Abdomen	In 7/21 (33.3%) of cases	In none cases
- Hydronephrosis	2 (9.5)	-
- Omphalocele	1 (4.8)	-
- Absent stomach	1 (4.8)	-
- Diaphragmatic hernia	1 (4.8)	-
- Hydrothorax	2 (9.5)	-
- Ascites	1 (4.8)	-
Others		
- Abnormal hands/feet	7 (33.3)	-
- Single umbilical artery	4 (19.0)	1 (25.0)
- Polyhydramnios	2 (9.5)	-
- Fetal growth restriction	2 (9.5)	1 (25.0)
- Umbilical cord cyst	1 (4.8)	-

Mean gestational age when pregnancy was terminated was 23.57 (16-32) weeks. The mean maternal age for trisomy 13 groups was 25 (21-32) years. All of them were under 35 years of age. Ultrasound examination was abnormal in all four cases (100%). Mean gestational age at diagnosis was 22.25 (16-28) an at termination of pregnancy 24 weeks (18-30 weeks).

All of the cases were sonographically evaluated before karyotyping. Therapeutic termination was done in all cases after proper counseling. All cases had at least two abnormal sonographic finding. The most common findings in trisomy 18 were choroid plexus cysts, strawberry shaped head, ventricular septal defects and abnormalities of extremities. The most common findings in trisomy 13 cases were vermis hypoplasia, holoprosencephaly, and facial cleft.

The sonographic findings and appropriate illustrations are seen in Table 1, Figure 1 and 2 for trisomy 18 and 13 cases.

Discussion

Trisomy 18 (Edwards syndrome) is a chromosomal abnormality that results from the presence of an extra copy of chromosome 18. The etiologies of the trisomy of 18 are known as maternal meiotic nondisjunction (over 90%), paternal meiotic nondisjunction (5%), and paternal dislocation. Trisomy 18 is a lethal chromosomal abnormality leading to fetal or neonatal death. Edwards first described the clinical features of the abnormality in 1960. Every organ system can be affected by trisomy 18. Fetuses are usually growth-restricted and have facial abnormalities, including microcephaly, prominent occiput, low-set ears, micrognathia, and a small mouth. They also have skeletal anomalies,

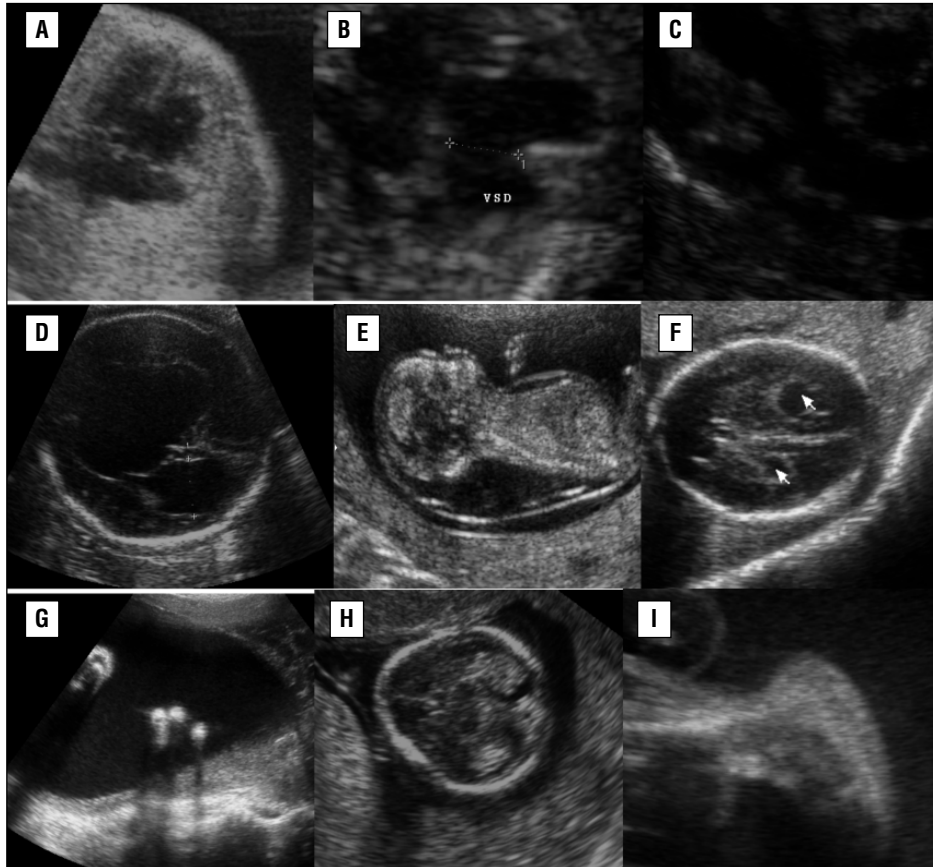


Figure 1. Different features in cases with trisomy 18. **A.** Atrioventricular septal defect; **B.** Ventricular septal defect; **C.** Double outlet right ventricle; **D.** Ventriculomegaly with porencephalic cyst; **E.** Septated cystic hygroma; **F.** Bilateral choroid plexus cyst; **G.** Oligodactyly; **H.** Strawberry-shaped cranium; **I.** Rockerbottom foot.

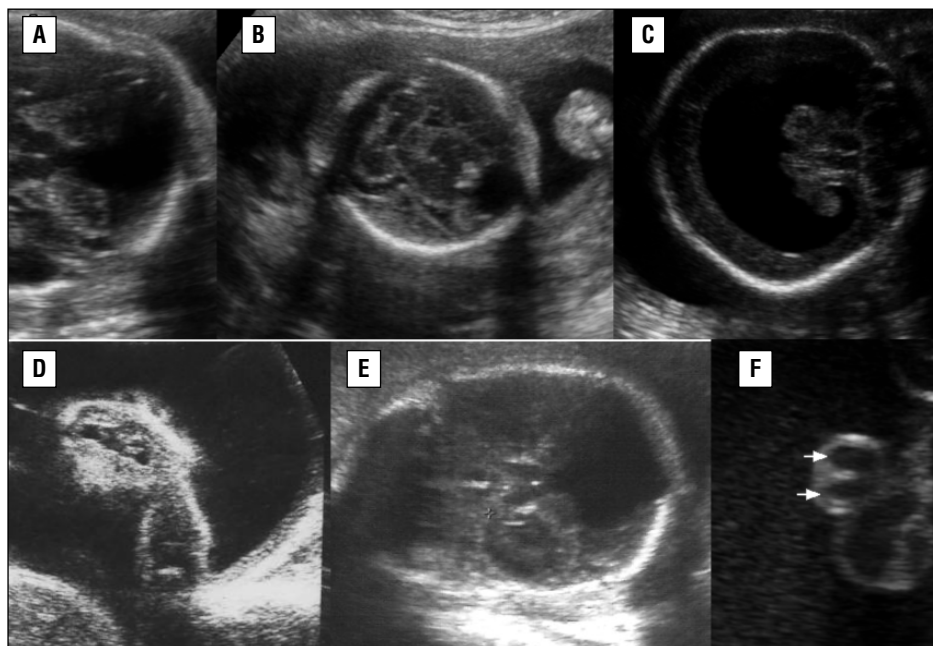


Figure 2. Ultrasound feature in cases with trisomy 13. **A.** Vermis agenesis; **B.** Semilobar holoprosencephaly; **C.** Alobar holoprosencephaly; **D.** Cleft lip; **E.** Dandy-Walker malformation; **F.** Single umbilical artery.

including overlapping fingers, syndactyly and rocker-bottom feet. Cardiac and renal anomalies are common (2).

Trisomy 13 has its own characteristic pattern of sonographic abnormalities, which may overlap with the patterns of other syndromes. Common sonographic features of trisomy 13 include holoprosencephaly, facial clefts, cardiac defects, intrauterine growth restriction, microcephaly, neural tube defects, omphalocele, polycystic kidneys, and polydactyly. Intracranial anomalies include abnormal posterior fossa, agenesis of the corpus callosum, and ventriculomegaly. In particular, alobar holoprosencephaly is a common finding that is invariably associated with severe midline facial defects, including hypotelorism, cyclopia, midline clefts, microphthalmia, proboscis, and the absence of the nose (13, 14). According to the largest study (13), major abnormalities seen sonographically in fetuses with trisomy 13 include holoprosencephaly, facial anomalies, renal anomalies, cardiac defects, intrauterine growth restriction, echogenic intracardiac foci, mild ventriculomegaly, abnormal cisterna magna, cystic hygroma and abnormalities of the extremities, including polydactyly and radial aplasia. Holoprosencephaly with facial defects is the most sensitive marker. Although cleft lips could be seen in approximately 60-80% of cases (2). Some other signs, such as nuchal edema, echogenic bowel, and hydronephrosis, which are commonly related to trisomy 21 in the second trimester, and in some cases, to trisomy 13, were rarely present at midpregnancy. Although this is a small series, it suggests that fetuses with trisomy 13 have their own sonographic patterns, which can overlap with those of other syndromes. It also suggests that detailed ultrasonography at midpregnancy could screen effectively for the need of further genetic testing.

Most studies upon the screening for chromosomal anomalies prenatally have been performed for Down syndrome. According to some studies, using the scoring indices based on ultrasonographic findings has detected 81% of Down syndrome cases with a 4.4% false positive rate (15-17). The three biochemical values (α -fetoprotein, unconjugated estriol, and human chorionic gonadotrophin) and maternal age are combined to determine Down syndrome risk and have a significantly high sensitivity of 69% to detect Down syndrome at age less than 35 years (18). In contrast, screening strategies for trisomy 18 are not fully developed, because of its lower incidence and its lethality. In pregnancies of trisomy 18, the three-biochemical markers values mentioned above are generally lower than normal (19-21). Concentrations of analytes are expressed as multiples of the median (MoM) for unaffected pregnancies. Using the abnormal three biochemical values (α -fetoprotein 0.75 MoM, unconjugated estriol 0.55 MoM and human chorionic gonadotrophin 0.60 MoM), it is generally accepted that 60% of trisomy 18 fetuses can be identified with a false positive rate of 0.4% (21). However, in the present study, of the 21 cases of trisomy 18, only 4 (17%) had all three

markers at low levels. The use of ultrasound to examine fetuses in the first and second trimester has resulted in the identification of certain sonographic markers as being associated with fetal aneuploidy (4,22,23). Over the past several years, the ultrasound abnormalities in the mid-trimester fetuses has shown a higher positive predictive rate for the detection of aneuploidy fetuses than did advanced maternal age and/or abnormal triple serum markers (16,24). A retrospective study of comparing the detection of trisomy 18 in the second trimester (13-24 weeks' gestation) by ultrasound and multiple biochemical marker test [α -fetoprotein (AFP), human chorionic gonadotrophin (hCG), unconjugated estriol (E3)] has shown that ultrasound was more likely to be abnormal (70%) than multiple-marker screening tests (43%) in fetuses with trisomy 18 (25). In the presented study, 23 (100%) had abnormalities detected by ultrasound. Only four (19%) had positive trisomy 18 screen or fetuses with positive biochemical marker screening test.

In the presented study ventricular and atrioventricular septal defects, strawberry-shaped head, choroid plexus cyst, cystic hygroma, agenesis/hypoplasia vermis, pleural effusions, single umbilical artery, facial cleft, polyhydroamnios, abnormal extremities as clenched hands or polydactyly in were the most seen abnormal findings in trisomy 18 cases, as former stated in the literature. The association between choroid plexus cysts and trisomy 18 has been well-documented (26). In the presented study, 42% of the fetuses had choroid plexus cysts. In other studies, cardiac abnormalities could be seen in 90% with ventricular septal defect (VSD), patent ductus arteriosus, atrial septal defect (ASD), and dextroposition, in decreasing order of frequency (2). However, in the presented study, we found this in only 71.4% of cases. A ventricular septal defect was demonstrated in 9 of the 21 (42%) and atrioventricular defect in 4 cases (19%). In addition, two fetuses showed double outlet right ventricle and three fetuses showed tetralogy of Fallot. They hypothesized that hemodynamic changes due to valvular abnormalities and hypoplasia of the great vessels may be the mechanism underlying the increased nuchal translucency observed in trisomic fetuses (27). Some other signs such as nuchal edema, hydronephrosis, which are commonly related to trisomy 21 in the second trimester and some cases of trisomy 18, attended at midpregnancy.

Although this is a small series, it suggests that fetuses with trisomy 18 have their own sonographic patterns, though could be overlapped with other syndromes, and detailed ultrasonography at midpregnancy could effectively screen for further definite genetic testing. When any of the findings described above are found consideration should be given to, the possibility of trisomy 18 and a careful anatomical survey should be performed to look for additional sonographic signs of this trisomy. The presented data showed that most fetuses had multiple sonomarkers but the number and severity are

highly variable. It is difficult for this small series to specify which abnormality is the best predictor, but the more abnormal findings, the more likely it is to be the syndrome. Recently, a study about abnormal sonographic features of 38 fetuses identified with trisomy 18 and the sensitivity of sonographic abnormalities was reported. They found that all trisomy 18 cases had 4 or more prenatally detected sonographic abnormalities, and the sensitivity of sonographic detection of fetuses with trisomy 18 was 100% (28). DeVore (29) reported a detection rate of 99% with the inclusion of fetal echocardiogram. In the presented study, all trisomy 18 cases had at least two or more anomalous findings. Therefore, our opinion is, that second trimester screening is the most important way in detecting trisomy 18 cases.

An 11-14 weeks' gestational nuchal translucency scan, including early cardiac scanning and neurosonography and excluding cystic hygroma, which is an indication for karyotyping, can also demonstrative. There are a few references in literature (30-33) which propose first trimester screening and report a detection rate of approximately 80% for fetal aneuploidy in this period.

In conclusion, early prenatal diagnosis of this lethal syndrome can reduce the maternal morbidity and provides an opportunity for the family to decide upon termination. Fetal abnormalities and soft markers must be separated. One soft marker alone is not an indication for karyotyping. Our study confirms that no bright test exists for the prenatal screening test of this highly lethal congenital anomaly, except for ultrasonography, as most cases of trisomy 18 and 13 had at least two or more sonographically detectable structural abnormalities. Therefore, prenatal screening should be proposed, first at 11-14 gestational weeks and finally at 18-22 gestational weeks for every pregnancy.

References

- Edwards MT, Smith WL, Hanson J et al. A new trisomic syndrome. *Lancet* 1960;1:787-9.
- Jones KL. *Smith's Recognizable Patterns of Human Malformation*, 5th edition. Philadelphia: W.B. Saunders; 1997:14-5.
- Rasmussen SA, Wong LY, Yang Q et al. Population-based analyses of mortality in trisomy 13 and trisomy 18. *Pediatrics* 2003;111:777-84.
- Nicolaides KH, Snijders RJM, Gosden CM et al. Ultrasonographically detectable markers of fetal chromosomal abnormalities. *Lancet* 1992;340:704-7.
- Sherod C, Sebire NJ, Soares W et al. Prenatal diagnosis of trisomy 18 at the 10-14 week ultrasound scan. *Ultrasound Obstet Gynecol* 1997;10:387-90.
- Gembruch U, Baschat AA, Knöpfle G, Hansmann M. Results of chromosomal analysis in fetuses with cardiac anomalies as diagnosed by first- and early second-trimester echocardiography. *Ultrasound Obstet Gynecol* 1997;10:391-6.
- Patau K. Multiple congenital anomaly caused by an extra chromosome. *Lancet* 1960;1:790-5.
- Nicolaides KH, Azar G, Byrne D et al. Fetal nuchal translucency: Ultrasound screening for chromosomal defects in first trimester of pregnancy. *BMJ* 1992;304:967-9.
- DeVore GR. Second trimester ultrasonography may identify 77-95% of fetuses with trisomy 18. *J Ultrasound Med* 2000;19:565-76.
- De Vigan C, Baena N, Cariati E, Clementi M, Stoll C, and the EUROSCAN working group. Contribution of ultrasonographic examination to the prenatal detection of chromosomal abnormalities in 19 centers across. *Europe Ann Genet* 2001;44:209-17.
- American College of Obstetrics and Gynecology: Ultrasonography in pregnancy. ACOG 1994; Technical Bulletin 187:1.
- American Institute of Ultrasound in Medicine: Antepartum obstetrical guidelines. *J Ultrasound Med* 1986;5:241.
- Lehman CD, Nyberg DA, Winter III TC et al. Trisomy 13 syndrome: Prenatal US findings in a review of 33 cases. *Radiology* 1995;194:217-22.
- Greene MF, Benacerraf BR, Frigoletto Jr FD. Reliable criteria for the prenatal sonographic diagnosis of alobar holoprosencephaly. *Am J Obstet Gynecol* 1987;56:687-9.
- Benacerraf BR, Nadel A, Bromley B. Identification of second trimester fetuses with autosomal trisomy by use of sonographic scoring index. *Radiology* 1994;193:135-40.
- Benacerraf BR, Nyberg D, Bromley B, Frigoletto FD. Sonographic scoring index for prenatal detection of chromosomal abnormalities. *J Ultrasound Med* 1992;11:449-58.
- Başer İ. Fetal anöplöidi olgularında 2. trimester ultrasonografinin etkinliği ve yeri. *T Klin Jineköl Obstet* 2002;12:364-70.
- Wald NJ, Watt HC, Hackshaw AK. Integrated screening for Down's syndrome based on tests performed during the first and second trimester. *N Engl J Med* 1999;341:461-7.
- Merkatz IR, Nitowsky HM, Macri JN, Johnson WE. An association between low maternal serum alpha-fetoprotein and fetal chromosomal abnormalities. *Am J Obstet Gynecol* 1984;148:886-94.
- Bogart MH, Pandian MR, Jones OW. 1987. Abnormal maternal serum chorionic gonadotrophin levels in pregnancies with fetal chromosome abnormalities. *Prenat Diagn* 1987;7:623-30.
- Canick JA, Knight GJ, Palomaki GE et al. 1988. Low second trimester maternal serum unconjugated estriol in pregnancies with Down syndrome. *Br J Obstet Gynecol* 1988;195:330-3.
- Pandya P, Snijders R, Johnson S et al. Screening for fetal trisomies by maternal age and fetal nuchal translucency thickness at 10-14 weeks of gestation. *Br J Obstet Gynecol* 1995;102:957-62.
- Bahado-Singh RO, Choi SJ, Oz U et al. Early second-trimester individualized estimation of trisomy 18 risk by ultrasound. *Obstet Gynecol* 2003;101:463-8.
- Hobbins JC, Lezotte DC, Persutte WH et al. 2003. An 8-center study to evaluate the utility of midterm genetic sonograms among high-risk pregnancies. *J Ultrasound Med* 2003;22:33-8.
- Brumfield CG, Wenstrom KD, Owen J, Davis RO. Ultrasound findings and multiple marker screening in trisomy 18. *Obstet Gynecol* 2000;95:51-4.
- Walkinshaw S, Pilling D, Spriggs A. Isolated choroid plexus cyst – the need for routine offer of karyotyping. *Prenat Diagn* 1994;14:663.
- Hyett JA, Moscoso G, Nicolaides KH. Cardiac defects in 1st trimester fetuses with trisomy 18. *Fetal Diagn Ther* 1995;10:381-6.
- Yeo Lami, Guzman ER, Day-Salvatore D et al. Prenatal detection of fetal trisomy 18 through abnormal sonographic features. *J Ultrasound Med* 2003;22:581-90.
- DeVore G. OC125: Genetic ultrasound: 99% detection rate for trisomy 13, 18 and 21. *Ultrasound Obstet Gynecol* 2007;30:405.
- Geipel A, Daiss T, Katalinic A et al. Changing attitudes towards non-invasive aneuploidy screening at advanced maternal age in a German tertiary care center. *Ultraschall Med* 2007;28:67-70.
- Spencer K, Nicolaides KH. A first trimester trisomy 13 / trisomy 18 risk algorithm combining fetal nuchal translucency thickness, maternal serum free beta-hCG and PAPP-A. *Prenat Diagn* 2002;22:877-9.
- Sen C. The use of first trimester ultrasound in routine practice. *J Perinat Med* 2001;29:212-21.
- Hyett JA, Moscoso G, Nicolaides KH. Cardiac defects in 1st trimester fetuses with trisomy 18. *Fetal Diagn Ther* 1995 Nov-Dec;10:381-6.