

The Importance of Using PET/CT Investigation in Case of Recurrence in an Ovarian Cancer Case with Lymph Node Metastasis Without any Lesions That can be Scanned via Conventional Methods

Özgür TANRIVERDİ¹, Sernaz UZUNOĞLU¹, Hakan KARAGÖL¹, İrfan CİCİN¹, Ruşen COŞAR ALAS²,
Füsün TOKATLI², Şemsi ALTANER³

¹Division of Medical Oncology, Department of Internal Medicine, Faculty of Medicine, Trakya University, Edirne, Turkey

²Department of Radiation Oncology, Faculty of Medicine, Trakya University, Edirne, Turkey

³Department of Pathology, Faculty of Medicine, Trakya University, Edirne, Turkey

Received 17 January 2008; received in revised form 11 March 2008; accepted 18 March 2008;
published online 28 August 2008

Abstract

Although lymph node involvement is common in ovarian cancer, axillary and supraclavicular lymph node involvement is quite rare. In the 55-year-old patient without any lesions that are scannable via conventional methods, in which increase of CA-125 level was detected during follow-up, recurrence was detected via combined positron emission tomography and computed tomography investigation. This case recurring with intraabdominal and supraclavicular and axillary lymph node (which are rare regions of involvement) metastasis has been discussed with literature information. In this article, the importance of combined positron emission tomography and computed tomography investigation in patients with suspected recurrence in whom no tumor detectable via conventional methods has been identified was highlighted.

Keywords: ovarian cancer, lymph node metastasis, prognosis, axillary lymph node, supraclavicular lymph node

Özet

Rekürrensli Bir Lenf Nodu Metastazlı Over Kanseri Olgusunda Konvansiyonel Metotlarla Lezyon Görülemediği Durumlarda PET/BT Kullanımının Önemi

Over kanserlerinde lenf nodu tutulumu sık olmakla birlikte, aksiller ve supraklaviküler lenf nodu tutulumu nadirdir. Takibi sırasında CA-125 seviyesinde artış tespit edildiği halde konvansiyonel metotlarla herhangi bir lezyon tespit edilemeyen 55 yaşındaki over kanserli hastada rekürrens pozitron emisyon tomografisi ve bilgisayarlı tomografinin birlikte kullanımı ile tespit edildi. Ender tutulum gösteren supraklaviküler ve aksiller lenf nodu ve intraabdominal lenf nodu tutulumu ile rekürrens saptanan hasta literatür ışığında tartışıldı. Bu olguda konvansiyonel metotlarla herhangi bir tümör saptanmayan durumlarda pozitron emisyon tomografisi ve bilgisayarlı tomografinin birlikte kullanımının öneminin altı çizildi.

Anahtar sözcükler: over kanseri, lenf nodu metastazı, prognoz, aksiller lenf nodu, supraklaviküler lenf nodu

Introduction

Ovarian carcinoma, the third most common gynecological cancer often manifests as advanced stage intra-abdominal disease and generally progresses in a fatal manner (1-4). Combined chemotherapy comprising Platinum and Paclitaxel is the primary treatment for ovarian cancer and

usually, complete clinic response is achieved. Despite this, most of the patients with ovarian cancer with a good baseline response develop recurrence (5). Despite the rarity of tumor spread via lymphatic way, lymph node (LN) metastasis is particularly prevalent in the pelvic and retroperitoneal LN regions (3). However, occurrence or recurrence of the disease with extra-abdominal LN metastasis and primarily supraclavicular and axillary regions is rare (2,6,7). Ovarian cancer recurrence is known to have a poor prognosis and early detection of recurrence is known to affect the response to treatment (2-4). Positron emission tomography (PET)

Corresponding Author: Dr. Özgür Tanrıverdi
Trakya Üniversitesi Tıp Fakültesi Güllapoğlu Yerleşkesi,
Medikal Onkoloji Kliniği, Edirne, Türkiye
Phone : +90 212 697 41 49
GSM : +90 532 391 79 28

should be used in cases of recurrence of ovarian cancer suspected by the increases detected during monitoring of the CA-125 values (3-8). Use of PET in combination with CT has an important place in detection of ovarian cancer recurrence. Combined PET/CT investigation is reported to have a sensitivity of 95.5% and a specificity of 100% in detection of ovarian cancer recurring with local or LN involvement that can not be scanned via conventional methods (5). We have aimed to present this case of ovarian cancer without a scannable intra-abdominal lesion, recurring with abdominal LN and axillary and supraclavicular LN involvement, which are rare regions of metastasis so that it would represent an example for metastasis of rare LN regions. This article has highlighted the need to investigate the disease recurrence via PET or combined PET/CT imaging methods in patients with ovarian cancer with increased CA-125 levels with no scannable lesion detected.

Case Report

The 55-year-old patient presenting with the complaint of swelling and abdominal discomfort in the right inguinal region had no pathological finding detected on examination, except a right inguinal 1-1.5 cm painless lymphadenopathy (LAP). The ultrasonography (US) performed revealed a mass in the right ovary and the abdominal CT revealed a 4 to 5 cm diameter nodular density in adjacency to the abdominal anterior wall and descending column ventrolateral at the right infrarenal level. The patient with a detected serum CA-125 value of 373 U/ml (N: 1.9-16.3) was diagnosed with ovarian tumor and total abdominal hysterectomy bilateral salpingo-oophorectomy was performed. The histopathological diagnosis was a case of moderate differential serous papillary carcinoma at stage IIIC (Figure 2a). The patient received 6 courses of Paclitaxel (175 mg/m²) and Carboplatin (AUCx6) combined chemotherapy regimen. The patient's CA-125 level, which had returned to normal (4.7 U/ml) at 10 months of chemotherapy, showed an increase again (297 U/ml). The chest and abdominal CT investigations detected no pathology while the PET investigation showed recurrence with intense hypermetabolic involvement in the pelvic vaginal dome (SUV_{max}: 10.7), upper mediastinum right prevascular region (SUV_{max}: 6.8), supraclavicular region (SUV_{max}: 3.9), right axillary region. Combined chemotherapy with 6 courses of Paclitaxel and Carboplatin was re-administered and radiotherapy was administered to vaginal stump. The patient with a complete clinical, radiological and marker response was detected to have palpable swelling in the right axillary region 2.5 years after the first presentation and 10 months after the first recurrence. The investigations performed revealed an increased CA-125 level (328 U/ml) while the chest and abdominal CT investigations were normal. The requested PET investigation revealed pelvic and para-aortic hypermetabolic involvement, right axillary (SUV_{max} 5.7) and supraclavicular LAM (SUV_{max}: 5.1) (Figure 1). The right axillary LAM excisional biopsy

revealed carcinoma metastasis (Figure 2b) while the breast and thyroid investigations detected no pathology. Chemotherapy was initiated with liposomal doxorubicin. The patient who revealed normalization of CA-125 levels (2.35 U/ml) and no pathology on control PET/CT investigation is still under monitoring without progression.

Discussion

Recurrence of ovarian cancer is a significant and fatal issue. The most common form of recurrence observed during the early post-operative period is the peritoneally disseminated lesion. Although LN metastasis is an established character of recurrence in patients with ovarian cancer, the rate of patients presenting with LN involvement for the first time or at recurrence is quite low (9). The most common areas of LN involvement are reported to be abdominal (47%), para-aortic (38%), mediastinal (29%) and pelvic (17%). While supraclavicular and inguinal LN involvement is reported to be 4% and 3%, respectively, axillary LN metastasis is quite rare. In autopsies performed in 100 women diagnosed with ovarian cancer, supraclavicular LN involvement was 4% while abdominal LN involvement, para-aortic LN, mediastinal LN and pelvic involvement were 47%, 38%, 29% and 17%, respectively. Axillary LN involvement was not reported (8). Euscher et al. detected supraclavicular and axillary LN involvement in, respectively, 11 and 2 of the 35 patients with minimal peritoneal disease and extra-abdominal LN metastasis (2). Our patient is a case recurring with supraclavicular and axillary LN metastases together with abdominal LN involvement and represents a rare example with respect to place of involvement and type of recurrence.

Isolated LN metastasis includes LN involvement detected without clinical and radiological solid organ involvement such as liver, lung or pleura or peritoneal carcinomatosis and has been reported to have a prevalence of 4.2% and to exhibit a better prognosis in 25% of the patients (6). Our patient also has presented with extra-abdominal and intra-abdominal LN involvement without clinically or radiologically detectable metastasis.

A progressive increase in serum CA-125 level is considered to cast suspicion with respect to ovarian cancer recurrence. However, no association was detected between the CA-125 level and the local or prevalent disease (4). Monitoring of serum CA-125 level has a sensitivity of 79-73% and a positive predictive value of 100% in estimation of recurring ovarian cancer (4). Also in our patient, recurrence was detected during the follow-up of the CA-125 level that was normal at the time of complete response achievement.

Although CT is an imaging method preferred for the follow-up of patients with diagnosis of ovarian cancer, it has a limited capacity particularly in imaging of the residual tumors in minor metastases (4). Different studies

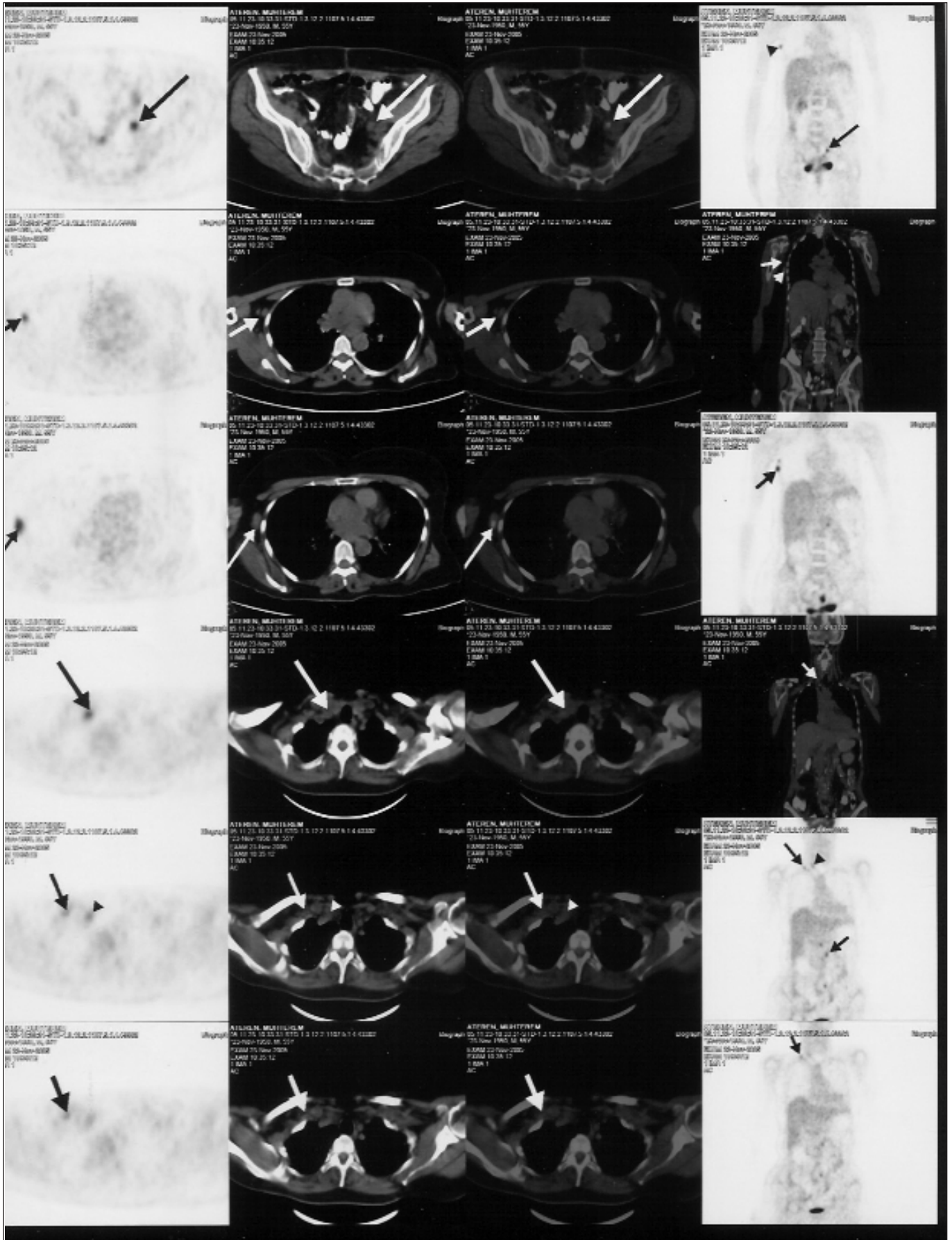


Figure 1. The requested PET investigation revealed pelvic and para-aortic hypermetabolic involvement, right axillary (SUV_{max}: 5.7) and supraclavicular LAM (SUV_{max}: 5.1).

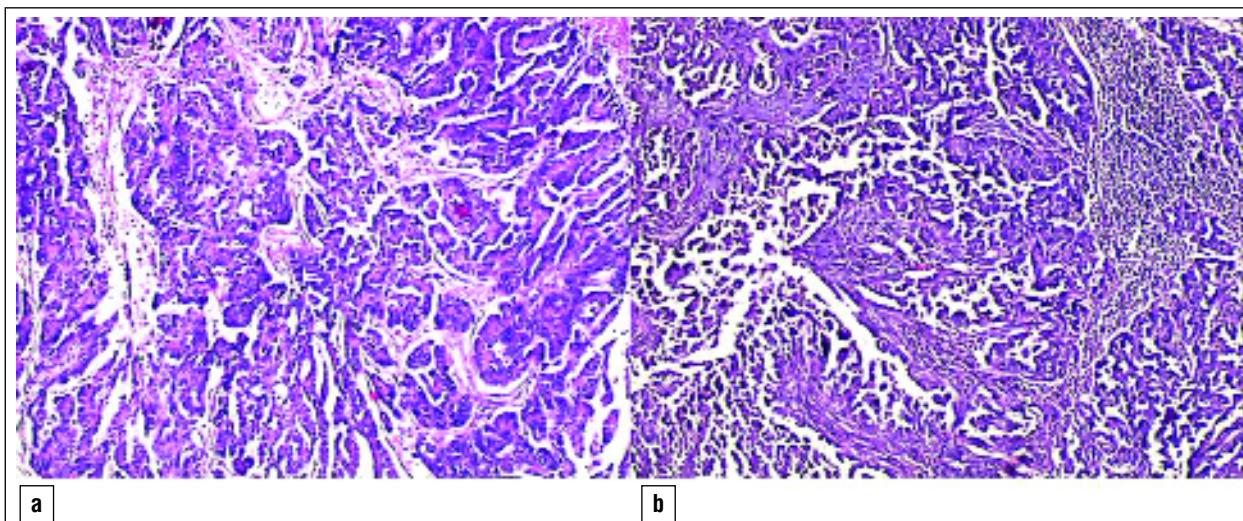


Figure 2. Histopathological examination revealed moderate papillary carcinoma (a: H+E x200) and carcinoma the right axillary LAM (b: H+E x200).

recommend PET investigation in imaging of the residual tumor in cases of ovarian cancer with suspicion of recurrence irrespective of the presence of suspicious CT findings (4). PET is a method of imaging based on the metabolic difference between the malign and benign tissues (4). When compared, the sensitivity of the PET and CT were found to be 87% and 53%, respectively in the detection of ovarian cancer with suspected recurrence and increased CA-125 level (3,4). In the prospective study by Bristow et al. in 22 patients suspected with recurrence due to high levels of CA-125, the sensitivity and positive predictivity of the PET/CT investigation was reported to be 83% and 93%, respectively for lesions larger than 1 cm (10). Thus, the PET investigation detected pelvic, axillary and supraclavicular LN metastases in absence of intra-abdominal lesions.

In conclusion, PET and PET/CT investigations have gained importance in detection of recurrence and particularly of LN metastases in patients with ovarian cancer without any lesions scannable via conventional methods although an increase in CA-125 levels has been detected on follow-up. Ovarian tumors may rarely manifest axillary and supraclavicular LN metastasis and this involvement doesn't necessarily have to be the second primary cancer metastasis. In our case, the pathological assessment of the axillary involvement observed in the second recurrence revealed the same histopathological structure with the primary tumor.

We have aimed to present this case of ovarian cancer with axillary and supraclavicular LN involvement as an example for rare sites of metastasis and the type of recurrence as well as to highlight that PET investigation would be useful for

detection of LN involvement and pelvic metastasis in many cases where metastasis can not be detected via conventional imaging techniques.

References

1. Orris BG, Geisler JP, Geisler HE. Ovarian carcinoma metastatic to bilateral axillary lymph nodes: A case report. *Eur J Gynaecol Oncol* 1999;20:189-90.
2. Euscher ED, Silva EG, Deavers MT et al. Serous carcinoma of the ovary, fallopian tube, or peritoneum presenting as lymphadenopathy. *Am J Surg Pathol* 2004;28:1217-23.
3. Fanti S, Nanni C, Castelluci P et al. Supraclavicular lymph node metastatic spread in patients with ovarian cancer disclosed at 18F-FDG-PET/CT: an unusual finding. *Cancer Imaging* 2006;6:20-3.
4. Gontier E, Wortschi M, Guinebretiere JM, Alberini JL. 18F-FDG-PET/CT in a patient with lymph node metastasis from ovarian adenocarcinoma. *AJR* 2006;187:285-9.
5. Thrall MM, Deloia JA, Gallion H, Avril N. Clinical use of combined positron emission tomography and computed tomography (FDG-PET/CT) in recurrent ovarian cancer. *Gynecol Oncol* 2007;105:17-22.
6. Blanchard P, Plantade A, Pages C et al. Isolated lymph node relapse of epithelial ovarian carcinoma: Outcomes and prognostic factors. *Gynecol Oncol* 2007;104:41-5.
7. Mahdavi A, Malviya VK, Husain M. Metastatic inguinal lymphadenopathy, presenting as the only physical evidence of recurrent ovarian carcinoma. *J Gynecol Surg* 2003;19:81-3.
8. Dvoretzky PM, Richards KA, Angel K et al. Distribution of disease at autopsy in 100 women with ovarian cancer. *Hum Pathol* 1988;19:57-63.
9. Hockstein S, Keh P, Lurain JR, Fishman DA. Ovarian carcinoma initially presenting as metabolic axillary lymphadenopathy. *Gynecol Oncol* 1997;65:543-7.
10. Bristow RE, del Carmen MG, Pannu HK et al. Clinically occult recurrent ovarian cancer: patient selection for secondary cytoreductive surgery using combined PET/CT. *Gynecol Oncol* 2003;90:519-28.
11. Recine MA, Deavers MT, Middleton LP et al. Serous carcinoma of the ovary and peritoneum with metastases to the breast and axillary lymph nodes: a potential pitfall. *Am J Surg Pathol* 2004;28:1646-51.