

# Clomiphene May Not Cause Neoplasia in the Ovary: An Animal Study on Ovarian Morphology, Biochemistry and Histochemistry

Chinmoy K. BOSE

The Kolkata Municipal Corporation, Kolkata, India

Received 31 December 2007; received in revised form 09 May 2008; accepted 10 May 2008;

published 01 September 2008

## Abstract

**Objective:** Many recent reports have shown that drugs used for ovulation induction may be associated with ovarian cancer, at least among certain subgroups of users. These studies have discouraged a 'blanket approach' and suggested the need for continued monitoring of long-term risks of such treatment. Clomiphene (2-[p-chloro-1, 2-diphenylvinyl] phenoxy) triethylamine) has been the ovulation inducing drug thus implicated in majority of the studies. However, there is paucity of study of its effect on ovary either *in vivo* or *in vitro*, indicating the necessity of further investigations. A case-control animal experiment in collaboration with a postgraduate home science department of a university has been planned and executed on seven mice of Swiss strain to see the effects of clomiphene in ovary and liver.

**Materials and Methods:** Against control mice, four mice were fed with 0.4 mg clomiphene citrate continuously for 45 days and then sacrificed to investigate changes in the ovaries and livers.

**Results:** The clomiphene-treated mice lost weight; liver peroxidase levels were high whereas the protein and glycogen levels were low. In the ovaries abundant follicular development and a striking increase in fibrosis was shown by histochemistry. Tissue homogenates showed exceptionally high alkaline phosphatase activity, also corroborated by histochemistry, probably due to the many growing follicles. No benign or malignant tumour could be detected in any of these samples.

**Discussion:** Clomiphene may not cause cancer of ovary. It is difficult to say whether clomiphene or infertility is the cause of some of reported association of cancer after clomiphene.

**Keywords:** clomiphene, Swiss mice, liver peroxidase, Graafian follicle, alkaline phosphatase

## Özet

### Klomifen Overde Neoplaziye Sebep Olmayabilir: Over Morfolojisi, Biyokimyası ve Histokimyası Üzerine Bir Hayvan Çalışması

**Amaç:** Birçok güncel çalışma, özellikle ilaç kullanan bazı altgruplarda ovülasyon indüksiyonu için kullanılan ilaçların over kanseri ile ilişkili olabileceğini göstermiştir. Bu yüzden, bu çalışmalar hastalarda uzun dönemde ortaya çıkabilecek risklerin takibini desteklemiştir. Bu çalışmaların çoğunda vurgulanan ilaç klomifendir. Ancak, klomifenin *in vivo* veya *in vitro* olarak overin üzerindeki etkisini gösteren çalışma sayısı azdır. Bu tür çalışmalara ihtiyaç vardır. Klomifenin over ve karaciğer üzerindeki etkisini görmek için İsveç türü yedi fare üzerinde bir çalışma planlandı.

**Materyal ve Metot:** Kontrol farelerle karşılaştırmak üzere dört fare 45 gün boyunca 0.4 mg klomifen sitrat ile beslendi ve sonra öldürüldü.

**Sonuçlar:** Fareler kilo kaybettiler; karaciğer peroksidaz seviyeleri yüksek, karaciğer protein ve glikojen seviyeleri ise düşüktü. Overde yoğun foliküler gelişim gözlemlendi. En çarpıcı bulgu, histokimyasal olarak gösterilen fibrozis artışıydı. Doku homojenatında, büyük olasılıkla büyüyen foliküllere bağlı olarak, histokimyasal bulgular ile uyumlu bir alkalen fosfataz artışı görüldü. Olguların hiçbirinde benign veya malign tümör oluşumuna rastlanmadı.

**Tartışma:** Klomifen overde kansere yol açmayabilir. Var olan kanser ile ilişki bulan yayınlarda infertilitenin mi yoksa klomifenin mi kansere yol açtığını söylemek zordur.

**Anahtar sözcükler:** klomifen sitrat, İsveç faresi, karaciğer peroksidaz seviyesi, Graafian folliküller, alkalen fosfataz

**Corresponding Author:** Dr. Chinmoy K. Bose  
8d, Mathur Sen Garden Lane Kolkata, India  
**Phone** : +91 332 272 32 64  
**GSM** : +98 301 14 880  
**E-mail** : ckbose@hotmail.com

## Introduction

Ovulation-inducing drugs have been widely used for various types of infertility since the early 1960s, and their use is ever increasing. However, proof has been presented to raise serious doubt about the safety of these drugs and the risk of malignancy associated with their use. There is a recent surge of case reports and studies in world literature on the possible carcinogenic effect of fertility drugs on the ovary. Whether there is causality or association between exposure to ovulation-inducing drugs and the incidence of various cancers been discussed but no general consensus has emerged. For example, a systematic review can show at least 95 cases of ovarian cancer in 15 publications. Clomiphene citrate (CC) and human menopausal gonadotrophin (HMG) are the two fertility drugs implicated in these reports (1). In 25.3% of the cases HMG had been used alone and in 74% cases CC had been used either alone or combination with HMG. Hence, many reviews and meta-analyses have been issued on the subject. A recent study has shown a stronger association between fertility drug use and borderline tumors of the ovary. Although it has been commented that the finding of ovarian cancer risk (especially for invasive epithelial and non-epithelial cancer) associated with fertility drug treatment is reassuring, a need for well-designed clinical trials to understand any possible carcinogenic effects of the ovulation-inducing drugs has also been emphasized (2). There is indeed an urgent need for this in order to understand effect of clomiphene on the ovary and to establish the safety of its use, which has not been done in the requisite detail as yet. In recent years two animal studies have been reported; one having been on the use of Follitorpin  $\beta$  and the other, more recent one, on the use of clomiphene in the rat. These have been limited to studying the change in ovarian morphology by naked eye and by microscopy. Some dysplasia of granulosa cell were observed and but no other observation was made on cellular morphology compatible with neoplastic changes. No biochemical or histochemical tests have been carried out to date, in order to detect early neoplastic change with biochemical markers or at the receptor level. Hence, this limited animal experiment was planned on healthy female mice of Swiss strain to see the effect of CC on the ovary.

## Materials and Methods

Seven healthy female adult mice of Swiss strain weighing 30 g were kept in the laboratory under normal conditions for 7 days before experimental use. Fifty milligrams of CC [FERTYL, Ar-Ex Laboratories Pvt Ltd, 10 Cama Industrial Estate, Goregaon (E), Mumbai 400 063], was macerated and dissolved in 25 ml of water and fed to each study animal daily at a dose of 0.4 mg (0.2 ml). Daily mouse diet consisted of Pellets (Bengal gram 5 g daily) with specific nutritive ingredients (Hindustan Lever Ltd.; Animal Feeding Stuffs Department, 63 Garden Reach Road, Kolkata 700 024, India), supplemented with 0.06 ml drops of Vitamins ABDEC (Parke-Davis, India).

Three mice were used for control and four were taken as the experimental study group. The control group was kept on normal diet with no drug treatment and the experimental group were fed with CC over a period of 45 days and was watched closely for any change of behavior and body weight. After 45 days of treatment, and at the end of 6 hours of fasting, all the animals were anaesthetised by chloroform; abdomen of each animal was cut open and the liver and both ovaries were dissected out.

Adherent blood was blotted out from the liver surface; 100 mg pieces of each liver were accurately weighed and plunged (a) into 4.9 ml of  $6.7 \times 10^{-3} \text{M}$  phosphate buffer (1:10) (pH 7) for peroxidase, (b) into 2 ml of 30% KOH solution for glycogen, and (c) into 0.9 ml of normal saline for of alkaline phosphatase and protein estimations.

The ovaries from each side were dissected out above the uterine horn and the oviduct and was cleared of adherent fatty tissue. One of a pair was fixed in Bouin (1897) fixative for 24 hours for histology and the other was fixed in 80% chilled alcohol and kept under refrigeration for 24 hrs (3).

Paraffin embedded tissue sections were prepared and stained by Masson's trichrome (using Weighert's haematoxylin and Ponceau acid fuschsin) (4). In histopathological examination, malignant lesions, ovarian cyst formation, epithelial stratification, epithelial tufting, mitotic index, polymorphism of epithelial cells and nuclei, epithelial cell nuclear diameter, chromatin density, nuclear atypia, and mitotic activity in ovarian epithelial and granulosa cells were evaluated. For histochemical fixation and staining, the Gomori staining procedure was adopted using cobalt chloride and ammonium sulphide (5).

Liver peroxidase was assayed by Bergmeyer's process, using hydrogen peroxide, potassium permanganate, paraphenylylene diamine and potassium dihydrogen phosphate. Estimation of liver protein was made by the biuret method (6). Liver alkaline phosphatase was measured by para-nitrophenol, carbonate-bicarbonate buffer. The Montgomery method using potassium hydroxide and sodium sulphate, was elected for estimation of the liver glycogen (7).

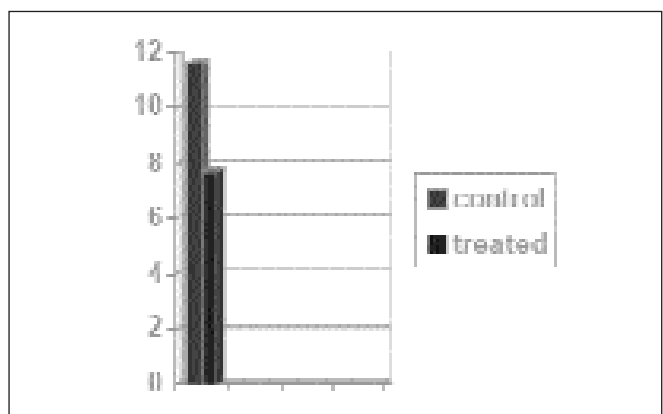


Figure 1. Average gain of weight in gram.

**Table 1.** Body weight of adult female mice during experimental period

Group	Sl. no	Animal no	Body weight (g)				
			Initial	Mean	Final	Mean	Average gain in body weight
Control	1	C1	30	30	40	41.66	11.66±1.67
	2	C2	30		40		
	3	C3	30		45		
Treated	1	T1	30	30	38	37.75	7.75±1.075 (p<0.01)
	2	T2	30		40		
	3	T3	30		38		
	4	T4	30		35		

**Table 2.** Total liver peroxidase level the treated and in the control groups of mice

Group	Sl. no	Animal	Liver peroxidase ( $\Delta$ OD/min/mg of protein)	Mean	Standard error (SE)
Control	1	C1	0.0135	0.0133	±0.00027
	2	C2	0.0137		
	3	C3	0.0128		
Treated	1	T1	0.014	0.0134 (p<0.1)	±0.00035
	2	T2	0.0127		
	3	T3	0.014		
	4	T4	0.0129		

**Table 3.** Liver glycogen levels in the treated and in the control groups of mice

Group	Sl. no	Animal	Glycogen (mg/g of tissue)	Mean	Standard error (SE)
Control	1	C1	10.99	11.27	±0.2043
	2	C2	11.67		
	3	C3	11.16		
Treated	1	T1	3.21	3.27 (P<0.001)	±0.3992
	2	T2	3.72		
	3	T3	2.76		
	4	T4	3.38		

**Table 4.** Liver protein levels in the treated and in the control groups of mice

Group	Sl. no	Animal	Liver protein (gm/100 ml of tissue homogenate)	Mean	Standard error (SE)
Control	1	C1	3.59	3.49	±0.056
	2	C2	3.46		
	3	C3	3.46		
Treated	1	T1	1.90	1.91 (p<0.001)	±0.099
	2	T2	2.15		
	3	T3	1.90		
	4	T4	1.675		

Recording of vaginal smear samples of both the control and the treated groups of mice was started on day 2 of the the experiment and continued until the end. Leishman's stain (5-7 drops) was used on each air-dried smear for one minute; which then was diluted two-fold with drops of distilled water and left for 15 minutes. The slide was then rinsed with water and dried by leaning on edge at room temperature and examined under high and low power of microscope.

## Results

Changes in body weight, and the biochemical, histological and histochemical features were noted and were compared for both the control and the experimentally treated groups (Table 1-5) (Figure 1).

Body weight of all mice was recorded individually at the beginning and just at the end of feeding and the results are

Table 5. Liver alkaline phosphatase activity in the treated and in the control groups of mice					
Group	Sl. no	Animal	P-N-P liberation (Mg/hour/ml of enzyme)	Mean	Standard error (S.E.)
Control	1	C1	0.085	0.063	±0.0148
	2	C2	0.035		
	3	C3	0.070		
Treated	1	T1	0.365	0.354 ( <i>p</i> <0.001)	±0.0071
	2	T2	0.335		
	3	T3	0.365		
	4	T4	0.350		

presented in Table 1. Weight gain was significantly less (*p*<0.01) in the experimentally treated group.

After Masson’s trichrome histological staining, the general morphology of the ovary was examined under the compound microscope at a magnification of x70. In the control group primordial follicles and maturing Graafian follicles were seen (Figure 2 and 3). In the treated group a greater number of both the primordial and the Graafian follicles could be seen. No new tumour formation was observed in any of the samples. No focal atypia and atypical mitoses were noted in

the epithelial or the granulosa cells. Only the numbers and distribution of the granulosa, theca and luteal cells were significantly more in the treated group.

Amongst significant findings, the amount of fibrous tissue was much higher in the ovarian cortex and stroma of the treated animals as compared to the controls (Figure 4 and 5). The alkaline phosphatase activity in the ovarian tissue was assessed by measuring the concentration of yellow ammonium sulphide as a black precipitation; i.e. the control group showed less alkaline phosphatase activity as a black

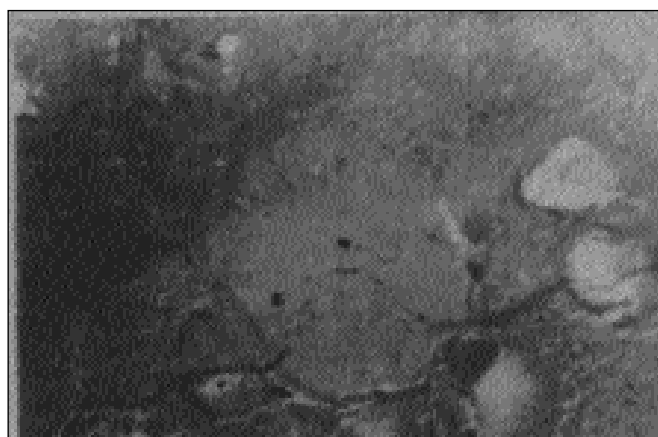

Figure 2. Normal distribution of primordial follicle and maturing Graafian follicle.



Figure 4. Fibrous tissue distribution in untreated cases.

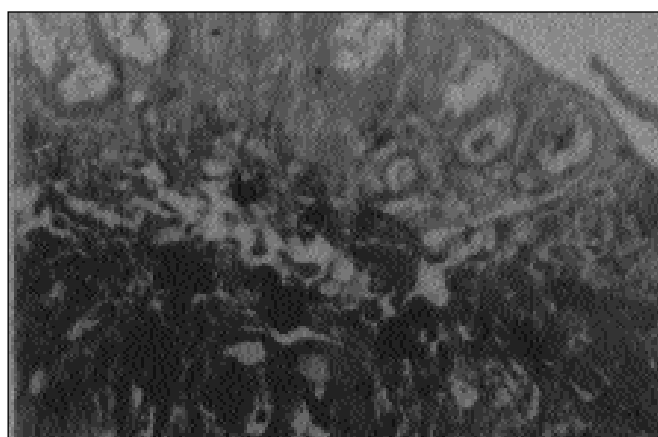


Figure 3. Greater number of both primordial and Graafian follicle.

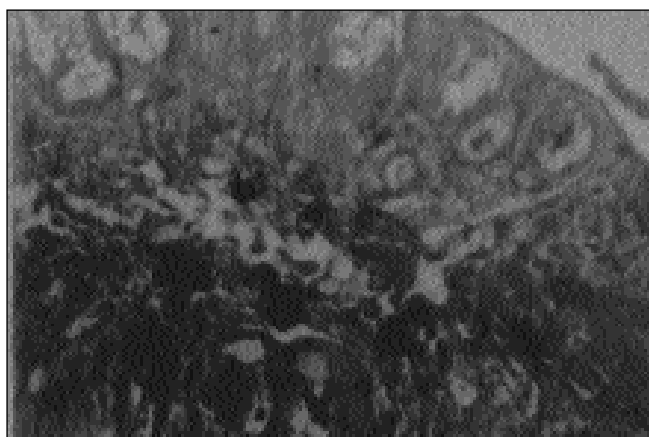
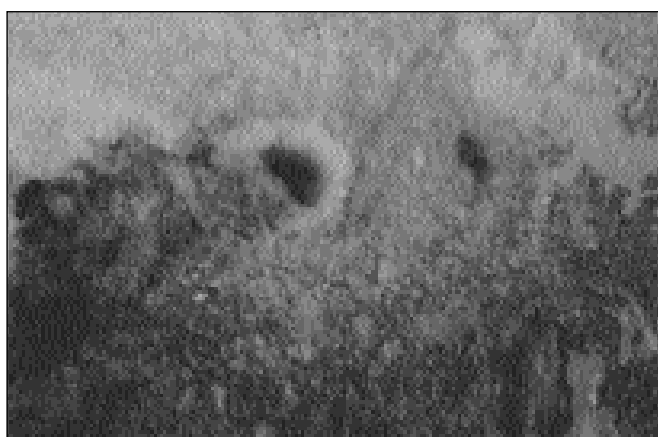

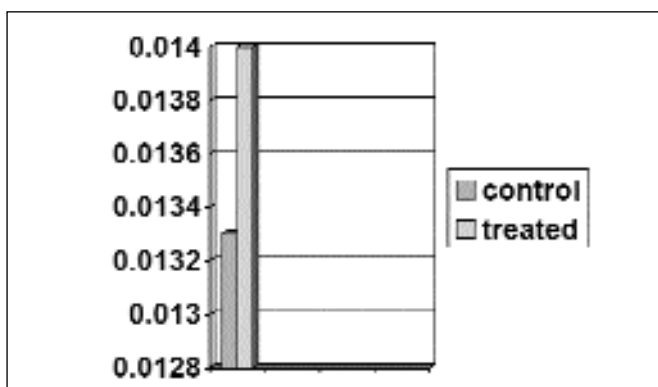
Figure 5. More abundant fibrous tissue distribution in treated cases.



**Figure 6.** Activity of alkaline phosphatase in the ovarian tissue of untreated cases.



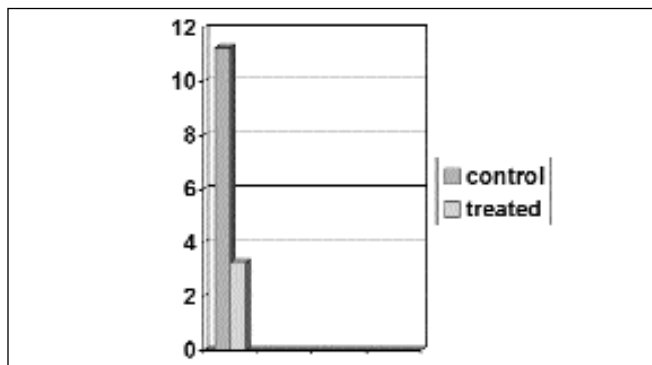
**Figure 7.** Higher activity of alkaline phosphatase in the ovarian tissue of untreated cases.



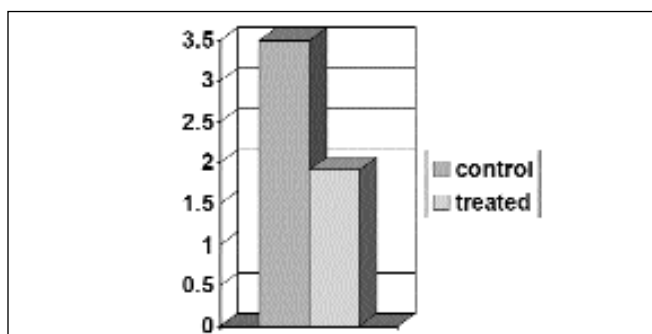
**Figure 8.** Mean liver peroxidase level in mice in OD/min/mg of protein.

precipitation in the stroma and cortical regions of the ovary. Ovaries of the treated mice showed high alkaline phosphatase activity in their stromal and cortical areas (Figure 6 and 7).

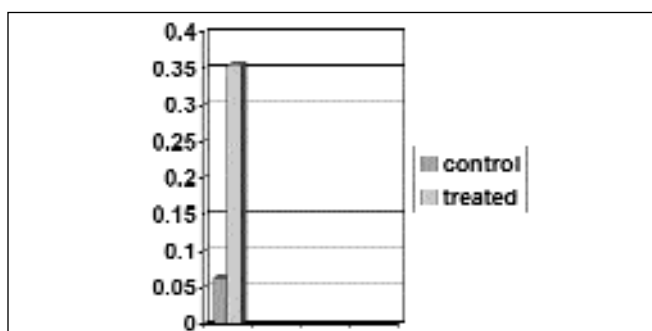
In the estrous cycle study, profuse estrous stage was observed in comparison to other stages (e.g. diestrous, proestrous, metestrous) in the experimentally treated group



**Figure 9.** Mean liver glycogen level in mg/gm of tissue.



**Figure 10.** Mean liver protein.



**Figure 11.** Mean alkaline phosphatase (PNP liberation in mg/hr/ml of enzyme).

whereas the control group showed normal estrous cycle mixed with the other cycle stages.

The results of the estimation of liver peroxidase activities are presented in Table 2 (Figure 8). A slightly increased peroxidase level in the experimental group in comparison to the control group is visible but the difference between the group means was not statistically significant.

The results of the liver glycogen level estimations are presented in Table 3 (Figure 9). In the treated animals, liver glycogen level was decreased which was statistically highly significant.

The results of the liver protein estimations are presented in Table 4 (Figure 10). In the treated animals, the liver protein level was decreased significantly.

The enzymatically determined liver alkaline phosphatase levels have been presented in Table 5 (Figure 11). In the treated animals, alkaline phosphatase activity was increased significantly.

## Discussion

We have given 18 mg of CC, in 0.4 mg daily doses, per animal on a continuous 45-day regime. Catabolic steriodogenic effect may be responsible for the observed weight loss, the high liver peroxidase activity, and the lowering of the liver glycogen and protein. The claimed carcinogenesis by clomiphene may be a direct effect of this compound on the ovarian structure or it could be due to the high endogenous gonadotrophin levels. There are two recent animal experiments on the rat ovary with ovulation inducing drugs. An established Turkish group carried out an animal study on the effects of ovulation induction by chorionic Follitropin  $\beta$  on ovarian morphology in 2004. After 1 to 6 cycles of ovulation induction with Follitropin  $\beta$  and HMG in 3 groups of rats no development of malignant lesion were observed despite the increase in the prevalence of epithelial dysplasia especially with the increase in the number of induction cycles, which showed that some ovarian pathologies could occur subsequently to ovulation induction (8). Özdemir et al, in a recent experiment, used up to 0.8 mg CC on a five-pulse monthly treatment for six months (9). They found that the numbers of granulosa, theca, and luteal cells of the CC 100- and the CC 200- treated groups to be significantly higher than those of the CC 50- treated and the control groups, which our findings corroborate with. Focal atypia and atypical mitoses were noted by them in the granulosa cells in 2 animals of the CC 100 and CC 200-treated groups. We did not make a similar observation which could be due to our usage of lower microscopic magnification of up to  $\times 70$ . In another more recent and important experiment with rats, the same group has been able to show, by the use of a micronucleus genotoxicity assay, a dose-dependent genomic instability effect of CC in bone marrow stem cells, *in vivo* (10).

This finding indicates the more work with CC. We could detect increased amounts of fibrous tissue in the cortex and stroma of the ovaries of the CC-treated mice. Postovulatory cicatrization could be cause of this high fibrous content of the CC-exposed ovary. Moreover, the elevated alkaline phosphatase activity of the ovarian tissue after CC treatment as evinced by the biochemical and histochemical analyses reported here denotes growing follicle and granulosa-theca

and luteal cells. We could not carry out placental alkaline phosphatase (PLAP) histochemistry by L-phenylalanine, L-leucine inhibition or monoclonal localization, due to resource constraints, albeit this alkaline phosphatase activity might partly be due to early tumour-specific PLAP denoting derepression of tumour cell genome (11-13) as well as indicating the post ovulatory overcicatrization. The large amount of continuous CC administration in our experiment has failed to induce any kind of tumour, either fibroma or benign and malignant epithelial tumour of ovary as proved by histology. This may indicate safety of the CC so far as any precipitation of neoplastic change is concerned. Though there are many speculations regarding carcinogenesis, our results suggest that the previously reported associations may not be causal in nature. However, more elaborate and basic work in biochemical and molecular biology is needed to find out changes in the ovarian cells due to clomiphene treatment.

## Acknowledgement

Support and help of the post graduate students and teachers of Home Science Department of Calcutta University is gratefully acknowledged.

## References

1. Bose CK. Fertility drug and ovarian cancer. J Obstet & Gynaecol of India 2000;50:100-1.
2. Mahdavi A, Pejovic T, Nezhat F. Induction of ovulation and ovarian cancer: a critical review of the literature. Fertil Steril 2006;85(4):819-26.
3. Bouin (1897) Arch d'Anat Micr, 1:225.
4. Bancroft JD and Stevens A. 2001. Theory and practice of histological techniques, London, England: Churchill Livingstone. pp 286.
5. Gomori G. Aldehyde-fuchsin: a new stain for elastic tissue. Am J Clin Pathol 1950;20(7):665-6.
6. Bergmeyer HU, Bernt E, Hess B. liver peroxidase, in Method of Enzymatic Analysis. Bergmeyer HU, editor. London: Academic Press; 1974. p. 753.
7. Montgomery R. Determination of glycogen. Arch Biochem Biophys 1967; 67:378-86.
8. Çelik C, Gezgin K, Aktan M et al. Effects of ovulation induction on ovarian morphology: an animal study. Int J Gynecol Cancer 2004;14(4):600-6.
9. Özdemir I, Üstündağ N, Güven A et al. Effect of clomiphene citrate on ovarian, endometrial, and cervical histologies in a rat model. Gynecol Obstet Invest 2005;60(4):181-5.
10. Duran B, Özdemir I, Demirel Y et al. In vivo evaluation of the genotoxic effects of clomiphene citrate on rat reticulocytes: a micronucleus genotoxicity. Gynecol Obstet Invest 2006;61(4):228-31.
11. Bose CK, Mukherjee M. Enzymatic tumour markers in ovarian cancer: a multiparametric study. Cancer Lett 1994;77(1):39-43.
12. Goldsmith JD, Pawel B, Goldblum JR et al. Detection and diagnostic utilization of placental alkaline phosphatase in muscular tissue and tumors with myogenic differentiation. Am J Surg Pathol 2002;26(12):1627-33.
13. al-Mudamgha ZA, Rassam MB, et al. Alkaline phosphatase of cancerous larynx tissue in comparison with the placental enzyme. Biochemical and histochemical studies. Acta Oncol 1997; 36(2):213-8.