

Nonimmunologic Hydrops Fetalis Associated with True Knot of Umbilical Cord: A Necropsy Study

Ashutosh HALDER

Department of Reproductive Biology, All India Institute of Medical Sciences, New Delhi, India

Received 09 May 2007; received in revised form 21 July 2007; accepted 03 September 2007;
published online 16 November 2007

Abstract

True umbilical cord knot is a common condition and often associated with perinatal morbidity and mortality. However, its association with hydrops fetalis is rarely observed. This report describes a case of hydrops fetalis associated with true knot of the umbilical cord. There were no other obvious causes for hydrops fetalis. On the basis of anatomic-pathological findings and review of the literature, the occurrence of hydrops due to umbilical cord true knot is proposed.

Keywords: placenta, non-immune hydrops fetalis, umbilical cord

Özet

Gerçek Umbilikal Kordon Düğümü ile İlişkili Non-immünolojik Hidrops Fetalis: Otopsi Sonuçları

Umbilikal kordonun gerçek düğümü sık görülen bir durumdur ve çoğunlukla perinatal morbidite ve mortalite ile ilişkilidir. Ancak, fetal hidrops ile ilişkisi nadiren gözlenir. Bu makalede, umbilikal kordonun gerçek düğümü ile ilişkili bir fetal hidrops olgusu tanımlanmıştır. Bariz başka bir fetal hidrops nedeni bulunamamıştır. Literatür gözden geçirilerek ve anatomik-patolojik bulgulara dayanılarak hidropsun umbilikal kordonun gerçek düğümüne bağlı olabileceği öne sürülmüştür.

Anahtar sözcükler: plasenta, nonimmün hidrops fetalis, umbilikal kord, gerçek düğüm

Introduction

Hydrops fetalis is defined as fluid accumulation in serous cavities of the fetus with variable degree of skin edema and with or without edematous placenta (1). Non-immunological hydrops fetalis (NIHF) is diagnosed when the cause of hydrops fetalis is other than fetomaternal blood group incompatibility (2). NIHF was first described by Potter in 1943 (3). The incidence of NIHF is reported to vary between 1 in 2500 to 3500 births (4). Numerous maternal, fetal and placental conditions can give rise to NIHF (5). However, the association of NIHF with umbilical cord true knot is reported only in few occasions (1,2,6). This report describes the necropsy study of a fetus with hydrops fetalis in association with the true knot of umbilical cord where no other causes for hydrops fetalis was apparent. A possible pathogenetic

mechanism for the causation of hydrops fetalis with true cord knot has been proposed.

Case Report

A hydropic female, stillborn fetus was sent for necropsy study. The stillborn fetus was delivered at 29 weeks of gestation to a primipara mother. The mother was 31 and the father was 36 years of age at the time of birth of the stillborn fetus. There was no consanguinity. The pregnancy was complicated by polyhydramnios which was symptomatic from 27 weeks when an obstetric ultrasound revealed hydrops fetalis. Ultrasonography did not find any malformations or cardiac arrhythmia in the fetus. Detailed fetal ultrasonography findings are given in Table 1. There was an excess of maternal weight gain, pedal edema and mild gestational hypertension during the pregnancy. Fetal death was diagnosed by ultrasonography two days before preterm delivery. The stillborn fetus was delivered by cesarean section because of failure of induction of labour.

At delivery fetus (Figure 1) and placenta were severely hydropic. Fetal edema was more marked over head and neck area. Generalized petechiae and ecchymosis were noted all

Corresponding Author: Dr. Ashutosh Halder
Ansarinagar 11002, New Delhi, India
Phone : +91 11 261 847 65
 +91 11 265 933 04
GSM : +90 93 133 095 79
E-mail : ashutoshhalder@yahoo.co.in



Figure 1. Clinical photograph showing hydroptic state.

over the body of the fetus but more so on face. There were no malformations on external and internal examinations. Feto-placental unit was intact as the cord had not been sectioned at delivery. Umbilical cord examination revealed a figure of eight knot. Antenatal and postnatal investigations of the mother and fetus excluded the possibility of immune hydrops fetalis and skeletal dysplasia (Table 1). Chromosomal analysis was not carried out because fetus and the placenta were sent in formalin. Fetal autopsy including histopathological examination of the placenta and fetal liver did not yield any evidence (eg. abnormal cells, inflammation, extramedullary hematopoiesis) for metabolic (eg. storage disorders) and infective causes, as well as alpha thalassemia that are commonly associated with NIHF (Table 1; Figure 2,3).

Table 1. Showing details of investigations undertaken at the time of detection of hydramnios antenatally, at delivery and at necropsy

Antenatal			
Hemoglobin (maternal)		10.4 g/dl	
Blood group and type (maternal)		B, rhesus negative	
Husband's blood group and type		AB, rhesus positive	
Indirect Coomb's test (maternal blood)		Negative	
Serological test for syphilis		Negative	
*Oral Glucose Tolerance test		Normal	
TORCH test (IgG and IgM)		No infection	
Ultrasonography (27+3 wks)		Singleton pregnancy with hydramnios and hydrops fetalis. No other congenital malformations. Fetal heart rate 140-160/minute, regular (no arrhythmias). Placenta large and thick. Umbilical cord edematous, umbilical vessels dilated	
At delivery			
Fetal blood group and type		AB, rhesus negative	
Direct Coomb's test		Negative	
Radiological examination		No skeletal dysplasia, no intracranial/intravascular calcifications, increase in subcutaneous thickness	
At necropsy examination (IUD 2 days prior to birth at 29 wks)			
Parameters	Observed	Expected Mean ±SD	Gross and microscopic
Fetal weight	1570 g	984±511	Large for date
Foot length	4.5 cm	5.3±0.9	Normal for date
Thymus	1.38 g	2.4±2.6	Depletion of lymphoid tissue in cortical region
Lungs	6.9 g	18.0± 8.6	Pulmonary hypoplasia
Heart	5.9 g	6.2±2.4	No abnormality
Liver	48.0 g	36.0±23	Congested parenchyma and dilated sinusoid
Adrenal	2.1	2.4±1.2	Marked edema in all the layers
Body cavities			Ascites, hydrothorax and pericardial effusion
Placenta weight	710 g	285±65	
Placenta microscopic			Large edematous. Chorionic villous stroma loosely arranged. Discrete chorionic villi, villous immaturity and hypovascularity with under development of vasculo-syncytial membranes. No inflammatory cell infiltrate. No storage cells. No extramedullary hematopoiesis.
Umbilical Cord Length (with knot)			31.5 cm (within normal range i.e., 35-80 cm)(17)
Vessels			Three in number, one dilatation and ruptured. Hemorrhage in surrounding tissue. Presence of organised thrombus.
*O'Sullivan method: Fasting (normal level <105 mg/dl) sample followed by 1 hour (normal level <190 mg/dl), 2 hour (normal level <165 mg/dl) and 3 hour (normal level <145 mg/dl) after 100 g of oral glucose challenge. Abnormal when 2 or more parameters are above the normal limit.			
From Textbook of Fetal and Perinatal Pathology (JS. Wigglesworth & D. Singer, eds.), Blackwell Scientific Publications, Boston, 1991.			

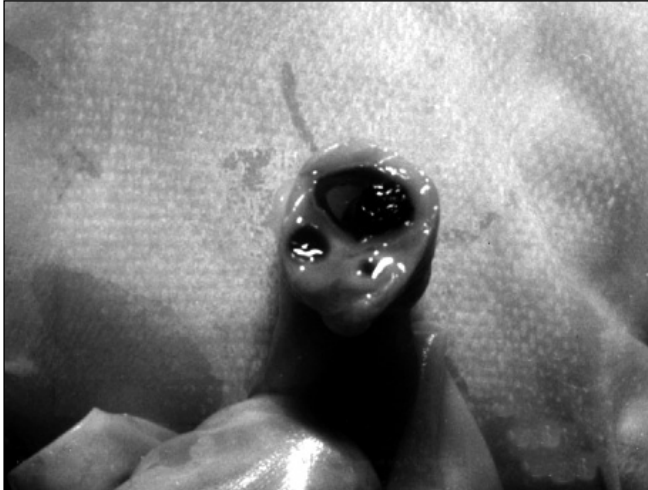

Figure 2. Section of umbilical cord (formalinized) showing three vessels including one dilated vein containing blood clot/thrombus.

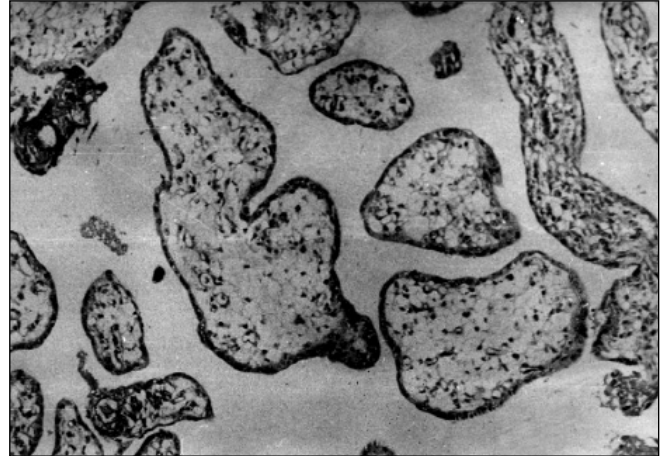


Figure 3. Microscopic (x40) placental section showing immaturity, hypovascularity and edema of chorionic villi.

Discussion

A case of NIHF in association with umbilical cord true knot is described in this report. Although umbilical cord true knot is a common occurrence (7-9), its association with hydrops fetalis is rare. It has been described only in few occasions and without explanatory investigations (1,2,6). The case described here was not due to rhesus incompatibility since fetal blood group and type was AB negative and the direct as well as the indirect Coomb's tests were negative. Radiological examination of the stillborn fetus had excluded the possibility of skeletal dysplasia. The chromosomal abnormality as a cause was also unlikely as there was no fetal malformation. Histopathological examination of the placental and fetal tissues did not show any large vacuolated cells (seen in storage disorders), extramedullary hematopoiesis (seen in alpha thalassemia), inflammatory cell infiltrates (seen in toxoplasmosis, cytomegalovirus infection, etc.) or cystadenomatoid malformation of lung. Hydrops due to parvovirus infection was also unlikely because there was no evidence of fetal anemia. Detailed examination could find umbilical cord true knot as sole association.


Although frequently umbilical cord true knot is asymptomatic (7-9), it may rarely produce hydrops fetalis (1,2,6). As the umbilical venous pressure (10 mmHg) is lower than the umbilical artery pressure, blood flow through umbilical vein is likely to be obstructed first leading to increase in hydrostatic pressure in umbilical vein proximal to obstruction (i.e., towards the placental side) and its consequences on the placenta and fetus (10,11). Umbilical venous partial obstruction in early stage could lead to a rise in intravillous capillary pressure resulting in edema towards the placental side and hypoxemia as well as hyponutrition towards the fetal side. Later, fetal cardiac function may be impaired because of rise in placental villous pressure. Collectively, it may give rise to hydrops fetalis. Increase in umbilical venous pressure following umbilical cord knot has been shown

experimentally (10). True knot of the umbilical cord may also result in transient constrictive effect on the umbilical venous blood flow (12,13). Similarly, umbilical vein thrombosis could increase pressure in placental vascular spaces causing fluid leakage and extravasation (14). The important factors affecting fetal fluid balance are chronic severe fetal anemia (leading to hypoxic capillary damage), hypoproteinemia (reducing colloid osmotic pressure), fetal heart failure (leading to reduction in fetal arterial hydrostatic pressure) and interference with fetoplacental circulation impedance to venous return from placenta (leading to placental villous edema and reduced efficiency of gas as well as solute exchange between maternal and fetal circulation) (15). Other important modifying factors involved in the genesis as well as the explanation of infrequent associations (16) are stage of gestation when the disorder first manifests (if it occurs during early fetal life, the fetus may be able to compensate, eg. analbuminemia), rate of progression of primary mechanism (accelerated in second half of pregnancy by rapid fetal growth) and sufficient time for developing placental villous edema (impairs oxygen-nutrient transfer to the fetus). These modifying factors may have played a precipitating role in the genesis of hydrops in this case.

The hydrops fetalis case reported here apparently seems due to true umbilical cord knot that affected umbilical venous circulation during accelerated phase of fetal growth leading to this rare association. The main drawback of this case study was the failure in diagnosing the cause during antenatal period. This resulted loss of the opportunity to study fetoplacental blood flow dynamics with this condition. Hence, it is suggested that routine fetal ultrasound color Doppler study in idiopathic NIHF should be targeted for evaluation of umbilical cord knot. This may help in detecting as well as understanding the mechanism of non-immune hydrops fetalis in association of true cord knot in the future.

References

1. Holzgreve W, Curry RJC, Golbus SM et al. Investigation of NIHF. Am J Obstet Gynecol 1984;150:804-12.
2. Hutchison AA, Drew HJ, Yu HYV et al. NIHF: a review of 61 cases. Obstet Gynecol 1982;59:347-52.
3. Potter EL. Universal edema of fetus unassociated with erythroblastosis. Am J Obstet Gynecol 1943;46:130-4.
4. Maidman JR, Yeager C, Anderson V et al. Prenatal diagnosis and management of NIHF. Obstet Gynecol 1980;56:576.
5. Ballantyne JW. The diseases and deformities of the foetus, vol. 1 (Ballantyne JW ed.), Oliver and Boyd, Edinburgh, 1892.
6. Shenker L, Anderson W, Anderson C. Ultrasound demonstration of masses in a 15 week fetus: hydrops in a fetus with umbilical cord occlusion. Prenat Diagn 1981;1:217-21.
7. Joura EA, Zeisler H, Sator MO. Epidemiology and clinical value of true umbilical cord knots. Wien Klin Wochenschr 1998;110:232-5.
8. Airas U, Heinonen S. Clinical significance of true umbilical knots: a population-based analysis. Am J Perinatol 2002;19:127-32.
9. Camann W, Marquardt J. Images in clinical medicine. Complex umbilical-cord knot. N Engl J Med 2003;349:159.
10. Browne FJ. On abnormalities of umbilical cord which may cause antenatal death. J Obstet Gynecol Br Emp 1925;32:17-48.
11. Tuxen AJ, Permezal M, Walker SP, Georgiou HM. Factors affecting umbilical venous perfusion during experimental cord knotting. Placenta 2005;26:753-7.
12. Gembruch U, Baschat AA. True knot of the umbilical cord: transient constrictive effect to umbilical venous blood flow demonstrated by Doppler sonography. Ultrasound Obstet Gynecol 1996;8:53-6.
13. Aranyosi J, Major T, Fulesdi B, Zatik J. Fetal arterial redistribution indicating true umbilical cord knot. Eur J Obstet Gynecol Reprod Biol 2003;106:225-6.
14. Hoag RW. Fetomaternal hemorrhage associated with umbilical vein thrombosis. Am J Obstet Gynecol 1986;154:1271-4.
15. Barnes E, Bryan EM, Harris DA et al. Edema in the new born. Mol Aspects Med 1977;1:187-282.
16. Keeling JW. Hydrops fetalis and other forms of excess fluid collection in the fetus, in Textbook of Fetal & Perinatal Pathology (JS. Wigglesworth & D. Singer eds.), Blackwell Scientific Publications, Boston, pp 429-54 (1991).
17. Berg TG, Rayburn WF. Umbilical cord length and acid-base balance at delivery. J Reprod Med 1995;40:9-12.



www.journalagent.com

**Online manuscript
submissions
and peer review
(JournalAgent)**

Available at
J Turkish German Gynecol Assoc
www.jtgga.org