

# Uterine Artery Catheterisation and Selective Leiomyoma Embolization: Patient Acceptance and Clinical Outcome

Şahin ZETEROĞLU<sup>1</sup>, Eray ÇALIŞKAN<sup>2</sup>, Mustafa HARMAN<sup>3</sup>, Muzaffer ŞENGÜL<sup>4</sup>,  
Ebru COŞKUN<sup>2</sup>, Bülent TIRAŞ<sup>5</sup>, Mansur KAMACI<sup>6</sup>

<sup>1</sup>Department of Obstetrics and Gynecology, Faculty of Medicine, Mustafa Kemal University, Hatay, Turkey

<sup>2</sup>Department of Obstetrics and Gynecology, Faculty of Medicine, Kocaeli University, Kocaeli, Turkey

<sup>3</sup>Department of Radiodiagnostics, Faculty of Medicine, Ege University, İzmir, Turkey

<sup>4</sup>Universale Hospital, Obstetrics and Gynecology Clinic, Adana, Turkey

<sup>5</sup>Department of Obstetrics and Gynecology, Faculty of Medicine, Gazi University, Ankara, Turkey

<sup>6</sup>Department of Obstetrics and Gynecology, Faculty of Medicine, Yüzüncü Yıl University, Van, Turkey

Received 09 May 2006; received in revised form 04 March 2007; accepted 06 March 2007;  
published online 21 March 2007

## Abstract

**Objective:** To evaluate the patient acceptance and clinical outcome after selective uterine leiomyoma embolization.

**Materials and Methods:** Twenty-four women with symptomatic uterine fibroid were recruited for this study. Selective uterine leiomyoma embolization proceeded until complete vascular occlusion was achieved. The main outcome measure was the decrease in the leiomyoma volume and factors that predict it. Pearson correlation analysis and linear regression analysis were performed to identify possible correlates and predictors of decrease in leiomyoma volume. Patient satisfaction was assessed by asking the subjects to indicate their degree of satisfaction on a five-point scale.

**Results:** The mean age of the patients was 41.5±4.9 (Range: 28-52). The mean leiomyoma volume before the procedure was 157±214 cm<sup>3</sup> which was calculated to be 44±66 cm<sup>3</sup> with a 76±17% (Range: 30-99%) decrease in the mean leiomyoma volume at the end of one year. Correlation analysis revealed that only preoperative estradiol level was positively correlated with the extent of decrease in the leiomyoma volume ( $r=0.54$ ,  $p=0.005$ ). This was also proved in the regression analysis ( $\beta=0.25$ ,  $p=0.01$ ). During the follow-up 17 (70.8%) patients had complete remission of the symptoms, 5 (20.8%) had partial remission and 2 (8.3%) had no clinically significant change. Twenty patients (83.3%) were completely satisfied, 2 were satisfied and 2 were dissatisfied with the leiomyoma embolization procedure.

**Discussion:** There is a positive correlation between the preoperative estradiol level and the extent of the decrease in the leiomyoma volume after the embolization procedure. As leiomyoma is a hormone dependent tumor, the shrinkage of the leiomyoma seems also dependent on the estradiol levels before the procedure besides the incurred ischemic necrosis secondary to arterial embolization.

**Keywords:** leiomyoma, arterial embolization, clinical outcome, estradiol level

## Özet

### Uterin Arter Kateterizasyonu ve Seçici Leiomyom Embolizasyonu: Klinik Sonuçlar ve Hastalar İçin Kabul Edilebilirliği

**Amaç:** Leiomyom için uygulanan selektif uterin leiomyom embolizasyonu sonrasında klinik sonuçları ve hasta memnuniyetini değerlendirmek.

**Materyal ve Metot:** Semptomatik uterin leiomyomu olan yirmi dört hasta çalışmaya alındı. Tam vasküler oklüzyon elde edilene kadar selektif embolizasyona devam edildi. Saptanması planlanan ana sonuçlar, işlemden bir yıl sonraki leiomyom hacmindeki azalma ve bunu öngören faktörlerdi. Pearson korelasyon analizi ve lineer regresyon analizi leiomyom hacmindeki azalma ile ilişkili olası faktörleri ve prediktörleri belirlemek için kullanıldı. Hasta memnuniyeti, hastaların beş-nokta skalasında memnuniyet derecelerini işaretlemeleri istenerek belirlendi.

**Corresponding Author:** Dr. Şahin Zeteroğlu  
İnönü Cad. Şehoğlu Apt No: 6/3 31070 Antakya, Türkiye  
**Phone** : +90 326 215 85 78  
+90 326 214 86 61/247  
**E-mail** : szeteroglu@hotmail.com

**Sonuçlar:** Hastaların ortalama yaşı  $41.5 \pm 4.9$  (Dağılım aralığı: 28-52) idi. Prosedür öncesi ortalama leiomyom hacmi  $157 \pm 214 \text{ cm}^3$  iken, bir yılın sonunda  $44 \pm 66 \text{ cm}^3$  olan ortalama leiomyom hacminde  $\%76 \pm 17$ 'lik bir azalma (minimum-maksimum= $\%30-99$ ) bulundu. Korelasyon analizinde sadece preoperatif östradiol seviyesi leiomyom hacmindeki azalma ile pozitif ilişkili bulundu ( $r=0.54$ ,  $p=0.005$ ). Bu sonuç regresyon analizinde de kanıtlandı ( $\beta=0.25$ ,  $p=0.01$ ). Takiplerde 17 hastada ( $\%70.8$ ) semptomların tamamen düzeldiği, 5 hastada ( $\%20.8$ ) kısmi düzeldiği izlenirken, 2 hastada ( $\%8.3$ ) klinik olarak önemli bir değişiklik izlenmedi. Leiomyom embolizasyon prosedürü sonrası 20 hasta ( $\%83.3$ ) çok memnun olurken, 2 hasta memnun oldu ve 2 hasta ise hiç memnun olmadı.

**Tartışma:** Preoperatif östradiol seviyesi ve embolizasyon prosedürü sonrası leiomyom hacmindeki azalma arasında pozitif korelasyon bulunmaktadır. Leiomyom, hormon bağımlı olduğundan leiomyomun küçülmesinde kan akımının azalması ile oluşan iskemik nekroz kadar işlem öncesi östrojen hormon düzeyine de bağlı görünmektedir.

**Anahtar sözcükler:** leiomyom, arter embolizasyonu, klinik sonuçlar, östradiol seviyesi

## Introduction

Uterine leiomyomas are the most common benign tumors that arise from the smooth muscle cells of the female genital tract. Most leiomyomas cause no symptoms, but some women have significant symptoms such as abnormal uterine bleeding, pelvic pressure, pelvic pain, constipation, urinary disturbances, dyspareunia, and reproductive dysfunction (1). The currently available treatments for leiomyoma are less than ideal. The ideal conservative treatment for fibroids should eliminate symptoms, markedly reduce the size of the fibroids, limit recurrence of future fibroids and preserve fertility.

Uterine artery embolization (UAE) for the treatment of uterine myomas that cause abnormal menstrual bleeding was first reported by Ravina et al. in 1995 (2). UAE successfully controlled symptoms in 85-95% of patients for a median of 24 months. The leiomyomas undergo coagulative necrosis and eventually hyalinize (3). After this procedure uterine volume approximately decreases by 30% and the dominant fibroid volume decreases by 40-60% (4). Procedural complications due to UAE which are extremely uncommon (less than 1%) are hematoma, pseudoaneurysm, arteriovenous fistula, arterial thrombosis and infection. Post-procedural complications are postembolization syndrome (fever, malaise, leukocytosis), uterine ischemia and infarction, infection of necrotic fibroid, expulsion of fibroids and/or uterus, endometritis, pyosalpinx, menstrual irregularity, ovarian failure and premature menopause (5). Spies et al. reported 10% of minor complications and 1.25% of major complications in 400 women treated with uterine fibroid embolization (6).

We aimed to evaluate the patient acceptance and clinical outcome after selective uterine leiomyoma embolization together with possible predictors of the decrease in leiomyoma volume at one year after the procedure.

## Materials and Methods

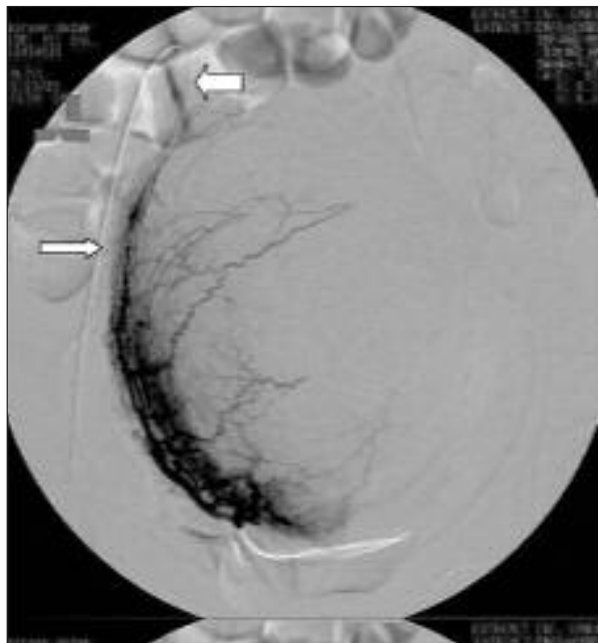For this study, 24 women with symptomatic uterine fibroid were recruited from Yüzüncü Yıl University Research Hospital in Van. The local institutional review board approved the research. Indications for selective uterine leiomyoma embolization (sULE) included heavy menstrual bleeding, pelvic pain or pressure caused by fibroids. Exclusion criteria included contraindications to angiography and embolization,

such as coagulopathy, pregnancy, pelvic inflammatory disease, diabetes mellitus, severe renal insufficiency, arteriovenous malformations, vasculitis and patients requiring pelvic surgery for concomitant conditions. These patients would have otherwise been candidates for surgical resection. All patients underwent pelvic ultrasonography (USG) and magnetic resonance imaging (MRI) to measure the diameter of the largest myoma, and the total uterine volume before selective uterine leiomyoma embolization sULE, most with the same observer (ŞZ) and equipment. Patients desiring future fertility were counseled about potential risk of sULE, including hysterectomy, radiation exposure and premature menopause. Alternative treatments were discussed. All women were seen in the research clinic at three-month intervals until one year post-procedure and had an ultrasonographic scan at each visit. The preoperative USG and MRI findings were compared with USG and MRI findings at one year after the procedure.

## The procedure

All women had a gynecological examination (performed by gynecologist) before sULE. The procedure, risks, indications, and alternatives were explained to the patient in detail by the interventional radiologist, after which informed consent was obtained both for the procedure and clinical trial. Pre-procedurally complete blood count, prothrombin time, partial thromboplastin time, and serum creatinine were assessed. The procedures were performed after cessation of menses in the late follicular or early luteal phase. As several patients had intermenstrual bleeding definitive dating for menorrhage was possible only with pathological evaluation.

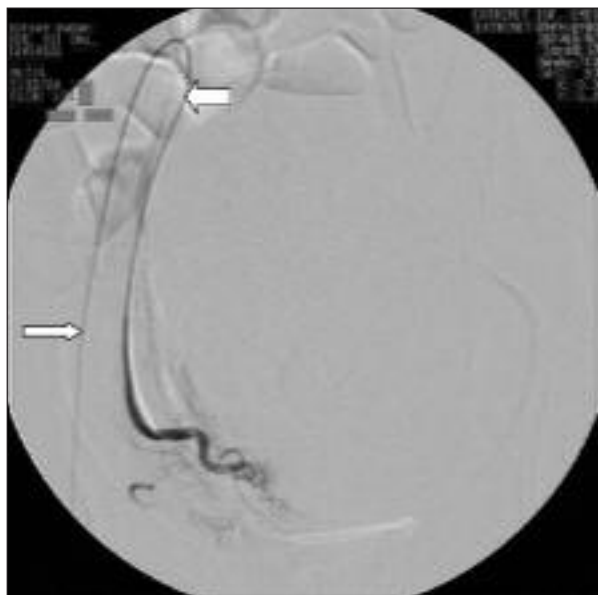
The procedure was performed in the angiography unit under conscious sedation, which was achieved with 50 mg pethidine (Aldolan, Liba, İstanbul, Turkey). All patients received prophylactic intravenous antibiotics, and ibuprofen 600 mg (Artil, Eczacıbaşı, İstanbul, Turkey) orally. Vascular access was obtained from a right common femoral arterial approach, and selective catheterization of uterine arteries was carried out with four or five French Cobra catheters, sometimes with four French Simons 2 catheters and arteries supplying the leiomyoma were found (Figure 1). The primary embolic agents were used polyvinyl alcohol particles (PVA) sized 355-500  $\mu\text{m}$  (contour; Tru-Fil; Cordis, Miami, FL). Selective embolization of arteries that nourish the leiomyoma proceeded until complete vascular occlusion was achieved (Figure 2). After



**Figure 1.** Uterine artery catheterization and visualizing the arterial supply of the leiomyoma. Thin arrow to the right: External iliac artery. Thick arrow to the left: Uterine artery.

the arteries were embolized a final arteriogram was obtained generally showing a residual flow to normal myometrial branches (Figure 2).

Patients were kept in bed resting for 12 hours after the procedure and then evaluated for possible discharge. At the completion of the procedure, all patients were given ibupro-



**Figure 2.** Selective embolization of the arteries supplying the leiomyoma. Thin arrow to the right: External iliac artery. Thick arrow to the left: Uterine artery.

phen 600 mg orally every six hours for a day. The patients were discharged on oral ibuprofen (600 mg 4 times daily) on demand. The main outcome measure was decrease in the leiomyoma volume and factors that predict it.

The statistical analysis of the data was performed using Statistical program for social sciences (SPSS 11.5, IL, USA). Mann Whitney U test was used to compare the mean decrease in the leiomyoma volume between cases at the end of one year from proliferative or secretory histological datings at the time of embolization. Pearson’s correlation analysis and linear regression analysis were performed to identify possible factors those of which correlate and predict the decrease in leiomyoma volume such as age, parity, preoperative leiomyoma volume, histological endometrial dating and preoperative estradiol levels.  $\chi^2$  test was used to compare categorical variables before and one year after the procedure. Wilcoxon test was used to compare continuous variables. The probability value  $p < 0.05$  was accepted to be statistically significant.

We assessed patient satisfaction by asking the subjects to indicate their degree of satisfaction on a five-point scale: 1- strongly dissatisfied, 2- dissatisfied, 3- neutral, 4- satisfied, 5- very satisfied. We asked patients to express their agreement to the statements below on a five point Likert scale: 1- strongly disagrees, 2- disagree, 3- neutral, 4- agree and 5-strongly agree. The statements were, “they can refer this procedure to another friend with leiomyoma” and “they would prefer another embolization procedure instead of surgery if the leiomyomas recur”.

## Results

The mean age of the patients was  $41.5 \pm 4.9$  (Range: 28-52). Four (16.6%) women were nulliparous. Twelve women were in the premenopausal period and 12 cases were in the reproductive age group without menopausal symptoms. The indications for the procedure included menometrorrhagia causing anemia and discomfort to the patient in 19 (79.1%) cases, pelvic pain in 1 case (4.1%) and both pain and irregular bleeding in 4 (16.6%) cases. Patients accepted the embolization procedure because 11 of them wanted to preserve their uterus, 11 of them were afraid of surgery and two of them found embolization procedure easier.

Catheterization of bilateral uterine arteries was achieved in 19 (79.1%) of the cases while only one uterine artery catheterization could be achieved in 5 cases. The mean procedure time was  $72.9 \pm 21.1$  minutes (Range: 30-120). Three cases had postoperative fever  $>38^\circ\text{C}$ , 7 (29.1%) had early severe abdominal cramping, eight (12.5%) had nausea and vomiting within 24 hours of the procedure. Eighteen patients (75%) recovered their daily activity 24 hours after the embolization.

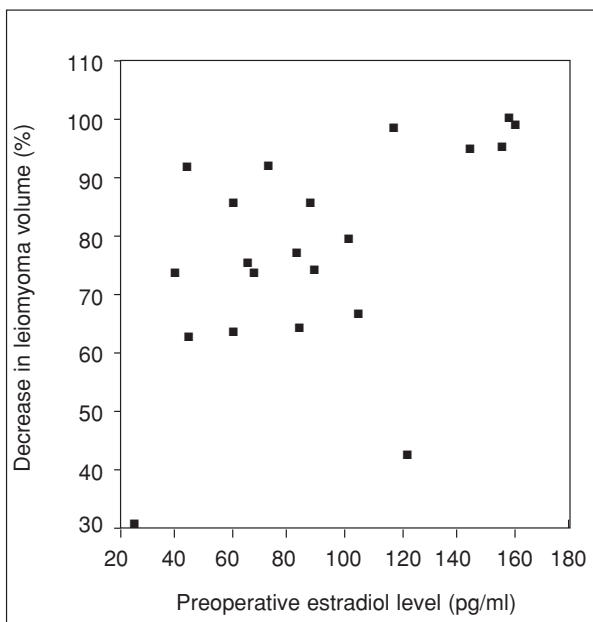
The mean leiomyoma volume before the procedure was  $157 \pm 214 \text{ cm}^3$  which was calculated to be  $44 \pm 66 \text{ cm}^3$  with a  $76 \pm 17\%$  (Range 30-99%) decrease in the mean leiomyoma volume at the end of one year. When magnetic resonance images were evaluated contrast of the leiomyomas were in-

creased in 7 (30.4%) cases, decreased in 7 (30.4%) cases and remained the same in 9 (39.1%) cases. Fourteen cases had secretory endometrial histology while ten cases had proliferative endometrial histology at the time of embolization and the mean decrease in leiomyoma volume were similar in the two groups ( $77\pm 21\%$  and  $73\pm 11\%$  respectively,  $p=0.2$ ).

Correlation analysis revealed that only preoperative estradiol level was positively correlated to the extent of decrease in the leiomyoma volume ( $r=0.54$ ,  $p=0.005$ ). This was also proved in the regression analysis that estradiol level could explain the decrease in leiomyoma volume ( $\beta=0.25$ ,  $p=0.01$ ). The decrease in leiomyoma volume with respect to preoperative estradiol level is given in Figure 3.

During the follow-up, 17 (70.8%) patients had complete remission of the symptoms, while 5 (20.8%) had partial remission and 2 (8.3%) had no clinically significant change. Twenty patients (83.3%) completely satisfied, 2 patients were satisfied and 2 patients were dissatisfied with the leiomyoma embolization procedure. Twenty-two patients (91.6%) completely agreed and 2 patients disagreed that they can refer this procedure to another friend with leiomyoma. Nineteen patients (79.1%) completely agreed, 3 agreed and 2 disagreed that they would prefer another embolization procedure instead of surgery if the leiomyomas recur.

Clinical evaluation of patient symptoms at the end of one year was presented in Table 1. Cycle length increased, bleeding time decreased, voiding frequency per day decreased, stress urinary incontinence decreased, constipation decreased, severe pelvic pain, dysparounia and dysmenorrhea decreased significantly one year after embolization.



**Figure 3.** The decrease in leiomyoma volume with respect to preoperative estradiol level.

**Table 1.** Clinical signs and symptoms before and one year after uterine leiomyoma embolization

Variable	Preoperative	One year after operation	p
Cycle length (day)	25±6.5	28±1.5	0.03
Bleeding time (day)	10.7±4.4	4.4±1.7	<0.001
Voiding per day	8.5±2.2	4.2±0.4	<0.001
Stres urinary incontinence	5 (20.8%)	0	0.03
Constipation	14 (58.3%)	4 (21.1%)	<0.001
Severe pelvic pain	15 (62.5%)	0	<0.001
Dysparounia	17 (70.8%)	0	<0.001
Severe dysmenorrhea	16 (66.7%)	0	<0.001
Mild dysmenorrhea	8 (33.3%)	16 (66.7%)	<0.001

## Discussion

Shrinkage of the leiomyomas and reduction in uterine volume have been used as measures of embolization efficacy. We found a  $76\pm 17\%$  (Range 30-99%) decrease in the mean leiomyoma volume at the end of one year. We found a positive correlation between the preoperative estradiol level and the extent of the decrease in the leiomyoma volume after the procedure.

Leiomyoma growth is dependent on hormones especially the estradiol. Studies have shown that leiomyomas have an abnormal gene expression that maintains high level of sensitivity to estradiol during the estradiol dominated proliferative phase of the menstrual cycle (3). In addition, cultured cells from leiomyomas have a significantly higher response to estradiol than do matched cultures of myometrial cells from the same patient, particularly if the tissue is taken for culture in the proliferative phase of the menstrual cycle (3). In our study the leiomyoma reduction extent did not differ between the two endometrial histology dating groups whether proliferative or secretory. As leiomyoma is a hormone dependent tumor, the shrinkage of the leiomyoma after sULE is also dependent on the estradiol hormone level besides hypoxia secondary to decreased blood supply rather than the leiomyoma size. A study has shown a consistent finding that the larger uterus does not decrease UAE's efficacy (7). On the contrary, it would be logical to assume that the larger leiomyomas might be more hormone dependent to grow that large and a greater decrease in their volume would occur as the estradiol supply to the cells is diminished.

Gonadotropin releasing hormone analogs (GnRHa) have been widely used for the treatment of leiomyoma and they cause pituitary desensitization by downregulation of GnRH receptors and decrease gonadal steroid production (8). Treatment with GnRHa for symptomatic leiomyoma has been observed to cause a reduction in uterine artery blood flow causing fibroid shrinkage an effect similar to that of sULE (9). The most striking microscopic feature after GnRHa treatment was coagulative necrosis (10). As the blood

supply to the leiomyoma was interrupted after uterine artery embolization, the leiomyoma underwent ischemic injury and coagulative necrosis, similar to the condition in sULE treatment. Estradiol is proven to increase myoma vascularity. Harman et al. showed that greater mass reduction occurred in leiomyomas with high pre-embolization vascularity (4). The pre-procedure hyperestradiolic state with increased pathological vascularity and high blood flow would lead to higher concentration of the embolic agent at this side after the selective uterine artery embolization procedure. On the other hand, semi-quantitative immunohistochemical demonstration of estradiol and progesterone receptors correlates with the growth rate of the myomas and in the group of patients treated with GnRHa it was shown that there was down-regulation of estradiol receptors (3). Treatment with GnRHa causes apoptosis of the smooth muscle cells (11). After sULE, pre-procedure estradiol available to the leiomyomas via blood stream declines sharply and this decrease, irrespective of the histological endometrial dating, may cause down-regulation of estradiol receptors and apoptosis of smooth muscle cells as seen after GnRHa treatment. In cases with higher pre-procedure levels of estradiol and higher pre-embolization vascularity, the decrease in the available blood and estradiol after embolization might cause a synergistic effect on the down-regulation of estradiol receptors and the extent of the decrease in the leiomyoma volume after sULE.

In our study, leiomyoma related symptoms decreased significantly after the sULE and the patient acceptance of the treatment was high with little complication rate, which was in agreement with the results of others (12). sULE is an effective, minimally invasive method of treating uterine

leiomyomas and reduces myoma related symptoms by producing significant volume reduction of both the leiomyomas and the uterus with high patient acceptance and tolerability. As shown here, the decrease in leiomyoma volume is more pronounced with higher preoperative estradiol levels.

## References

1. Stewart EA. Uterine fibroids. *Lancet* 2001;357(9252):293-8.
2. Ravina JH, Herbretreau D, Ciraru- Vigneron N et al. Arterial embolization to treat uterine myomata. *Lancet* 1995;346 (8976):671-3.
3. Robboy SJ, Bentley RC, Butnor K, Anderson MC. Pathology and pathophysiology of uterine smooth-muscle tumors. *Environ Health Perspect* 2000;108 (supp 5):779-84.
4. Harman M, Zeteroglu S, Sengul M et al. Uterine leiomyoma embolization: role of power Doppler ultrasonography. *Tani Girisim Radyol* 2003;9:240-5.
5. Sterling KM, Vogelzang RL, Chrisman HB et al. Uterine fibroid embolization: Management of complications. *Tech Vasc Interv Radiol* 2002; 5:56-66.
6. Spies JB, Spector A, Roth AR et al. Complications after uterine artery embolization for leiomyomas. *Obstet Gynecol* 2002;100:873-80.
7. Prollius A, de Vries C, Loggenberg E et al. Uterine artery embolization for symptomatic fibroids: the effect of the large uterus on outcome. *BJOG* 2004;111:239-42.
8. Crowley WF Jr. Gonadotropin releasing hormone and its analogues. *NEJM* 1991;324:93-103.
9. Shaw RW. Gonadotropin hormone-releasing hormone analogue treatment of fibroids. *Baillieres Clin Obstet Gynecol* 1998;12(2):245-68.
10. Colgan TJ, Pendergast S, LeBlanc M. The histopathology of uterine leiomyomas following treatment with gonadotropin-releasing hormone analogues. *Hum Pathol* 1993;24(10):1073-77.
11. Higashijima T, Kataoka A, Nishida T and Jakushiji M. Gonadotropin-releasing hormone agonist therapy induces apoptosis in uterine leiomyoma. *Eur J Obstet Gynecol Reprod Biol* 1996;68:169-73.
12. Worthington-Kirsch RL, Popky GL, Hutchins FL Jr. Uterine arterial embolization for the management of leiomyomas: quality-of-life assessment and clinical response. *Radiology* 1998 Sep;208(3):625-9.