

Laryngeal Atresia

Özlem PATA¹, Talat Umut Kutlu DİLEK¹, Filiz CAYAN¹, Ayşe POLAT², Ali NAYCI³, Saffet DİLEK¹

¹Department of Obstetrics and Gynecology, Faculty of Medicine, University of Mersin, Turkey

²Department of Pathology, Faculty of Medicine, University of Mersin, Turkey

³Department of Pediatric Surgery, Faculty of Medicine, University of Mersin, Turkey

Received 25 October 2006; received in revised form 19 December 2006; accepted 20 December 2006;
published online 20 February 2007

Abstract

Congenital laryngeal atresia is a rare abnormality and its prenatal diagnosis has been difficult. Recent advances in fetal ultrasonography, have allowed laryngeal atresia cases to be diagnosed prenatally. We describe an 18 week-old male fetus with bilateral enlarged echogenic lungs, dilated airways. This was associated with fetal ascites and suggested possible diagnosis of laryngeal atresia. After therapeutic abortion laryngeal atresia was also confirmed at the autopsy.

Keywords: laryngeal atresia, fetal ascites, dilated airways, echogenic lung

Özet

Laringeal Atrezi

Konjenital laringeal atrezi, prenatal tanısı güç olan nadir bir anomalidir. Ultrasonografi tekniğinde meydana gelen gelişmeler, laringeal atrezinin prenatal tanısına imkân vermektedir. Gebeliğin 18. haftasında yapılan ultrasonografik incelemede bilateral genişlemiş ekojenik akciğerler, dilate hava yolları saptanan erkek fetus tanımlanmıştır. Aynı zamanda asit de saptanan olgu, laringeal atrezi olarak değerlendirilmiştir. Terapötik abortus sonrası yapılan otopside, prenatal tanı doğrulanmıştır.

Anahtar sözcükler: laringeal atrezi, fetal asit, dilate hava yolları, ekojenik akciğerler

Introduction

Congenital high airway obstruction syndrome (CHAOS) is a clinical condition caused by complete or near complete obstruction of upper airway due to several etiologies such as laryngeal atresia, tracheal atresia and laryngeal cysts. Although prenatal ultrasonographic exam shows bilateral enlarged echogenic lungs, dilated airways and flattened or inverted diaphragms with associated fetal ascites and/or non-immune hydrops, the diagnosis of CHAOS is difficult (1). Balci et al. suggested that after the prenatal ultrasonography an investigation by a clinical geneticist is necessary and a postmortem examination by a pathologist-must differentiate it from cystic adenomatoid malformation (CAM) type III (2). We report here, an 18-week 3-day male fetus in whom prenatal sonography led to the possible diagnosis of laryngeal atresia or CAM type III and we discuss diagnosis and the specific clinical manifestation of CHAOS.

Case

A 23-year-old woman, gravida 1, para 0, was admitted to our clinic for anomaly-scanning. The menstrual age was 18 weeks and 2 days. Ultrasound examination showed that the fetus had massive ascites, bilateral symmetrically expanded hyper-echogenic lungs, dilated airways and inverted diaphragms (Figure 1). Internal tracheal diameter was 3.03 mm, measured from inner edge to inner edge, as described by Kalache et al. (3). The other organs and fetal echocardiography appeared normal. These findings were strongly suggestive of CHAOS with fetal hydrops caused by mediastinal compression with dilated lungs. Amniocentesis revealed a normal male karyotype.

After elective termination, the autopsy showed a male fetus, weighing 350 g, with gross edema of neck and trunk. No other external anomalies were detected. The lungs were pale and voluminous (Figure 2). There was type I laryngeal atresia. Laryngeal vestibule was represented by a shallow cleft. Below this reminder of the vestibule was replaced by mass of muscle. Infraglottic region was occluded by a dome-shaped cricoid (Figure 3). Histological examination of the lungs revealed marked interstitial edema and

Corresponding Author: Dr. Talat Umut Kutlu Dilek
Çamtepe Sitesi No: 28 Kuyuluk, Mersin, Türkiye
Phone : +90 533 384 42 64
E-mail : umutdilek@gmail.com

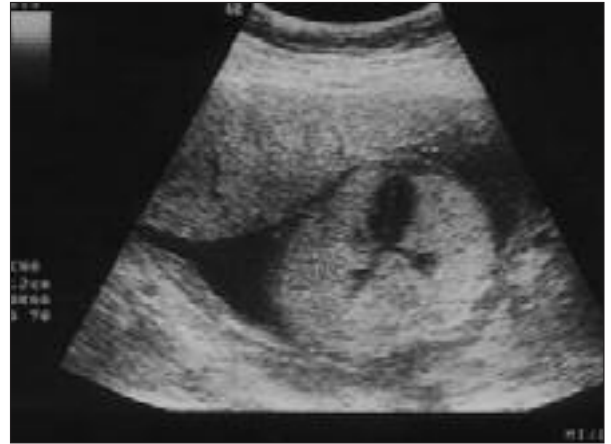
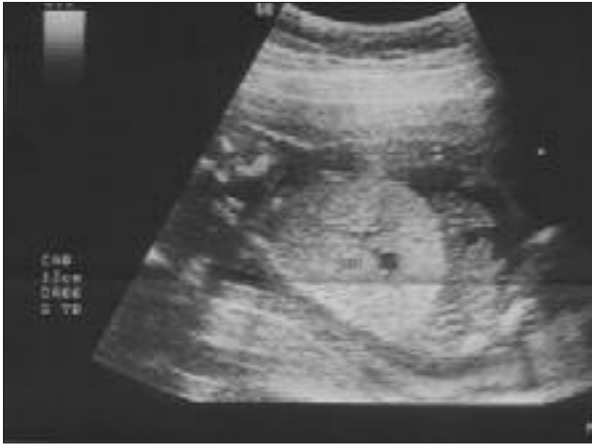
Figure 1. The fetus had massive ascites and inverted diaphragms (Figure 1a), bilateral symmetrically expanded hyperechogenic lungs, dilated airways (Figure 1b)s

striking distension of the developing airspaces. There was 50 cc of serous ascites. The esophagus and other organs were normal.

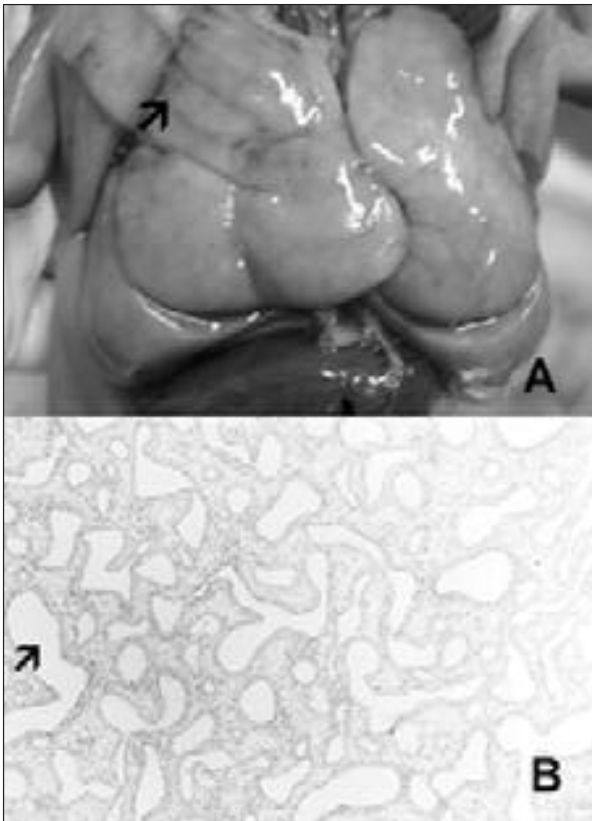


Figure 2. Anterior view of opened thorax and abdomen, shewing large pale lungs almost obscuring the heart and displacing the diaphragm downwards. Arrow shows costal impression on surface of the lung (A). Light photomicrography of lung shows marked dilatation of airspaces (arrow) with interstitial edema (H&E, x100).

Discussion

Recent advances in fetal ultrasonography, have allowed laryngeal atresia cases to be diagnosed antenatally. Changes caused by obstruction of larynx are indirect signs of laryngeal atresia. The fetal lungs require a continuous efflux of lung liquid. However, laryngeal obstruction causes the alveoli to become distended with lung fluid. Sonographic finding of bilateral symmetrically enlarged hyperechoic lungs, fluid filled dilated trachea are the reported consequences of this distension caused by laryngeal atresia (4,5). It is likely that the massive ascites is due to compression by the enlarged congested lungs on the heart, great vessels, and thoracic duct, preventing venous return (5). In some cases pressure on the oesophagus may cause decreased fetal swallowing of amniotic fluid and leading to polyhydramnios (5).

The improved diagnostic potential of ultrasonography has led to increased interest in the evaluation of fetal neck

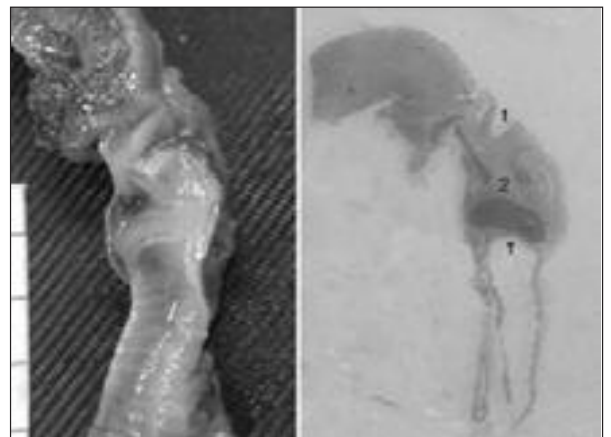


Figure 3. Macroscopic appearance of the larynx and trachea at necropsy (A). Sagittal section through larynx. Arrow indicates, cartilage bar (cricoid) occluded airway 1 indicates laryngeal vestibule, and 2 indicates masses of muscle (B) (H&E, x100).

structure. Kalache et al. examined ultrasound measurement of the fetal trachea, larynx and pharynx throughout gestation and their applicability to prenatal diagnosis of obstructive anomalies of the upper respiratory-digestive tract. They provided normograms for the tracheal, laryngeal and pharyngeal diameters during normal pregnancy. They suggested that among the measured structures, only the tracheal diameter would seem to be of clinical significance for the prenatal diagnosis of obstructive anomalies of the respiratory tract (3). They also demonstrated the absence of flow in trachea during fetal breathing movements so that they could position the exact level of atresia by using color Doppler sonography. On the other hand, it was suggested that tracheal diameter and absence of flow in the trachea during fetal breathing movements might be used to differentiate CHAOS from CAM (3,6). In our case, all indirect signs of laryngeal atresia were present. The tracheal diameter was larger than those of a normal fetus at the same gestational age (Mean +2SD=3.02 mm for 18 week).

Congenital laryngeal atresia is an extremely rare and frequently lethal condition. The exact cause of the laryngeal atresia is not known. Prenatal diagnosis of laryngeal atresia requires careful ultrasonographic evaluation, because affected infants may demonstrate variable malformations. Meizner et al. reported that 50% of cases involved other major malformations (5). Önderoğlu et al. reviewed the literature and showed 17 rare syndromes reported to be associated with laryngeal atresia such as Fraser syndrome, Di George syndrome (7). Although autosomal recessive or X-linked dominant genes can not be completely excluded, our case had no family history of congenital abnormality and no other malformations or chromosomal abnormalities, suggesting a presumably sporadic etiology.

Generally, the natural course of a fetus with isolated laryngeal atresia is thought to be poor and a lot of intrauterine deaths have been reported (8,9). Prognosis is much more favorable should any communication through the obstructed airway develop to allow release of fetal lung fluid and intrathoracic pressure such as trachea-oesophageal fistula. Several attempts were made for the management of CHAOS prenatally. Fetoscopic and ultrasound guided decompression of the fetal trachea have been successfully attempted in CHAOS from laryngeal atresia and permitted normalization of hemodynamics in hydropic human fetuses (10). *Ex utero*

intrapartum treatment (EXIT) procedure involving a planned tracheostomy allows fetal interventions to be applied while maintaining placental blood circulation to the fetus. Several CHAOS were delivered successfully by EXIT procedure to date (9). However even if they survive the acute phase, the appropriate treatment for patients with CHAOS is still controversial and the timing and method of airway reconstruction does not currently exist (8). In this case, presence of laryngeal atresia and massive generalized ascites were determined as poor prognostic factors. Therefore, therapeutic abortion was chosen as an option.

In conclusion, the identification of laryngeal atresia in fetus is difficult, but technically possible. In addition, the natural history of the syndrome remains poorly understood and the experience to define proper perinatal management of the fetus with laryngeal atresia is not sufficient.

References

1. Hedrick MH, Ferro MM, Filly RA et al. Congenital high airway obstruction syndrome (CHAOS): A potential for perinatal intervention. *J Pediatr Surg* 1994;29:271-4
2. Balci S, Altınok G, Ozaltın F et al. Laryngeal atresia presenting as fetal ascites, oligohydramnios and lung appearance mimicking cystic adenomatoid malformation in a 25-week-old fetus with Fraser syndrome. *Prenat Diagn* 1999;19:856-8.
3. Kalache KD, Franz M, Chaoui R, Bollmann R. Ultrasound measurements of the fetal trachea, larynx and pharynx throughout gestation and applicability to prenatal diagnosis of obstructive anomalies of the upper respiratory-digestive tract. *Prenat Diagn* 1999;19:211-8.
4. Watson WJ, Thorp JM Jr, Miller RJ. Prenatal diagnosis of laryngeal atresia. *Am J Obstet Gynecol* 1990;163:1456.
5. Meizner I, Sherizly I, Mashlach R et al. Prenatal sonographic diagnosis of laryngeal atresia in association with single umbilical artery. *J Clin Ultrasound* 2000;28:435-8.
6. Kalache K, Chaoui R, Tennstedt C, Bollmann R. Prenatal diagnosis of laryngeal atresia in two cases of congenital high airway obstruction syndrome (CHAOS). *Prenat. Diagn.* 1997;17:577-81.
7. Önderoğlu L, Karamürsel SB, Bulun A et al. Prenatal diagnosis of laryngeal atresia. *Prenat Diagn* 2003;23:277-80.
8. Kanamori Y, Kitano Y, Hashizume K et al. A case of laryngeal atresia (Congenital high airway obstruction syndrome) with chromosome 5p deletion syndrome rescued by ex utero intrapartum treatment. *J Pediatr Surg* 2004; 39:25-9.
9. Lim FY, Crombleholme TM, Hedrick HL et al. Congenital High Airway Obstruction Syndrome: Natural History and Management. *Pediatr Surg.* 2003;38:940-5.
10. Kohl T, Hering R, Bauriedel G et al. Fetoscopic and ultrasound-guided decompression of the fetal trachea in a human fetus with Fraser syndrome and congenital high airway obstruction syndrome (CHAOS) from laryngeal atresia. *Ultrasound Obstet Gynecol.* 2006;27:84-8.