

Squamous Cell Carcinoma Arising from Mature Cystic Teratoma of the Ovary in a 28-year-old Woman

Elif Aylin TAŞKIN, Salih TAŞKIN, Aslı YARCI, Bora CENGİZ, Mete GÜNGÖR

Department of Obstetrics and Gynecology, Faculty of Medicine, Ankara University, Ankara, Turkey

Received 02 October 2006; received in revised form 03 November 2006; accepted 03 November 2006

Abstract

Malignant transformation in mature cystic teratoma occurs very rarely (2%), its incidence increases with age reaching the highest level in postmenopausal period.

A case of squamous cell carcinoma arising from mature cystic teratoma in a 28-year-old woman, one of the few youngest cases reported, and her treatment with fertility sparing surgery is presented.

Young age is not a guard from malign transformation arising from mature cystic teratoma; therefore clinician must be aware of this risk. Intraoperative frozen section examination may be beneficial to guide the extent of surgery. Fertility sparing surgery may be preferred in young patients desiring fertility.

Keywords: malign transformation, mature cystic teratoma, young patient

Özet

Yirmi Sekiz Yaşındaki Genç Hastada Matür Kistik Teratomdan Köken Alan Skuamöz Hücreli Karsinom

Matür kistik teratomda malign transformasyon oldukça nadir olup (%2), bu risk yaş ile beraber artarak, en yüksek insidans postmenopozal dönemde görülür.

Matür kistik teratomda malign transformasyon saptanan ve rapor edilmiş birkaç genç hastadan biri olan, 28 yaşındaki olgu ve ona uygulanan fertilitte koruyucu tedavisi sunulmuştur.

Genç yaş, malign transformasyon için bir engel teşkil etmez ve klinisyen bu konuda dikkatli olmalıdır. İntraoperatif frozen-kesit incelemesi cerrahinin boyutunu belirlemede yararlı olabilir. Fertilitte koruyucu cerrahi, fertilitte arzusu olan hastalarda önerilebilir.

Anahtar sözcükler: malign transformasyon, matür kistik teratom, genç hasta

Introduction

Mature cystic teratoma (MCT) of the ovary, well known as a benign tumor, accounts for 10-20% of all ovarian neoplasms. Malignant transformation (MT) of its components occurs very rarely (2%), with squamous cell carcinoma (SCC) being the most common (approximately 80%) followed by adenocarcinoma, and carcinooids (1-4). MT confers an extremely poor prognosis and differing from ordinary germ cell tumors of the ovary, its incidence increases with age reaching the highest level in postmenopausal period (2,3).

In this report, a case of SCC arising from MCT in a 28-year-old woman and her treatment with fertility sparing surgery is reported.

Case

A 28-year-old multipara was referred to our clinic due to adnexal mass. Pelvic examination confirmed the presence of a large immobile pelvic mass with regular contours extending up to umbilicus. Transvaginal ultrasound demonstrated a right ovarian tumor measuring 146x103x96 mm, normal looking uterus and left ovary, and absence of ascites. Ultrasonographic appearance of the tumor was suggestive of MCT with heterogeneous solid echo and calcifications. The patient's tumor marker profile was as follows: CA-125: 26.23 U/ml (normal <30 U/ml), CA 19-9: 240 U/ml (normal <36.2 U/ml), AFP:1.5 ng/ml (normal <5 ng/ml).

Corresponding Author: Dr. Salih Taşkın
Ankara Üniversitesi Tıp Fakültesi
Kadın Hastalıkları ve Doğum AD,
Cebeci 06100 Ankara, Türkiye
GSM : +90 532 392 51 95
E-mail : salihtaskin@yahoo.com

At laparotomy there was a right ovarian solid mass measuring 140x100x100 mm grossly consistent with MCT. Other pelvic and abdominal organs were free of disease macroscopically. After obtaining peritoneal washing for cytological evaluation, the mass was removed intact as right salpingo-oophorectomy. The frozen-section diagnosis was MCT with a focus of SCC. Taking the patient's age into account, fertility sparing surgery was decided, and right pelvic and para-aortic lymph node dissection, wedge biopsy of the contralateral ovary, omentectomy and appendectomy were performed.

Pathological evaluation demonstrated MCT including a focus of SCC (Figure 1), infiltrating but not extending beyond the tumor capsule. No other malignant focus was defined in the surgical specimen and peritoneal cytology was negative. As the tumor was FIGO stage Ia, no adjuvant therapy was planned.

The patient is under follow-up for 18 months and disease-free until now.

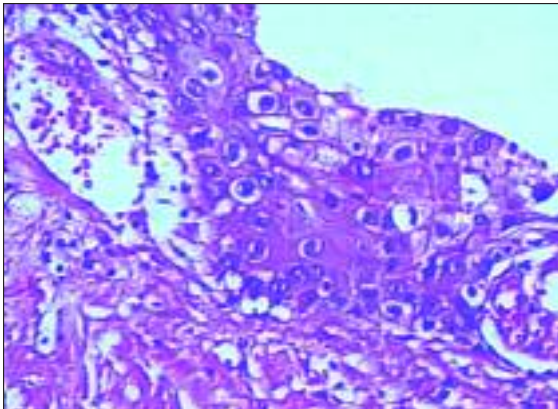


Figure 1. The focus of *in situ* carcinoma in the lining epithelium (HE, x400)

Discussion

Ovarian SCCs are extremely rare; mostly arise from MCT, with a peak incidence at advanced ages. The mean age of 37 SCC in MCT cases reported by Kikkawa et al. was 55.2 years (5). Similarly, Chadha and Schaberg reported 18 SCC cases among 24 cases of MCT with MT whose average age was 55 with 81% being over 50 years (4). This case, who was only 28 years old at time of diagnosis, is one of the few youngest cases reported.

Generally MT in MCT confers an extremely poor prognosis (2). The stage (3) and mode of infiltration (2) were propounded as the most important prognostic factors. Most survivors are the ones with disease confined to the ovary (FIGO Stage I), especially the ones without capsular invasion, but prognosis is very poor when the disease has spread beyond the ovary.

Pre- and intraoperative diagnosis is especially important to decide the extent of surgery, especially if the future fertility is desired. Kikkawa et al. suggested serum SCC-antigen and CEA level measurements if the patient is older than 44-years and the tumor is larger than 10 cm (5). Suzuki et al. proposed M-CSF as a useful tumor marker to discriminate MCTs with MT especially when used in combination with squamous cell antigen (SCA) (1). However no tumor marker has been confirmed to be absolutely predictive and specific for MT in MCT. A careful frozen section examination with adequate sampling performed by an experienced pathologist provides a useful guide to designate the extent of surgery, which is especially important in young patients desiring to retain fertility. Although extremely elevated CA 19-9 level in MCT lacking any malignant focus was reported previously (6), in this patient high CA 19-9 level and large tumor size arose the suspicion of MT, therefore frozen section was planned and the extent of the operation was designated accordingly.

An effective standard therapy for SCC in MCT has not been established due to its rarity (2). However comprehensive staging was recommended, as for the other ovarian tumors. On the other hand, fertility sparing surgery has been advocated for some early stage epithelial and germ cell tumors of the ovary in young patients (7). Also, stage Ia patients with SCC in MCT (such as this case) were reported to have good prognosis with 85% survival (4). Taking the patient's age and fertility desire into account, the contralateral ovary and the uterus were left in place in this patient. Adjuvant chemo- or radiotherapy was also reported to have not much to offer in improving the survival (4), therefore no adjuvant therapy was planned for this patient.

A standard surgical procedure for SCC in MCT has not been established, yet. As while as in 4.9% of early stage ovarian cancer has appendix metastasis, appendectomy is proposed for all epithelial ovarian carcinoma patients as a part of the initial surgical staging procedure (8). Contralateral ovarian biopsy should be done to exclude occult disease in the normal appearing ovary (9). Although contralateral lymph node dissection in stage I ovarian carcinoma is not suggested by some reports (10), this issue is controversial (11).

In conclusion, young age is not a guard from MT arising from MCT; therefore clinician must be aware of this risk. Although their diagnostic value has not been established yet, SCC-antigen, M-CSF and CEA may be used for preoperative risk assessment. Intraoperative frozen section examination may be very beneficial to guide the extent of the surgery. Fertility sparing surgery may be preferred in young patients desiring to retain fertility.

References

1. Suzuki M, Tamura N, Kobayashi H et al. Clinical significance of combined use of M-CSF and squamous cell carcinoma antigen as a selective diagnostic marker for squamous cell carcinoma arising in mature cystic teratoma of the ovary. *Gynecol Oncol* 2000;77:405-9.
2. Spanuth WA, Rocconi RP, Kirby TO et al. Gamma mode of infiltration associated with poor prognosis in malignant teratoma of the ovary: a case report. *Gynecol Oncol* 2005;98:155-7.

3. Powell JL, Stinson JA, Connor P et al. Squamous cell carcinoma arising in a dermoid cyst of the ovary. *Gynecol Oncol* 2003;89:526-8.
4. Chadha S, Schaberg A. Malignant transformation in benign cystic teratomas: dermoids of the ovary. *Eur J Obstet Gynecol Reprod Biol* 1988;29: 329-38.
5. Kikkawa F, Nawa A, Tamakoshi K et al. Diagnosis of squamous cell carcinoma arising from mature cystic teratoma of the ovary. *Cancer* 1998;82: 2249-55.
6. Atabekoglu C, Bozacı EA, Tezcan S. Elevated carbohydrate antigen 19-9 in a dermoid cyst. *Int J Gynaecol Obstet* 2005;91:262-3.
7. Gershenson DM. Fertility sparing surgery for malignancies in women. *J Natl Cancer Inst Monogr* 2005;34:43-7.
8. Ayhan A, Gultekin M, Taskiran C, Salman MC, Celik NY, Yuce K, Usubatun A, Kucukali T. Routine appendectomy in epithelial ovarian carcinoma: is it necessary? *Obstet Gynecol* 2005;105:719-24.
9. Benjamin I, Morgan MA, Rubin SC. Occult Bilateral Involvement in Stage I Epithelial Ovarian Cancer. *Gynecol Oncol* 1999;72:288-91.
10. Benedetti-Panici P, Greggi S, Maneschi F et al. Anatomical and pathological study of retroperitoneal nodes in epithelial ovarian cancer. *Gynecol Oncol* 1993;51:150-4.
11. Negishi H, Takeda M, Fujimoto T et al. Lymphatic mapping and sentinel node identification as related to the primary sites of lymph node metastasis in early stage ovarian cancer. *Gynecol Oncol* 2004;94:161-6.

