

Hysteroscopic Balloon Technique for Correction of the Complete Uterine Septum

Yusuf ÜSTÜN, Yaprak ENGİN ÜSTÜN, M. Mutlu MEYDANLI, Ruşen ATMACA, Ayşe KAFKASLI

Department of Gynecology and Obstetrics, Faculty of Medicine, İnönü University, Malatya, Turkey

Received 01 November 2005; received in revised form 14 April 2006; accepted 03 August 2006

Abstract

Cervical duplication with a longitudinal vaginal septum and a complete uterine septum is a congenital malformation rarely encountered in general gynecology practice. A 25-year-old nulliparous woman presenting with a complaint of dyspareunia and desiring to conceive was referred for evaluation. A longitudinal vaginal septum and septate uterus with double cervix was diagnosed by combined hysteroscopy and laparoscopy. After the excision of the complete longitudinal vaginal septum, corporal part of a complete uterine septum was hysteroscopically perforated using electrocautery by the help of a balloon introduced into the second cavity and then incised with no problems. The septum was spared below the internal cervical os.

Keywords: septate uterus, double cervix, hysteroscopy

Özet

Komplet Uterin Septumun Düzeltmesinde Histeroskopik Balon Tekniği

Longitudinal vajinal septum, komplet uterin septum ve servikal duplikasyon jinekoloji pratiğinde nadir görülen bir konjenital malformasyondur. Dispareni şikâyeti ve çocuk istemiyle başvuran 25 yaşında nullipar hastamızda muayene, histeroskopi ve laparoskopi yoluyla longitudinal vajinal septum, uterin septum ve çift serviks tespit edildi. Komplet longitudinal vajinal septum eksiye dildikten sonra, komplet uterin septumun korporal bölümü ikinci kaviteye yerleştirilen balon kılavuzluğunda elektrokoter ile histeroskopik olarak çıkarıldı. Septum, internal servikal osun altında korundu.

Anahtar sözcükler: uterin septum, çift serviks, histeroskopi

Introduction

The incidence of congenital uterine anomalies in the general population is estimated to be 0.001-10%. Septate and arcuate uteri represent approximately 75% of Müllerian abnormalities (1). The cause of most congenital uterine abnormalities is due to the improper development and fusion of the embryonic Müllerian ducts. Although cervical duplication with a longitudinal vaginal septum and a complete uterine septum is a congenital malformation rarely encountered in general gynecology practice, it is probably more frequent than thought since there are over 50 cases reported in the literature (2-15).

Structural genital malformations may be associated with recurrent pregnancy loss, pre-term labor, abnormal fetal presentation and infertility (16).

Here, we report the operative management of cervical duplication with a longitudinal vaginal septum and a complete uterine septum.

Case Report

A 25-year-old nulliparous woman presenting with the complaint of dyspareunia and desiring to conceive was referred for evaluation. A longitudinal vaginal septum (Figure 1) and the presence of 2 separate cervixes (Figure 2) were seen on speculum examination. The position of the left cervix was superior and the right cervix was inferior to the horizontal axis of the vagina. No urinary anomalies were established.

A longitudinal vaginal septum and bicervical septate uterus was also diagnosed by combined hysteroscopy and laparoscopy. The vaginal septum was removed at the time of hysteroscopy. Resection of the longitudinal vaginal septum was

Corresponding Author: Dr. Yusuf Üstün
İnönü Üniversitesi Tıp Fakültesi Lojmanları T23/2
44069 Malatya, Türkiye
Phone : +90 422 341 06 60/1602
E-mail : ustuny@hotmail.com

The abstract of this study was presented as poster presentation in 6th, International Congress of The Turkish-German Gynecological Association, 19-22 May 2005, Antalya

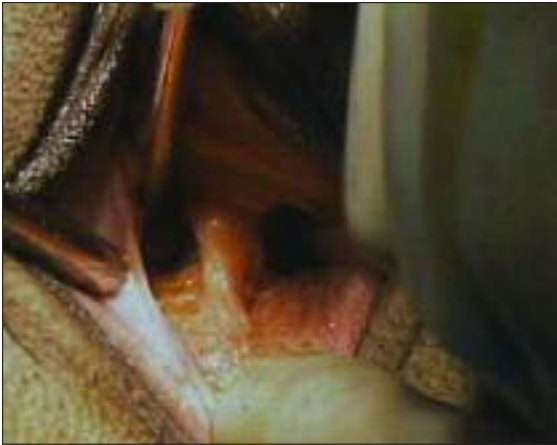

Figure 1. Complete longitudinal vaginal septum

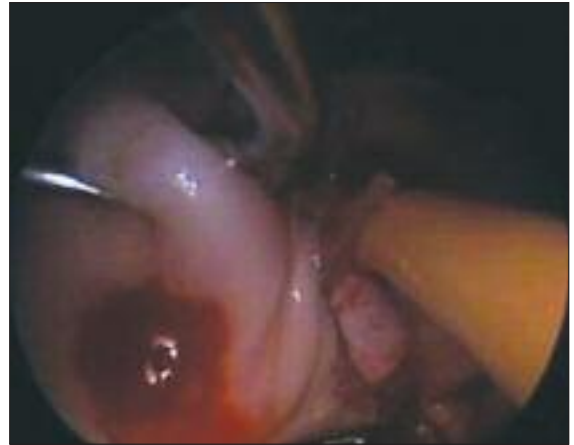

Figure 2. Two separate cervixes with Foley catheter in the left orifice

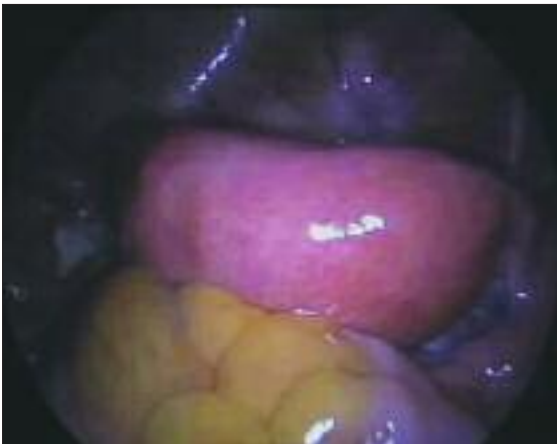

Figure 3. Laparoscopic view: Broad-based uterine fundus

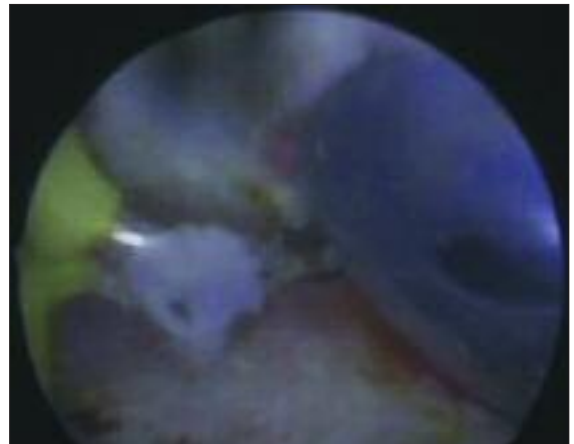


Figure 4. Appearance of the balloon during septum incision

performed using the classical surgical procedure widely described in textbooks (17): excision by scissors after the application of two Kelly or Kocher forceps to prevent any blood loss. The edges were sutured for hemostasis with 3-0 absorbable sutures. Laparoscopy excluded the diagnosis of a uterus didelphys or other bicornuate uterine malformations that present with a duplicated cervix (Figure 3).

After the excision of the complete longitudinal vaginal septum, a pediatric Foley catheter was inserted into the second cavity and inflated to distend the septum. With a non-ionic distention medium, the corporal part of the complete uterine septum was incised with an operative hysteroscope using electrocautery (Figure 4). The septum was spared below the internal cervical os. Blood loss was negligible.

Following treatment, the patient has not yet achieved pregnancy.

Discussion

Septate uterus is the most frequent cause of congenital uterine anomalies (1). Cervical duplication with a longitudinal vaginal septum and a complete uterine septum challenges the classic embryological teaching on the fusion of the unidirectional caudad to cephalad Müllerian ducts but fits an alternative embryologic hypothesis of Müller et al. (18), according to whom fusion and resorption begins at the isthmus and proceeds simultaneously in both the cranial and caudal directions and results with a normal uterine fundus, a complete septum, cervical duplication, and a longitudinal vaginal septum.

Presenting complaints can be pregnancy loss in parous women and dyspareunia in nulligravid women (14). Cases of complete uterine and vaginal septum can be easily confused with uterus didelphys (10,14).

The options for surgical repair of the septate uterus with either a single or double cervix include both transabdominal and hysteroscopic approaches. Laparoscopy can be performed in patients to confirm the diagnosis and assist in the planned hysteroscopic repair.

Patton et al have identified and treated a total of 16 cases representing one of the largest reported series to date (14). As in our case, in Patton's series the cervical portion of the septum (i.e. the fused medial junction of the double cervix) was conserved because of concerns for problematic bleeding and future cervical incompetence. Saygılı et al reported 9 cases, which suggest that this atypical septate uterus type is probably more frequent than reported. These cases support the bidirectional Müllerian theory and may imply the presence of another type of Müllerian anomaly (15).

We performed resection of the longitudinal vaginal septum using the classical surgical procedure. Montevecchi described the endoscopic technique used to treat cases of complete longitudinal vaginal septum (19). We then inserted a pediatric Foley catheter into the second cavity and inflated to distend the septum. With a non-ionic distention medium, the corporal part of the complete uterine septum was incised with an operative hysteroscope using electrocautery. This technique using a balloon provided a safe and identifiable surface above the cervix, where the resection could be initiated. This technique was also used by Römer and Lober (20). Once a passage was created, the resection was completed in the usual fashion with sparing of the tissue in the cervix.

Complete septate uterus with longitudinal vaginal septum is not associated with primary infertility. Duffy et al advocated not resecting the uterine septum because of risk for cervical competence and reported a patient who delivered a full-term infant after only resecting the vaginal septum (21). Heinonen et al stated that their results did not support elective hysteroscopic incision of the septum in asymptomatic patients or before first pregnancy (7).

Because this Müllerian duct malformation is rare and optimal management is unknown, patients with this anomaly who have a history of a poor reproductive outcome may benefit from this technique.

References

1. Acien P. Incidence of Müllerian defects in fertile and infertile women. *Hum Reprod* 1997;12:1372-6.
2. Wai CY, Zekam N, Sanz LE. Septate uterus with double cervix and longitudinal vaginal septum. A case report. *J Reprod Med* 2001;46:613-7.
3. Fatum M, Rojansky N, Shushan A. Septate uterus with cervical duplication: rethinking the development of müllerian anomalies. *Gynecol Obstet Invest* 2003;55:186-8.
4. Garcia Leon F, Kably-Ambe A, Von der Meden W et al. Septate uterus with cervical duplication and vaginal partition: a rare malformation. *Ginecol Obstet Mex* 1998;66:489-91.
5. McBean JH, Brumsted JR. Septate uterus with cervical duplication: a rare malformation. *Fertil Steril* 1994;62:415-7.
6. Chang AS, Siegel CL, Moley KH et al. Septate uterus with cervical duplication and longitudinal vaginal septum: a report of five new cases. *Fertil Steril* 2004 Apr;81(4):1133-6.
7. Heinonen PK. Complete septate uterus with longitudinal vaginal septum. *Fertil Steril* 2006;85:700-5.
8. Giraldo JL, Habana A, Duleba AJ, Dokras A. Septate uterus associated with cervical duplication and vaginal septum. *J Am Assoc Gynecol Laparosc* 2000;7:277-9.
9. Balasch J, Moreno E, Martinez-Roman S et al. Septate uterus with cervical duplication and longitudinal vaginal septum: a report of three new cases. *Eur J Obstet Gynecol Reprod Biol* 1996;65:241-3.
10. Sharara FI. Complete uterine septum with cervical duplication, longitudinal vaginal septum and duplication of a renal collecting system. A case report. *J Reprod Med* 1998;43:1055-9.
11. Ergun A, Pabuccu R, Atay V. Three sisters with septate uteri: another reference to bidirectional theory. *Hum Reprod* 1997;12:140-2.
12. Lev-Toaff AS, Kim SS, Toaff ME. Communicating septate uterus with double cervix: a rare malformation. *Obstet Gynecol* 1992;79:828-30.
13. Hundley AF, Fielding JR, Hoyte L. Double cervix and vagina with septate uterus: an uncommon müllerian malformation. *Obstet Gynecol* 2001;98:982-5.
14. Patton PE, Novy MJ, Lee DM, R. Hickok LR. The diagnosis and reproductive outcome after surgical treatment of the complete septate uterus, duplicated cervix and vaginal septum. *Am J Obstet Gynecol* 2004;190:1669-75.
15. Saygılı-Yılmaz ES, Erman-Akar M, Bayar D et al. Septate uterus with a double cervix and longitudinal vaginal septum. *J Reprod Med* 2004;49:833-6.
16. Heinonen PK, Saarikoski S, Pystynen P. Reproductive performance of women with uterine anomalies. *Acta Obstet Gynecol Scand* 1982;61:157-60.
17. J.A. Rock. Surgery for anomalies of the Müllerian ducts. In: J.A. Rock and J.D. Thompson, Editors, *Te Linde's operative gynecology* (8th ed.), Lippincott-Raven, Philadelphia 1997, pp. 687-729.
18. Muller P, Musset R, Netter A et al. State of the upper urinary tract in patients with uterine malformations. *Presse Med* 1967;75:1331-6.
19. Montevecchi L, Valle RF. Resectoscopic treatment of complete longitudinal vaginal septum. *Int J Gynecol Obstet* 2004;84:65-70.
20. Römer T, Lober R. Hysteroscopic correction of a complete septate uterus using a balloon technique. *Hum Reprod* 1997;12:478-9.
21. Duffy DA, Nulsen J, Maier D et al. Septate uterus with cervical duplication: a full-term delivery after resection of a vaginal septum. *Fertil Steril* 2004;81:1125-6.