

A New, Non-compensatory Colpopexy Technique for Stage IV POP: Long-term Clinical Outcomes

Adam OSTRZENSKI

The Department of Obstetrics and Gynecology, University of South Florida, Tampa, Florida, USA

Received 24 May 2006; received in revised form 26 July 2006; accepted 22 August 2006

Abstract

Objective: To analyze and report results of long-term clinical outcomes of non-compensatory colpopexy in women associated with stage IV POP.

Materials and Methods: This was a prospective comparative cohort study of 27 women with stage IV POP.

The control group I included 16 women and the interventional group II included 11 subjects. In group I, 3 anatomical levels and in group II, 4 anatomical levels of pelvic defects were repaired. No other concomitant surgery was performed. Postoperatively, all subjects were followed-up annually from February 1996 to February 2006. The POP-Q classification and the UDI were utilized for evaluation. The primary outcome measure was POP recurrence and secondary outcome measure was to determine occurrence of urinary incontinence, dyspareunia, changes in libido and changes in frequency of coital events. Statistical analysis was performed with an χ^2 test, a Student *t* test, and 2-sided Fisher test.

Results: Preoperatively in both groups, subjects reported the presence of superficial and/or deep dyspareunia, decreased libido and low number coital events (\dagger 1 coital event per month). The group I had statistically significant higher POP recurrence ($P=0.004$), one case of mixed urinary incontinence; overall improvement of dyspareunia, libido and the frequency of coital events were documented. In the group II, the cured rate of POP was 91% ($P=0.004$) and 9% recurrent stage III POP was noted; no urinary incontinence had occurred; dyspareunia was cured in all cases and libido, and the number of coital events improved significantly ($P=0.001$).

Conclusion: 1. In the interventional group, the cure rate was statistically significant higher and no urinary incontinence occurred, dyspareunia, libido, and the number of coital events improved significantly. 2. Reconstructing all defects in all four anatomical levels provided optimal outcomes of the surgery.

Keywords: colpopexy, non-compensatory colpopexy, colposuspension, pelvic organ prolapse, site-specific pelvic reconstruction, non-compensatory pelvic reconstruction, total vaginal prolapse, laparoscopic surgery

Özet

Evre IV POP İçin Geliştirilen Yeni Bir Kolpopeksi Tekniği: Uzun Vadeli Klinik Sonuçlar

Amaç: Evre IV POP hastalarında non-kompensatuar kolpopeksi tekniğinin uzun vadeli klinik sonuçlarını analiz etmek ve sunmak.

Materyal ve Metot: Evre IV POP bulunan 27 hastada prospektif karşılaştırmalı kohort bir çalışma tasarlandı. Kontrol grubu (Grup I) 16 hastayı, çalışma grubu (Grup II) 11 hastayı kapsamaktaydı. Grup I'de pelvik defektler 3 anatomik seviyede, Grup II'de ise 4 anatomik seviyede onarıldı. Ek tamamlayıcı bir cerrahi işlem yapılmadı. Postoperatif dönemde hastaların tamamı Şubat 1996'dan Şubat 2006'ya kadar takip edildiler. Değerlendirme için POP-Q sınıflandırması ve UDI kullanıldı. Birincil derecede çalışmada POP rekürrensi, ikincil derecede çalışmada üri-ner inkontinans, dispanoni, libidoda ve koital sıklıktaki değişiklikler değerlendirildi. İstatistiksel analiz χ^2 testi, Student-*t* testi ve 2 yönlü Fisher testi ile yapıldı.

Sonuç: Preoperatif her iki grupta da yüzeysel veya derin dispanoni, azalmış libido ve koital sıklık (\dagger 1 koit/ay) mevcuttu. Grup I'de POP rekürrensi ($P=0.004$) anlamlı derecede fazlaydı; bir vakada miiks üri-ner inkontinans ortaya çıktı. Bu grupta genel olarak dispanonide azalma, libido ve koital sıklıkta artış izlendi. Grup II'de tedavi olan POP oranı %91 ($P=0.004$) ve rekürren Evre III POP oranı da %9 idi; bu grupta üri-ner inkontinans izlenmedi; dispanoni tüm vakalarda ortadan kalktı ve libido ve koital sıklık anlamlı derecede arttı ($P=0.001$).

Tartışma: Girişimsel grupta POP'nin tedavi oranları anlamlı derecede daha iyiydi ve bu grupta üri-ner inkontinans ortaya çıkmadı. Dispanoni, libido ve koital sıklık belirgin derecede düzeldi. Defektlerin 4 anatomik planda da re-konstrükte edilmesi cerrahi tedavinin başarısını arttırmaktadır.

Anahtar Sözcükler: kolpopeksi, kolpostansiyon, pelvik organ prolapsusu, laparoskopik cerrahi

Corresponding Author: Dr. Adam Ostrzenski
14808 Gulf Blvd Madeira Beach, 33708 Florida, USA
Phone : +90 727 319 37 77
E-posta: aostrzenski@hotmail.com

Condensation

Non-compensatory colpopexy yielded statistically significant higher cure rate $P=0.004$ (91%) when all four anatomical levels, side-specific defects were repaired in post hysterectomy women associated with stage IV POP. Postoperatively, no urinary incontinence developed, dyspareunia was cured, and libido, and the number of coital event significantly increased.

Introduction

A pelvic reconstructive surgery has to reestablish integrity of a defective gross anatomy, and to restore a functional anatomy, in order to achieve an optimal success of surgical outcomes. The question arises whether or not currently is a surgical technique available to satisfy this concept in women associated with stage IV POP? Reviewing the World literature related to colpopexy and colposuspension by establishing the appropriate Medical Subject Heading (MSH) terms and using them in a computerized search of the Medline database, Ovi-Disc database, and the Online ACOG database, and utilizing a manual search, indicated that until now such technique has not existed. Therefore, the presented technique here of non-compensatory colpopexy is a new operation for total vaginal prolapse for stage IV POP.

A compensatory reconstructive pelvic surgery creates an artificial defect to compensate for an existing pelvic defect(s). Currently, most commonly used compensatory procedures for stage IV POP are transabdominal sacrocolpopexy and transvaginal sacrospinous ligament vaginal suspension. Both of these procedures neither reconstructs a defective gross anatomy nor restores a function of the vagina; however, both techniques are reliable methods for anchoring the apex of the vagina to unnatural suspension areas. Additionally, nonabsorbable suturing and mesh materials used during these procedures predispose for inflammation, adhesion, seromas, harboring and potentiate infection, creating sinus tract, erosion, fistula formation, and shrinkage (1-3). The scope of these complications range from 5% to 27% and depends on mesh material being used (Gore-Tex 5-9% (1); silicone coated AMS 19% (3), Cadaveric fascia 27% (2). Also mesh as a foreign body can erode through-and-through the vagina, bladder and rectum (4-6). An abdominal sacrocolpopexy procedure is associated with postoperative developing of decreasing libido and coital events in 41%, postoperative dyspareunia in 22%, and stress urinary incontinence in 18% (7).

Contrary to compensatory colpopexy, in this new non-compensatory colpopexy technique this absorbable sutures were used and the natural ability of tissues to scar was utilized, by performing tissue scarification with scissors (superficial oozing of blood from the surface of the edges being approximated) or vaporizing with laser or using electrocoagulation on the tissue edges.

The new Ostrzenski's non-compensatory colpopexy surgical technique for stage IV POP is an evolution of previously published techniques, (8-13) in which the restoration of natural pelvic topography and vaginal suspension were developed.

The objective of this study was to analyze and report results of long-term clinical outcomes of non-compensatory colpopexy for stage IV POP.

Materials and Methods

This was a prospective comparative cohort study of 27 women with stage IV POP. The study was designed to meet criteria for Grade B, Level III (B₂) of the evidence-based classification. Surgeries were performed between September 1989 and August 1995. Preliminary clinical outcomes of non-compensatory colpopexy were published by this author in 1996 (8). During the initial study between 1989 and 1995, the ischial spine and the hymen were used as anatomical landmark points of reference; (8) and from February 1996 to February 2006 all subjects were followed-up annually to measure clinical outcomes and the Pelvic Organ Prolapse Quantification classification (POP-Q system) (14) was utilized. Exclusion criteria included: concomitant urinary incontinence of any form, prior anti-incontinence conservative medical or surgical therapy, and medical condition precluding general anesthesia and/or spinal analgesia, pelvic infection within 3 months of preceding the surgery, premalignant or malignant condition of urogenital-perineal-rectal areas. Inclusion criteria included: stage IV POP (total vaginal prolapse), post hysterectomy status, and pessary (the gelhorn or inflataball types) failure to improve symptoms.

Twenty-seven subjects, associated with stage IV POP were divided non-randomly into two groups; 16 women were relocated to the control group I and 11 subjects were assigned to the interventional group II. In both group, the primary outcome measure was recurrence of POP and the secondary outcome measure was postoperative occurrence of urinary incontinence, dyspareunia, changes in libido and changes in frequency of coital events. At the yearly interval, all patients were furnished with a postage-paid return envelope and asked to complete a questionnaire related to pelvic relaxation symptoms and signs, to a 48-hour diary of bladder voiding and to complete the Urogenital Distress Inventory (15) (UDI; a form to assess life quality and distress symptoms for urinary incontinence and pelvic floor dysfunction in women). If we received no response, the author contacted the subjects by phone. A clinical evaluation was conducted annually by the author and the results of the POP-Q measurements were recorded and urinary incontinence was documented.

SPSS 11.5 version for Windows was used to perform statistical analysis. Proportions between subjects in group I and group II were compared by χ^2 test. Categorical variables were compared by 2-sided Fisher test. Interval variables were compared by a Student-*t* test. *P* values <0.05 were considered statistically significant.

Each operation was performed in ambulatory set-up by this author. Surgeries were executed via laparoscopic-transvaginal-perineal approaches. In control group I, 16 women underwent surgical procedures in the anatomical level I, level III, and level IV. In the interventional group II, 11 women were subjec-

ted to reconstructive surgery in the all 4 anatomical levels. In this study, procedures in anatomical levels I and II were performed via laparoscopy in the retroperitoneal area of the pelvis and in the retropubic space retrospectively.

Anatomical level I (Retroperitoneal, upper pelvic area)

The first step was to dissect sharply the bilateral, anterior, and posterior vagina from the adjacent organs, to which the vagina has been anchored during previous surgery(s). The round ligaments, infundibulopelvic ligaments, adnexa, superficial layers of the uterosacral ligaments and the bladder are very commonly sutured to the vaginal apex. Also, the sharp excision of the hernia sac (enterocele) from the pouch of Douglas was executed (Figure 1 and 2). The second step was to suspend the vaginal apex to the deep layer of the uterosacral ligaments posteriorly and to reconstruct the posterior “cul-de-sac” (Figure 3). The third step was to suspend the vaginal apex to the cardinal ligaments (Figure 4). Step four was to re-approximate Denno-villiers’ fascia superiorly to the cardinal/uterosacral complex. Step five was to suspend the vaginal apex anteriorly to the subocervical fascia (also called the anterior vaginal wall or vaginal muscularis) (Figure 5). Number 0-PDS (Polydioxanone) Endoknot suture (Ethicon, Co, New Jersey, USA) was used and tissue scarification was performed throughout entire operation before suturing.

Anatomical level II (The Retzius space area or the midpelvis area)

In the space of Retzius, two reconstructive procedures were performed for repairing lateral vaginal site-specific defects: 1. The right paravaginal defect repair and 2. The left paravaginal defect repair. Laparoscopy magnification in the retropubic area eases the process of identification of the defects (Figure 7-10). The space of Retzius was entered from the abdominal cavity between the urachus and the medial umbilical folds on the right and left sides of the urachus. The transversalis fascia was separated from the superior ramus of the pubis bilaterally with 5 mm laparoscopic curved scissors and/or a hydrodissection technique. To identify paravaginal and pararectal defects, the fascia transversalis and the bladder must be advanced to the midline. The anterior lateral superior vaginal sulci and the tendinous arch can be visualized and defects recognized. Also, the defects can be acknowledged between the obturator internus muscle fascia and/or the pubourethral ligament. There are different forms of fascia defects between the anterior lateral superior vaginal sulci and the tendinous arch (Figure 7-11). The inspection of the tendinous arch from the inferior ramus of the pubic bone to the ischial spine was performed and fascia defects were determined (Figure 7-11). Number 0-PDS (Polydioxanone) Endoknot suture (Ethicon, Co, New Jersey, USA) was used throughout the pararectal and paravaginal reconstruction.

The recto-vaginal fascia converging with the tendinous arch was identified (approximately 4 cm from the inferior ramus of the pubis and approximately 5 cm from the ischial spine). Upon identifying the rectovaginal fascia converging point with the tendinous arch, two 0-PDS stitches were placed

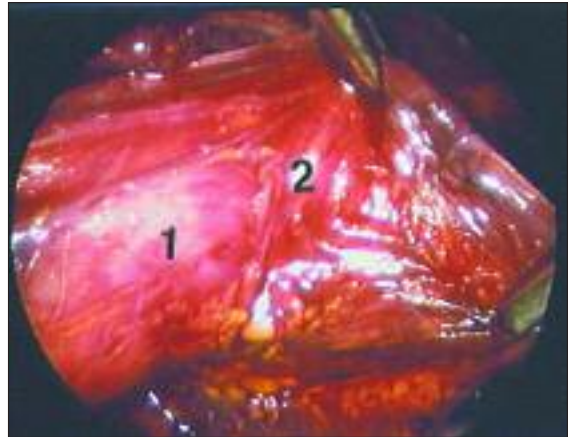


Figure 1. The anatomical level I. Sharp vaginal wall dissection from adjacent anatomical structures; 1. The vaginal wall 2. Dissection stopped at the cardinal ligament

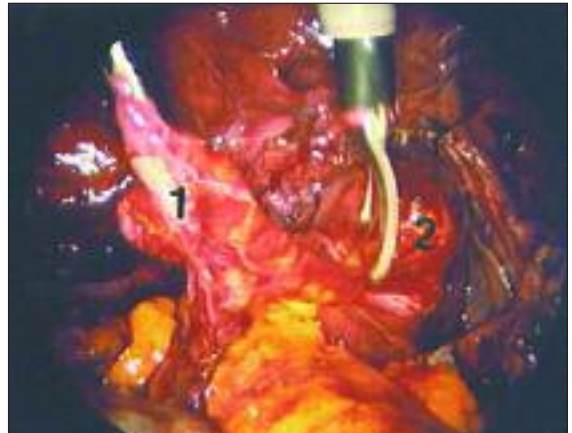


Figure 2. The anatomical level I. Excision of the hernia sac from the pouch of Douglas; 1. A process the hernia sac excision 2. The vagina

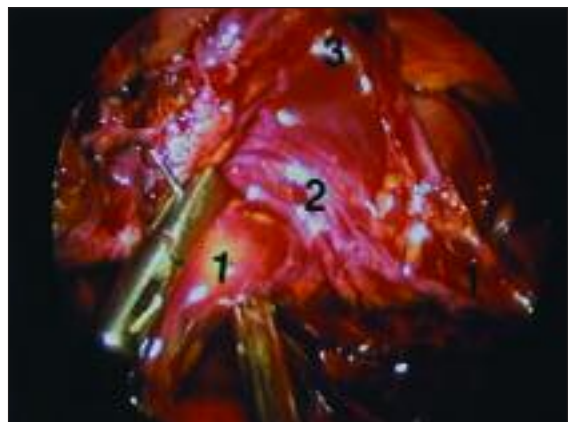


Figure 3. The anatomical level I. A process of posterior vaginal apex suspension and posterior cul-de-sac reconstruction; 1. The deep layers of the uterosacral ligaments 2. The vagina 3. The bladder

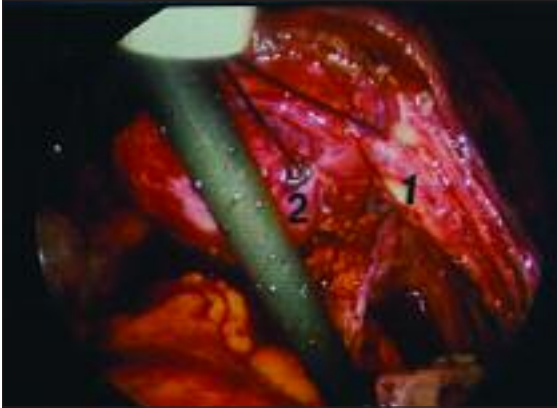


Figure 4. The anatomical level I. Lateral vaginal wall suspension to the cardinal ligament; 1. The cardinal ligament 2. The vagina

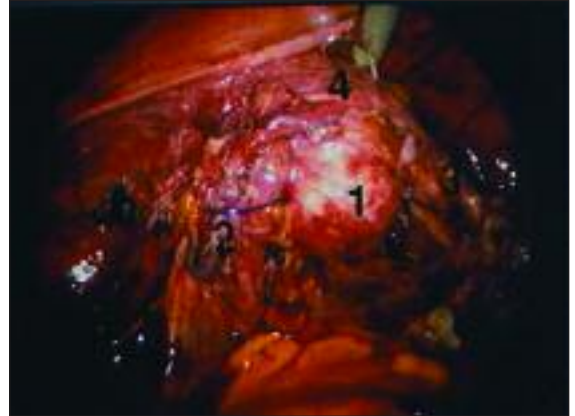

Figure 5. The anatomical level I. Right lateral and posterior vaginal well suspension has been completed; 1. The vagina 2. The right cardinal ligament approximated to the lateral vaginal wall and the uterosacral-cardinal complex was created 3. The left cardinal ligament before placing the second suture 4. The edge of the pubo-cervical (endopelvic) fascia before suturing it to the anterior vaginal apex

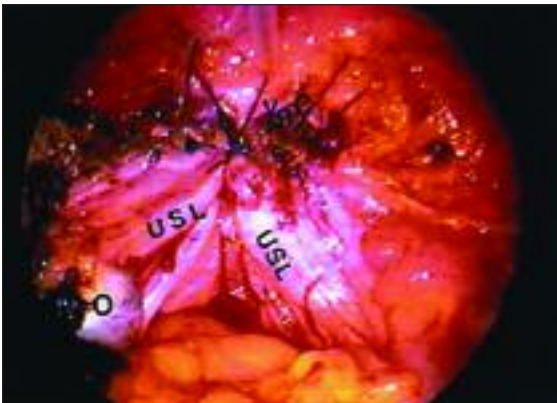


Figure 6. The anatomical level I. Completed surgery in the anatomical level I. Vaginal apex suspension and posterior cul-de-sac reconstruction completed. The uterosacral ligaments (USL) clearly delineate the posterior cul-de-sac. The ovary (O) and tube have been brought out the vaginal apex

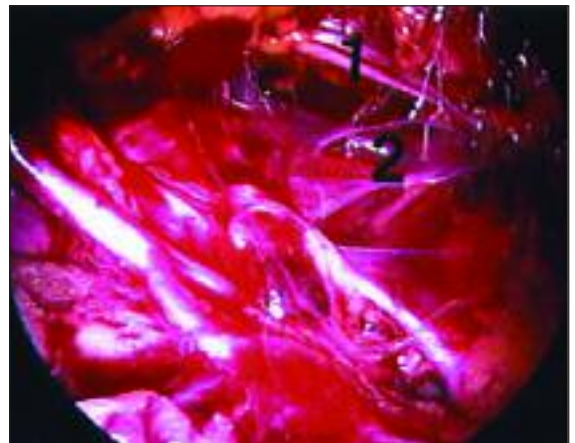


Figure 7. The anatomical level II. Complete separation of the lateral superior vaginal sulci from the tendinous arch; 1. The tendinous arch 2. Paravaginal defect

0.5-1.0 cm laterally to the grasper at the converging point (gentle elevation of the vaginal apex with 2 fingers of the non-dominant hand of the surgeon helps in this process). Both tutes were grasped and put on tension. A third stitch was placed between them. This procedure brings the rectovaginal fascia and the tendinous arch together (Figure 11). The sequence of performing the pararectal reconstruction before performing the paravaginal reconstruction eliminated excessive tissue tension. The paravaginal reconstruction of site-specific defects was carried out bilaterally bringing the edges of the tendinous arch and lateral vaginal paracolpium together. It is important to remember that before tying the knot, tissue edge scarification should be performed to create an environment for a new scar formation. Delayed absorbable suturing materials were used. The modification of the original laparoscopic colpexy (11) was incorporated in 1996 (8). The first stitch in paravaginal reconstruction was placed in the vicinity of the pubourethral ligament and the vaginal envelope. The endopelvic fascia was brought together to the superior fascia of the obtura-

tor muscle and the tendinous arch. Approximately 1.5 to 2 cm apart, the next suture was placed and continued until the anterior paravaginal defect was reconstructed. Before knots were tied, scarification of the tissue edges was performed. The procedure was executed bilaterally (Figure 12).

Anatomical level III (Vaginal wall areas)

The anterior vaginal wall has a trapezoid configuration and the smaller proximal plane attaches ventro-medially near the pubic symphysis and the distal plain attaches dorso-laterally near the ischial spine (16,17). Within this trapezoidal plane, three different types of defects can occur within the anterior vaginal walls: 1. *Central defect* or pubourethral ligament defect is the least common defect of the anterior vaginal wall and is located near the pubic symphysis. This defect will create hypermobility of the urethra with a telescopic movement of the urethra bene-

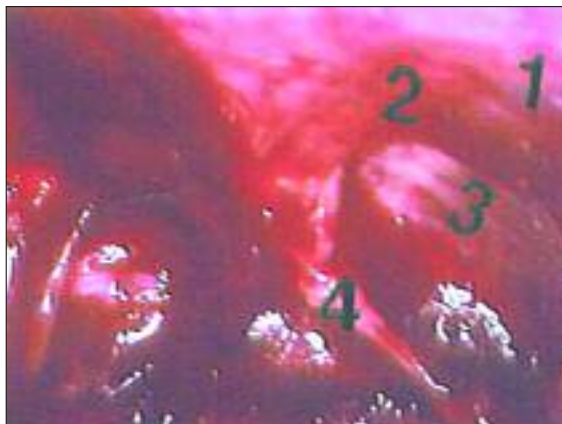


Figure 8. The anatomical level II. The obturator muscle and paravaginal defects; 1. The superior fascia of the obturator muscle 2. The obturator muscle 3. The inferior fascia of the obturator muscle 4. The tendinous arch

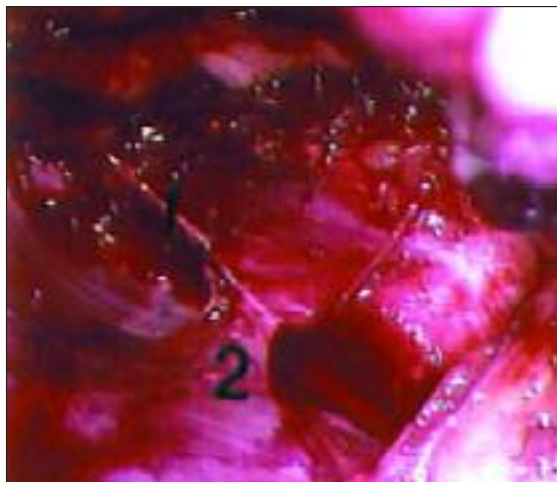


Figure 9. The anatomical level II. Incomplete paravaginal defect; 1. The tendinous arch 2. The preserved fragment of the anterior lateral superior sulci attached to the tendinous arch

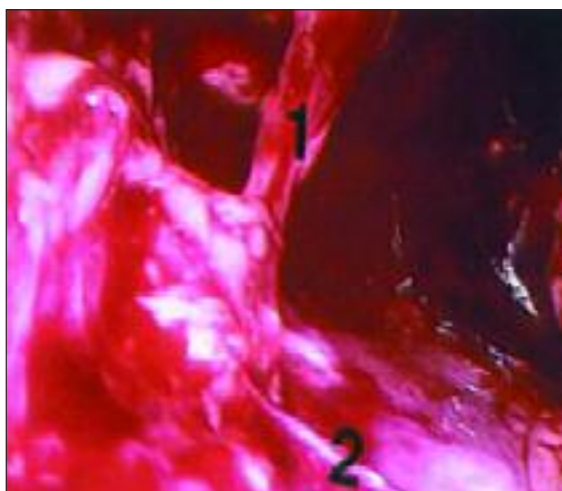


Figure 10. The anatomical level II. Incomplete paravaginal defect. The much smaller “bridge” than on fig 8 between the anterior lateral superior sulci and the tendinous arch

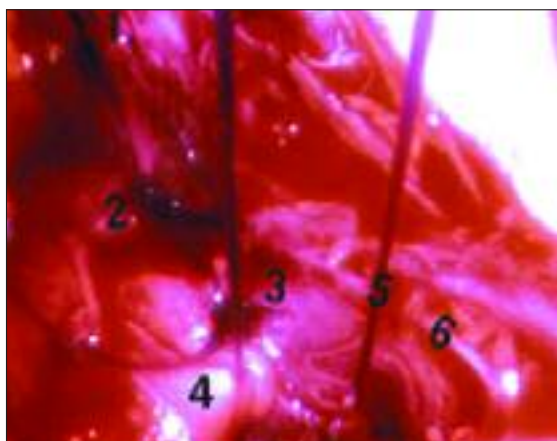


Figure 11. The anatomical level II. Pararectal reconstruction; 1, and 2, and 3 represent suture line 4. Represents the suture enters to the lateral vaginal wall and piercing the Denonvilliers' fascia 5. Suture would be brought to the tendinous arch 6. The tendinous arch

ath the pubic symphysis and it is the most difficult defect to reconstruct (17). 2. *Transverse defect* and double transverse defects are the most common. It is a defect within the pubocervical fascia and will cause large anterior vaginal wall prolapse with the bladder bulging through a defect of the anterior vaginal wall. (17) 3. *Midline defect* is the defect due to an antero-posterior separation of the vaginal muscularis and adventitia layers from the overlying bladder and/or urethra (17,18). 4. *The lateral defects of the vagina* are not within the vaginal walls, but paravaginal and/or pararectal tissues and their reconstruction was presented above in the anatomical level II.

The posterior vaginal wall defects can be identified within the rectovaginal fascia and fall into the following categories: 1.

Upper transverse tear, 2. Lower transverse tear, 3. Double transverse defects, 4. U-shaped tear (semi-lunar), 5. L-shaped tear (transverse and longitudinal tear) and, 6. Mixed tears (19,20). Upon adequate identification, all anterior and posterior vaginal wall defects were reconstructed by the technique described by Richardson (17,19,20). The only difference in executing this part of the surgery was applying scarification of the edges of the tissues before closing the defects and executing it via a laparoscopic approach. Evaluation of the levator ani muscle fascia and its attachment to the rectovaginal fascia must be clinically assessed, and reconstruction must be performed, when a defect is present.

Reconstruction of central (apex) compartment vaginal wall defects has been presented in the section regarding the anat-

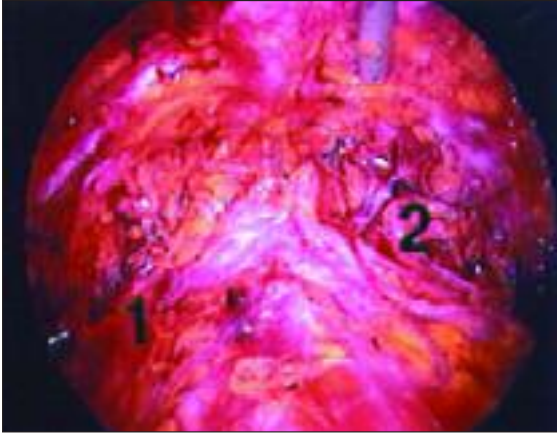


Figure 12. The anatomical level II. Completed paravaginal and para-rectal surgery; 1 and 2 depict the suture lines

mical level I, where retroperitoneal posterior culdoplasty was performed.

Anatomical level IV (Perineal areas)

The perineal membranes, perineal muscle fascias, and perineal body defects repair were the essence of anatomical level IV reconstructions. The most difficult aspect of this part of non-compensatory colpopexy was identifying the defects of fascias within the perineum. Identification of the defects within Colles' fascia, the bulbocavernosus muscle fascia, the superior and inferior fascia of the superficial and/or deep transverse perineal muscles, and the fascia of the external anal sphincter muscle requires significant clinical experience in the dissection of the appropriate layers. These fascia defects must be individually repaired and scarification of the tissue edges must be done before the suture knots can be tied. A monofilament, delayed-

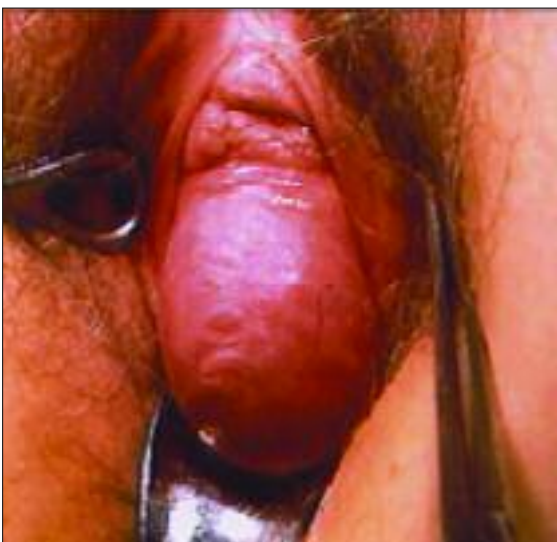

Figure 13. Stage IV of vaginal wall prolapse. The vagina length was 4 cm as a result of previous multiple reconstructive surgeries

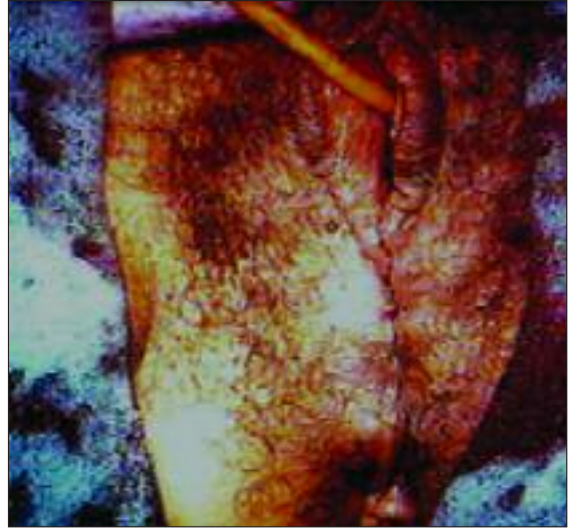

Figure 14. Anatomical level IV. Completed reconstruction in all 4 anatomical levels

absorbable suture was applied to repair the facial defects. The central point of the perineum must be reconstructed, where the all muscle fascias from the left and right sides converge (the fascia of the superficial transverse perineal muscles, bulbocavernosus muscle and external anal sphincter muscle). The perineal reconstruction concludes the non-compensatory colpopexy for stage IV POP (total vaginal prolapse) (Figure 13,14).

Results

All patients were available for a clinical evaluation. Despite a lack of randomization, there were no demographic differences between subjects of both groups. No concomitant anti-incontinence surgical procedure or other surgery was performed in both groups. In control group I, the long-term success rate was 62.50%. Six out of 16 subjects (37.5%) POP recurred. Among these 6 subjects, 3 women demonstrated stage III POP, 2 subjects presented with the stage II POP and 1 subject presented with the stage I POP. The interventional group II had statistically significant lower recurrence of POP ($P=0.004$). The overall success rate in this group was 91%. One case (9%) demonstrated recurring stage III POP. In the interventional group II, stage III POP developed within 7 years postoperatively.

The POP-Q abnormal findings in the group I and group II were presented in Table I and Table II respectively. Five subjects from the group I underwent repair of paravaginal and para-rectal defects. No central defects were identified either in the control or interventional group. One woman with stage I POP decided against repeating pelvic reconstructive surgery. In interventional group II, one subject (9.09%) developed stage III POP. This patient had a re-operation done by a surgeon outside of our institution. Since this woman underwent traditional anterior colporrhaphy, without site-specific defects re-operation, and laparoscopic Burch procedure (she did not present with

stress urinary incontinence), this subject was excluded from this study analysis. Therefore, 10 women from group II had a full 10-year clinical evaluation.

In both group preoperatively, subjects reported the presence of superficial and/or deep dyspareunia, decreased libido and low number coital events († 1 coital event per months). Postsurgically, 81% dyspareunia was cured and 72% libido and the frequency of coital events improved in group I. Dyspareunia was cured in all subjects in group II (statistically significant difference, $P=0.001$). Libido and the frequency of coital events improved significantly ($P=0.003$) in group II.

Five subjects from group I were relocated to group II; however, only a 4-year clinical follow-up evaluation has been conducted. No vaginal wall prolapse has been observed in any of these 5 subjects within 4-year observation period, but these five subjects have not been included in this study analysis.

Conclusion

A non-compensatory colpexy surgical concept is based on the notion of “nature at work” and this reconstructive technique follows the natural path of vaginal suspension and support mechanisms as closely as possible. The vagina is the only organ in the human body that is suspended in multiple anatomical levels, and also supported by several anatomical mechanisms (the retroperitoneal intra-abdominal level, retropubic level, the paracolpium, and the perineum). The natural vaginal location is parallel to the rectum and the levator plate. This location, with its inherent suspension and support mechanisms are designed to maintain the vagina in the intra-pelvic position and to assist vaginal tenting as a natural response to sexual stimulation during the arousal phase. Understanding this complexity are key elements for execution of non-compensatory colpexy successfully.

Subjects from the interventional group II was cured in 91%. A cured was considered when within 10 years stage 0 POP had been maintained. Group I demonstrated cure rate of 62.5%.

Particular attention was given to the case (form the group II), with a 9% surgical treatment failure and stage III POP recurrence. The original video of the operation was reviewed several times. The surgical technique did not depart from the norm that was implemented in all cases in the group II. The patient was previously diagnosed with congenital urachal anomalies (patent urachal sinus) and the case was published (20). Although, reviewing the world literature to identify coexisting vaginal wall prolapse and congenital urachal anomalies did not yield any publication to support this notion. The ultrasonographic study of this case documented the integrity of the paravaginal and pararectal reconstruction was preserved. Also, the posterior vaginal wall, posterior “cul-de-sac”, and the perineal membrane/body were intact. Only an anterior vaginal transverse defect was identified. Whether or not the transverse anterior vaginal defect was missed during the original surgery or an inherited weakness of the anterior vaginal compartment was present is impossible to recognize. In the group I, 62.5% long-term cure rate is quite impressive in this medical entity; however, when all levels of vaginal suspension and support mechanism defects were repaired (the group II), it yielded a statistically significant higher cure rate, $P=0.004$ (91%).

It is imperative to remember that all the anatomical defects must be identified and adequately reconstructed. The posterior “cul-de-sac” repair, which is an integral part of non-compensatory colpexy, must be executed by incorporating the deep layer of the uterosacral ligaments (8,9) and not by obliterating the peritoneum (21-24). Obliterative posterior culdoplasty procedures such as Moschowitz, (21) Halban, (22) Torpin (23) and McCall (24) utilize the peritoneum as ana-

Table 1. Group I subjects with recurrent POP-Q

Subject	Aa	Ba	C	Ap	Bp	TVL	gh	pb	Stage
1	+1.7	+2.8	-1.5	-3	-3	7	3.9	3	III POP
2	+1.5	+3	-2.5	-3	-3	8	3.5	3	III POP
3	+1.2	+2	-3	-3	-3	8.5	2.5	3	III POP
4	0	-1.8	-3	-3	-3	8	2.2	3	II POP
5	1	-1.2	-3	-3	-3	8.5	2.8	3	II POP
6	-1.5	-1.8	-3	-3	-3	7.5	2.0	3	I POP

The measurement is presented in centimeters.

Aa: point on anterior vagina 3 cm proximal to hymen; **Ba:** most dependent point of anterior wall; **C:** the most distal edge of the cuff; **Ap:** 3 cm proximal to the hymen on posterior wall; **Bp:** most dependent point of wall; **TVL:** total vaginal length; **gh:** the distant from the external meatus to the posterior hymen; **pb:** the distant from the posterior hymen to the annual opening

Table 2. Group II subject with recurrent POP-Q

Subject	Aa	Ba	C	Ap	Bp	TVL	gh	pb	Stage
6	+2.0	+1.5	-1.5	-3	-3	6	2.8	3	III POP

Table 3. Different anatomical levels reconstruction for total vaginal prolapse

Anatomical Levels	Anatomical Region	Site-Specific Damage Reconstruction
LEVEL I Laparotomy or laparoscopic approach	The Retroperitoneal Abdominal – Pelvis	<ol style="list-style-type: none"> 1. Sharp dissection of the vagina from the adjacent structure 2. Retroperitoneal Identification of: <ol style="list-style-type: none"> a. The cardinal ligaments b. The deep layer of the uterosacral ligaments c. The subvesical location of the pubocervical fascia 3. Retroperitoneal Posterior Culdoplasty: <ol style="list-style-type: none"> a. Sharp excision of the peritoneal hernia sac of the posterior cul-de-sac b. Reconstruction of the cul-de-sac by utilizing the deep layer of the uterosacral ligaments and the Dennoivilliers' fascia 4. Retroperitoneal vaginal apex suspension to: <ol style="list-style-type: none"> a. The deep layer of the uterosacral ligaments and the Dennoivilliers' fascia (the posterior vaginal wall) b. The cardinal ligaments bilaterally (the lateral vaginal wall) c. The pubocervical fascia (the anterior vaginal wall)
LEVEL II Laparotomy or laparoscopic approach	The Retzius Space	Para-rectal and para-vaginal reconstruction: <ol style="list-style-type: none"> a. Suspension of the Dennoivilliers' fascia to the tendinous arch b. Suspension of the lateral vaginal wall to the tendinous arch
LEVEL III Vaginal approach	The Vagina	<ol style="list-style-type: none"> 1. Anterior compartment site specific damage reconstruction of central, transverse or midline. (The lateral damage see level 2) 2. Central compartment (see posterior culdoplasty see level 1) 3. Posterior compartment site specific damage reconstruction (upper or lower transverse, or double transverse, or L-shape or mix damage)
LEVEL IV Perineal approach	The Perineum	Site-specific perineal membrane and perineal body damage reconstruction

tomical elements for obliteration of the posterior “cul-de-sac”. The peritoneum is not strong enough for posterior “cul-de-sac” reconstruction in stage IV POP. The superficial layer of the uterosacral ligaments are considered as part of the peritoneum and the stretching ability of peritoneum make it useless in reconstructive surgery for colpexy. In 1929, Okabayashi (25) documented the presence of the deep retroperitoneal layer of the uterosacral ligaments, which are strong and suitable for reconstruction of stage IV POP.

It is critical to incorporate the rectovaginal fascia (the rectovaginal septum or Denonvillier's fascia) into the reconstructive process due to the fact that the rectovaginal fascia is indirectly attached to the sacrum via the uterosacral ligaments and to the pelvic side bone, and the inferior arm of the pubic bone via the cardinal ligaments. In 1839, Denonvillier first described a layer of fascia in men, and in 1957, Uhlenhuth and Nolley, (26) in 1969, Milley and Nichols, (27) and in 1993 Richardson (19) documented the presence of this structure in women. Additionally, the rectovaginal fascia is indirectly attached to the ischial spine through the tendinous arch. Leffler et al. (28) published the results of the anatomical study, in which they proved that the rectovaginal septum was anchored directly to the tendinous arch. This finding concurred with clinical observations presented by Ostrzenski (7-9). Indeed, the rectovaginal fascia is clearly noticeable as an off-white structure fusing with the tendinous arch. This converging point is

clinically identifiable approximately 4 cm from the inferior pubic ramus and 5 cm from the ischial spine (Figure 11).

In non-compensatory colpexy, the vaginal apex was firmly suspended to the natural suspensory mechanisms (the cardinal and the uterosacral ligaments) (Figure 6). Fresh tissue approximation (oozing blood before edges approximation or using laser, or electrocoagery for scarification) created an environment for “de novo” scar formation in desirable areas. It would allow using delayed absorbable suturing materials and using non-absorbable suturing materials or mash, which both can lead to tissue weakening by developing erosion should be avoided. The scarification technique was used throughout the entire non-compensatorycolpexy procedure and in each anatomical level.

Lateral vaginal wall defects, paravaginal and/or pararectal, are not defects within the vaginal wall. A paravaginal defect occurs when the anterior superior lateral vaginal sulci separate from the tendinous arch (Figure 1-7). In 1909, White (28) described the surgical reconstructive technique of paravaginal area, by which anterior wall prolapse (cystocele) was reduced. White's (28) observation did not appeal to pelvic surgeons for over 67 years until Richardson et al (16) resurrected this procedure and added clinical evidence of a cause-and-effect between the presence of a paravaginal defect and anterior vaginal wall prolapse. In 1996, Ostrzenski (7,11) adapted and modified White's technique (28) by adding the pararectal reconstruction and

executed it laparoscopically. Also, in 1998, Ostrzenski utilized this technique laparoscopically for the treatment of stress urinary incontinence in women (12). The presence of lateral vaginal defects requires not only paravaginal defect reconstruction for total vaginal prolapse but also pararectal defect reconstruction. To assist in identification and documentation of paravaginal defects Ostrzenski et al (29) and Ostrzenski & Osborne (30) developed the ultrasonographic technique.

The perineum plays a significant role in the supportive mechanism of the vagina. Whether or not the presence of a defect itself in the perineal area can lead to vaginal walls prolapse and to what extent defects can influence vaginal prolapse are unknown. Reviewing the existing literature on this subject failed to produce any publication that documented a cause-and-effect between perineal membrane and/or perineal body defects and vaginal wall prolapse. Historically, perineoplasty has been performed long enough such that a departure from this clinical approach without verifiable clinical data would be an inappropriate undertaking. The perineal membrane has a direct anatomical relationship to the tendinous arch, levator muscles, perineal body and pubic bone and functionally participates in compressing the urethra, and the urethral-vaginal sphincter.

The non-compensatory colpopexy procedure can be executed as a combination of laparotomy/transvaginal/perineal approaches or laparoscopic/transvaginal/perineal approaches. The laparoscopic approach is a very demanding approach, since it requires a surgeon to master a very advanced laparoscopic skill in the abdominal-pelvic retroperitoneal areas and in the retro-pubic Retzius' space.

Conclusion

1. In the interventional group, the higher cure rate was statistically significant, no urinary incontinence occurred, and dyspareunia, libido, and the number of coital events improved significantly. 2. Reconstructing all defects in all four anatomical levels provided optimal outcome for the surgery.

References

- Begley JS, Kupferment SP, Kuznetsov DD et al. Incidence and management of abdominal sacrocolpopexy mesh erosions. *Am J Obstet Gynecol* 2005 June;192(6):1956-62.
- Kammerer-Doak DN, Rogers RG, Bellar B. Vaginal erosion of cadaveric fascia lata following abdominal sacrocolpopexy and suburethral sling urethropexy. *Int Urogynecol J Pelvic Floor Dysfunct*. 2002;13(2):106-9.
- Cervigni M, Natale F. The use of synthetics in the treatment of pelvic organ prolapse. *Curr Opin Urol* 2001 Jul;11(4):429-35.
- Kohli N, Walsh PM, Roat TW, Karram MM. Mesh erosion after abdominal sacrocolpopexy. *Obstet Gynecol* 1998 Dec;92(6):999-1004.
- Patsner B. Mesh erosion into the bladder after abdominal sacral colpopexy. *Obstet Gynecol* 2000 Jun;95(6 Pt 2):1029.
- Kenton KS, Woods MP, Brubaker L. Uncomplicated erosion of polytetrafluoroethylene grafts into the rectum. *Am J Obstet Gynecol* 2002 Jul;187(1):233-4.
- Virtanen H, Hirvonen T, Makinen J, Kiilholma P. Outcome of thirty patients who underwent repair of posthysterectomy prolapse of the vaginal vault with abdominal sacral colpopexy. *J Am Coll Surg* 1994;178(3):283-7.
- Ostrzenski A. Laparoscopic colposuspension for total vaginal prolapse. *Int J Gynecol Obstet* 1996;55:147-52.
- Ostrzenski A. A new, simplified posterior culdoplasty and vaginal vault suspension during abdominal hysterectomy. *Int J Gynecol Obstet* 1995;49:25-34.
- Ostrzenski A. New retroperitoneal culdoplasty and colpopexy at the time of laparoscopic abdominal hysterectomy (L-TAH). *Acta Obstet Gynecol Scand* 1998;77:1017-21.
- Ostrzenski A. A new laparoscopic retroperitoneal posterior culdoplasty. *J Reprod Med* 1999;44:504-10.
- Ostrzenski A. Laser video laparoscopic colpopexy. *Pol Gynecol* 1992;63(7):317-23.
- Ostrzenski A. Genuine stress urinary incontinence in women. A new laparoscopic paravaginal reconstruction. *J Reprod Med* 1998;43:477-82.
- Bump RC, Mattiasson A, Bo K, Brubaker LP et al. The standardization of terminology of female pelvic organ prolapse and pelvic floor dysfunction. *Am J Obstet Gynecol* 1996 Jul;175(1):10-7.
- C. Huub van der Vaart, JRJ de Leeuw, JPWR Roovers, AP Heintz: Measuring health-related quality of life in women with urogenital dysfunction: The Urogenital Distress Inventory and Incontinence Impact Questionnaire revisited. *Neurourol Urodyn* 2003;22:97-104.
- DeLancey JOL. Fascial and muscular abnormalities in women urethral hypermobility and anterior vaginal wall prolapse. *Am J Obstet Gynecol* 2002;187:93-8.
- Richardson AC. A new look at the pelvic relaxation. *Am J Obstet Gynecol* 1976;126:568-73.
- Weber AM, Walters MD. Anterior vaginal prolapse: Review of anatomy and techniques of surgical repair. *Obstet Gynecol* 1997;89:311-8.
- Richardson AC. The anatomic defects in rectocele and enterocele. *J Pelv Surg* 1995;1:214-8.
- Richardson AC. The rectovaginal septum revisits relationship and its importance in rectocele repair. *Clin Obstet Gynecol* 1993;36:976-83.
- Ostrzenski A, Osborne NG, Ostrzenska K, Godette AO. Preoperative contrast ultrasonographic diagnosis of patent urachal sinus. *Int Urogynecol J* 1998;9:52-4.
- Moschcowitz AV. The pathogenesis, anatomy and cure of prolapse of the rectum. *Surg Gynecol Obstet* 1912;15:7-21.
- Halban J. *Gynaekologische Operationslehre*. Urban und Schwarzenberg. Berlin 1932, p 172.
- Torpin R. Excision of the cul-de-sac of Douglas, for surgical care of hernias through the female caudal wall, including prolapse of the uterus. *J Int Coll Surg* 1955;24:322-30.
- McCall ML. Posterior culdoplasty: Surgical correction of enterocele during vaginal hysterectomy: A preliminary report. *Obstet Gynecol* 1957;10:595-602.
- Okabayashi H. Radical abdominal hysterectomy for cancer of the cervix uteri. *Surg Gynecol Obstet* 1929;23(4):335-46.
- Uhlenhuth E, Nolley GW. Vaginal fascia, a myth? *Obstet Gynecol* 1957;10:349-58.
- Milley PS, Nichols DH. A correlative investigation of the human rectovaginal septum. *Anat Rec* 1969;163:443-52.
- Leffler KS, Thomson JR, Cundiff GW, Buller JL, Burrows LJ, Ybarra MAS. Attachment of the rectovaginal septum to the pelvic sidewall. *Am J Obstet Gynecol* 2001;185:41-3.
- White GR. Cystocele: a radical cure by suturing lateral sulci of vagina to white line of pelvic fascia. *JAMA* 1909;21:1707-10.
- Ostrzenski A, Osborne NG, Ostrzenska K. Method for Diagnosing Paravaginal Defects Using Contrast Ultrasonographic Technique. *J Ultrasound in Med* 1997;16:673-7.
- Ostrzenski A, Osborne NG. Ultrasonography as a Screening Tool for Paravaginal Defects in Women with Stress Incontinence: A Pilot Study. *Int Urogynecol J* 1998;9:195-9.