

Diverticulum of the Ureter Presenting as an Adnexal Mass in a Woman with Familial Adenomatous Polyposis

Ali HABERAL¹, Evrim Ebru KOVALAK¹, Mehmet GÖKCÜ¹, Aylin Pelin ÇİL¹, Hikmet TOPALOĞLU²

¹*Etilik Obstetrics and Gynecology Training and Research Hospital, Ankara, Turkey*

²*Dışkapı Training and Research Hospital, Ankara, Turkey*

Received 18 June 2005; received in revised form 09 October 2005; accepted 28 December 2005

Abstract

Pelvic mass is the terminology used for the masses anatomically located in the female pelvis. Although, these masses usually take origin from gynecologic organs, they can also originate from genitourinary and gastrointestinal system. The clinical presentation of pelvic masses may differ according to its origin, so we must always keep in mind rare situations like our case. Blind-ending duplication of the ureter with cystic dilation of blind-ending branch is a rare malformation and often gives rise to urinary complications. Duplicated and bifid ureters constitute the most common ureteral malformations, but a double malformation combining a diverticulum of one ureter with a distal bifid ureter on the same side is rare. We report a case of a woman with familial adenomatous poliposis and blind-ending duplication of the ureter with cystic dilation of blind-ending branch, which was misdiagnosed as an adnexal mass.

Keywords: adnexal diseases, diverticulum, ureter, abnormalities

Özet

Familiyal Adenomatöz Polipozisli Bir Kadında Adneksiyal Kitle Gibi Ortaya Çıkan Üreter Divertikülü

Pelvik kitle anatomik olarak kadın pelvisinde lokalize kitlelerin terminolojisi için kullanılır. Bu kitleler, çoğunlukla jinekolojik organlardan kaynaklanmasına rağmen, üriner ve intestinal organlardan da kaynaklanabilirler. Pelvik kitle nadiren değişik klinik prezentasyonlarla karşımıza çıkabilir. Bu nedenle cerrahi öncesi her türlü olasılık göz önünde bulundurulmalıdır. Üreter divertikulumu nadir bir malformasyon olup, sıklıkla üriner komplikasyonlara neden olur. Çift ya da bifid üreterler en yaygın üreteral malformasyonlardır. Ancak, aynı tarafta bir distal bifid üreterle bir divertikülün kombinasyonundan oluşan çift malformasyon oldukça nadirdir. Biz, familiyal adenomatöz polipozisli bir kadında, adneksiyel kitle tanısı koyduğumuz üreter divertikülünü sunduk.

Anahtar sözcükler: adneksiyel kitle, divertikülüm, bifid üreter

Introduction

Diverticulum of the ureter is a rare malformation and often gives rise to urinary complications, but duplicated and bifid ureters constitute the most common ureteral malformations (given as 0.65% in 51 880 autopsies by Campbell and as 1.8% in 5196 urographies by Privett) and usually have no pathologic consequences (1,2). We report the case of a woman with familial adenomatous polyposis and diverticulum of the ureter, which was misdiagnosed as an adnexal mass.

Case

A 34-year-old woman, G1, P1 presented with pelvic pain and vomiting for a week. She had a history of cesarean section 8 years ago, right salpingoophorectomy and cholecistectomy 2 years ago, total proctocolectomy and mucosal ileoanal pouch, and Brooke ileostomy for familial adenomatous polyposis 3 years ago. Her family history was remarkable for familial adenomatous polyposis. Her initial physical examination was unremarkable other than incision scars on the abdomen of her past operations. On pelvic examination; a tender, cystic mass was noticed on the left adnexal region. The transvaginal ultrasound examination showed a normal sized uterus and a 15x10 cm unilocular, simple cystic mass in left adnexal region and the left ovary could not be clearly visualized. On intravenous pyelography, the right kidney, pelvicalyceal system and the bladder looked normal, but the

Corresponding Author: Dr. Evrim Ebru Kovalak
Tavuskuşu Sok. No: 23/17, Dikmen, 06460 Ankara, Türkiye
Phone : +90 312 482 45 89
+90 312 322 01 80
E-mail : evrimebru@yahoo.com

left kidney was hydronephrotic with grade 2 dilatation of the pelvicalyceal system and the distal portion of left ureter was not visualized appropriately. Consulting with an urologist, the reason for hydronephrosis was thought to be because of the external pressure of the mass defined by ultrasound. Her laboratory examination including the total blood count, biochemical values, urinalysis and tumor markers were within normal limits. At the twelfth hour of hospitalization, her pain worsened and she had an emergent surgery. At laparotomy, after sharp and blunt dissections of the adhesions, a 15x10 cm mass was noted on the left adnexal region. The uterus and left ovary was normal. After a small incision made on the cyst capsule, urine like fluid was seen inside the cyst with a ureteral opening leading to a diagnosis of ureteral diverticulum. On the distal portion of the cyst, there were two openings, both of them were atrophic. One of the openings was ended blindly after 5 cm and the other one could be followed up to the bladder. Proximal end of the left ureter was dissected and the cyst capsule was excised. The histological examination of the frozen section of the specimen was reported as benign pathology. Because the distal ureter was not enough and it was atrophic, either end to end anastomosis or procedures like Boary flap or psoas hitch was impossible; transureteroureterostomy was applied between the right ureter and the proximal portion of the left ureter with the insertion of a Double J catheter. The recovery period was uneventful. Postoperative histological analysis demonstrated that the cystic mass was consistent with a diagnosis of ureteral diverticulum (Figure 1).

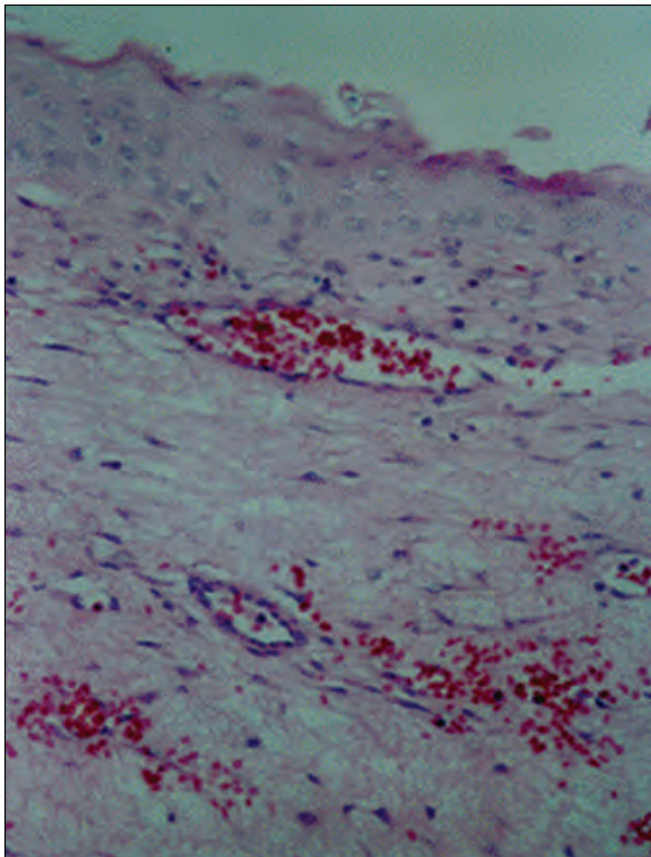


Figure 1. Squamous epithelium on the diverticulum wall with hemorrhagic fibrous tissue underneath (Stain: hematoxylin-eosin, 150x).

Discussion

Pelvic or adnexal masses are common dilemmas faced by practicing gynecologists. Usually the origin of the adnexal masses can be diagnosed with history, laboratory evaluation and radiological imaging techniques but sometimes confusing situations as within our case can lead to atypical presentations.

Diverticula of the ureter have been classified by Gray and Skandalakis into three categories; abortive ureteral duplications (blind-ending bifid ureters), true congenital diverticula containing all tissue layers of the normal ureter, and acquired diverticula representing mucosal herniations (3). Single acquired diverticula may be associated with strictures or calculi and may occur after trauma (4).

The ureteral duplication and bifid ureter are relatively common malformations and often clinically unimportant, but stasis and pyelonephritis do occur. On the other hand, duplicated or bifid ureters with a blind-ending branch are rare (1). Because the blind segment does not always fill on excretory urography, retrograde pyelography may be required for diagnosis (3). In our patient the intravenous pyelography did not show a diverticulum and as we had no suspicion of a diverticulum, a retrograde pyelography was not performed. Many of these blind ending segments do not cause any problems. (1).

Congenital diverticula of the ureter results from the same malformation process as bifid ureters and as duplex ureters with a blind-ending branch (3). Congenital diverticula possess the histological layers of the ureter (mucosa, muscularis and adventitia) and connect with the other ureter at an acute angle (bifid ureter with blind-ending branch). Through these structural features they are distinguished from acquired diverticula (post-traumatic or infective), which have no ureteric wall proper (1). The histopathologic diagnosis in our case revealed partly stratified and simple squamous epithelium with hemorrhagic fibrous tissue underneath which does not typically seen in congenital cases. Because of three past pelvic operations, stricture formation was seen in our patient. Distal ureteral flow obstruction because of strictures, probably lead to gradual formation of diverticula and by the additive action of the pressure caused by increasing mass of the diverticula lead to total obstruction of the flow at the end. As the weakest point of the ureter is the bifurcation point of the bifid ureter with the blind ending pouch, this is the most common point where the diverticula are seen, as in our case. Gradual growing of the mass and flow obstruction lead to ureterohydronephrosis and slowly increasing nature of the pain. Total occlusion of the ureter, caused distal visualization defect in intravenous pyelography and we couldn't see diverticula before surgery. If we had suspected of diverticula formation, performing a retrograde pyelography could visualize the diverticula.

Familial adenomatous polyposis is an autosomal dominant hereditary disease characterized by the appearance of hundreds of colorectal polyps which inexorably undergo malignancy.

nant transformation (4). To our knowledge, there isn't any other report in the literature about a double malformation combining left distal ureteral duplication and a diverticulum of left proximal ureter in a patient with familial adenomatous polyposis. The ureteral obstructions reported in this syndrome are usually due to desmoid tumors (5).

In conclusion, as gynecologists we must always be in suspicion to meet adjacent organ pathologies while evaluating pelvic masses. Although it is a rare pathology, ureteral diverticula should be in mind in patients with past abdominopelvic operations.

References

1. Cussenot O, Desgrandchamps F, Teillac P, Lesourd A. Double ureter and congenital diverticulum of the ureter. *Surg Radiol Anat* 1991;13:323-6.
2. Perlmutter AD, Retik AB, Bauer SB. Anomalies of the upper urinary tract. In: Campbell (ed). *Urology*, Vol 2. Philadelphia: WB Saunders; 1986; 1713-55.
3. Schlüssel RN, Retik AB. Ectopic ureter, ureterocele, and other anomalies of the ureter. Chapter 58. In: Walsh PC (ed). *Campbell's Urology*, 8th Edn. Philadelphia: Saunders; 2002;2007-52.
4. Penna Ch. Management of familial polyposis coli. *J Chir (Paris)* 2002;139 (5):260-7.
5. Pikaar A, Nortier JW, Griffioen G, Vasen HF. Desmoid tumors in patients with familial adenomatous polyposis. *Ned Tijdschr Geneeskd.* 2002 Jul 20; 146(29):1355-9.



www.journalagent.com

**Online manuscript
submissions and
peer review
(Journal Agent)**

Now available at
J Turkish German Gynecol Assoc
www.jtgga.org