

Amniotic Band Syndrome Associated With Cranial Defects and Ectopia Cordis: A Report of Two Cases

Talat Umut KUTLU DİLEK¹, Gürkan YAZICI¹, Sıtkı GÜLHAN², Ayşe POLAT³, Burcu DİLEK⁴, Saffet DİLEK¹

¹Department of Obstetrics and Gynecology, Mersin University School of Medicine, Mersin, Turkey

²Department of Radiology, Mersin University School of Medicine, Mersin, Turkey

³Department of Pathology, Mersin School of Medicine, Mersin Turkey

⁴Department of Radiology, Mersin State Hospital, Mersin Turkey

Received 28 May 2005; received in revised form 15 September 2005; accepted 18 September 2005

Abstract

Amniotic band syndrome is a group of disorders characterized by amputations, disunion, constricting bands and body wall defects. Amniotic band syndrome or amnion disruption sequence had complex pathophysiological mechanism. We described the diagnosis of two cases of amniotic band syndrome by postmortem examination. In the first case, cranial deformation, ectopia cordis, facial cleft and gastroschisis were detected by ultrasound. In the second case, ultrasonography has revealed a frontal encephalocele. In both cases amniotic bands were detected at postmortem examination. This report indicates the importance of detailed search for amniotic bands when body wall defects, facial clefts and cranial deformations are diagnosed.

Keywords: ectopia cordis, amniotic band syndrome, craniofacial abnormalities, gastroschisis

Özet

Kraniyal Defektlerin ve Ektopia Kordisin Eşlik Ettiği Amniyotik Band Sendromu: 2 Olgu Sunumu

Amniyotik band sendromu; amputasyonlar, disunion, konstriksiyona yol açan bandlar ve karın duvarı defektleri ile seyreden kompleks bir bozukluktur. Amniyotik band sendromu, kompleks fizyopatolojik mekanizmaya sahiptir. Bu yazıda otopside amniyotik band sendromu tanısını alan iki olguyu tanımladık. İlk olguda prenatal ultrasonografide kraniyal deformiteler, ectopia kordis, fasiyal yarıklar ve gastroşizis saptanmışken, ikinci olguda sadece ultrasonografi ile frontal ensefalosel tespit edildi. Her iki olguda da amniyotik bandlar postmortem incelemede saptandı. Ventral defektlerin, fasiyal yarıkların ve kraniyal deformitelerin saptandığı olgularda amniyotik bandların araştırılması gereklidir.

Anahtar sözcükler: ectopia kordis, amniyotik band sendromu, kraniyal defektler, gastroşizis

Introduction

Amniotic band syndrome is a rare complex group of malformation associated with fibrous bands that entrap or entangle various fetal parts in-utero. Disunion, deformation, malformations, clefts and constricting bands and amputations of various part of body could be seen. It occurs in 1 in 1200 to 1 in 15 000 live births (1). It can affect any organ or system and cause a single or multiple defects. Amniotic bands cause unique anomalies; no single child affected with amniotic band syndrome has been reported to demonstrate all of these

defects (2). Also no infant are affected in same manner. We presented two different cases which had amniotic band related congenital anomalies.

Case 1

An 18-year-old primigravida woman was referred to our clinic for advanced ultrasonographic evaluation at 21 weeks of gestation. Past medical history was normal and no prenatal exposure to teratogenic agents and family history of congenital malformation. She did not admit for antenatal care visit until 20th weeks of gestation. In the first visit, before the admission to our clinic, ectopia cordis and gastroschisis were detected. We performed sonography by GE Logic 500 Pro scanner (Milwaukee, US) with 3.5 MHz convex transducer. Sonography revealed a live fetus with an ectopia cordis, gastroschisis, single umbilical artery, facial cleft and disruption

Corresponding Author: Dr. Talat Umut Kutlu Dilek
Adonis Sitesi, Selvi Blok No: 20, Mezitli, Mersin, Türkiye
Phone : +90 533 384 42 64
Fax : +90 324 337 43 05
E-mail : umutdilek@gmail.com

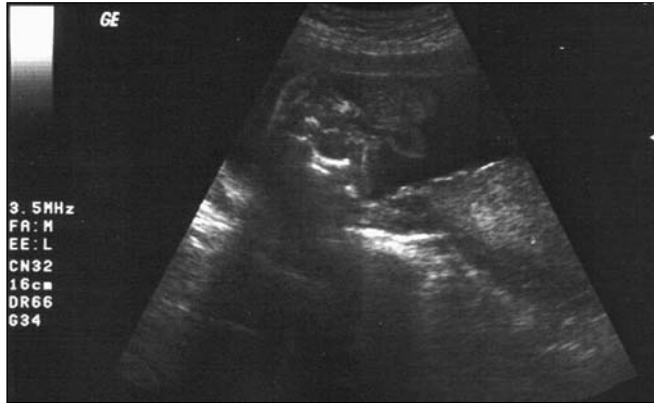

Figure 1. Extracorporeal location of fetal heart was seen.

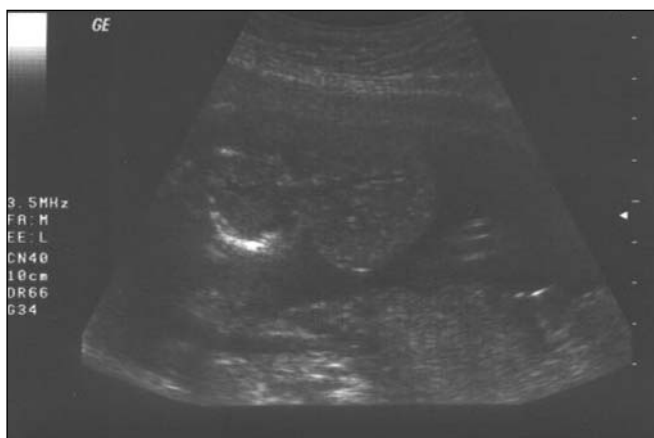


Figure 2. Ultrasound was revealed gastroschisis and extra-abdominal location of fetal liver.

of skull bones in the midline (Figure 1, 2). Amniotic fluid volume was normal. By the diagnosis of ectopia cordis, gastroschisis and midline skull deformation, pregnancy was terminated at 22 weeks of gestation. Before the termination, percutaneous umbilical blood sampling was done to genetic evaluation of effected fetus. A female fetus weighing 380 g with a karyotype of 46 XX was delivered. In addition to pre-termination sonographic findings, amniotic band over the scalp and pes equinovarus and cleft plate were detected. Pathologic examination confirmed the prenatal ultrasonographic diagnosis. Cystic degeneration of brain, amniotic band over the scalp, bilateral cleft and lip, ectopia cordis, gastroschisis and bilateral pes equinovarus were seen (Figure 3). Bladder, kidneys and external genitalia were normal. Cardiovascular malformation accompanying to ectopia cordis was not seen.

Case 2

A 29-year-old primigravida admitted for routine sonographic examination and 2nd trimester biochemical screening test at 18 weeks of gestation. First trimester ultrasonographic evaluation was unremarkable. She had report no recent infection, exposure of teratogenic agents or family history of malformations. Sonographic examination was done by GE Logic 500 Pro (Milwaukee, US) with 3.5 MHz convex transducer. Frontal

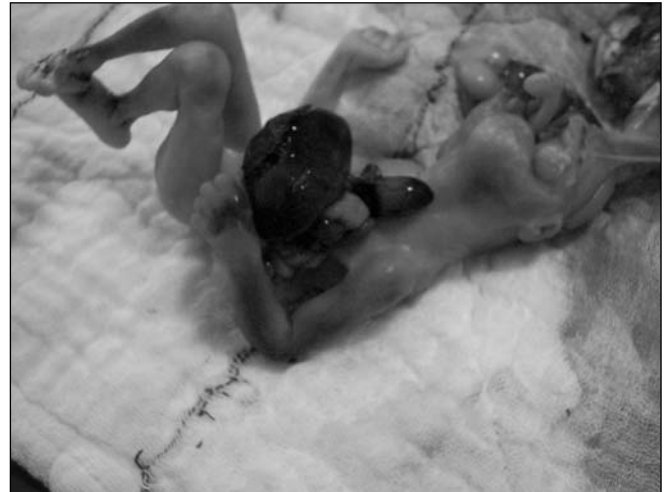

Figure 3. During the postmortem examination, gastroschisis, ectopia cordis, clubfoot and bilateral facial cleft were seen. Amniotic band was adhered on the fetal cranium in the midline axis.

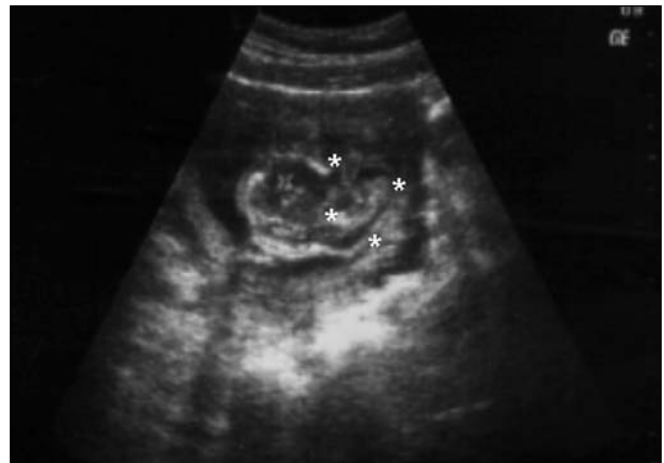

Figure 4. Frontal encephalocele was detected during the ultrasonographic examination.

cystic mass containing solid component possibly “brain tissue” was detected by ultrasound. Cytogenetic analysis by cultured amniotic fibroblasts revealed a 46 XY karyotype. Following the initial evaluation pregnancy was terminated. Pathologic examination confirmed frontal encephalocele with amniotic band (Figure 4). Amniotic band was over the frontal region. Frontal lobe was herniated to the subcutaneous tissue from bony defect. Fetal extremities, external genitalias, anal opening, urinary bladder, kidneys, hearth and gastrointestinal system were normal. Umbilical cord contained three vessels.

Discussion

Amniotic band syndrome or amniotic band disruption complex are characterized by asymmetrical disruptive anomalies, with amputated limbs and splitting defects such as ventral wall defects. Estimated prevalence is 1 in 1200 to 1 in 15 000 live births (1). Occurrences of amniotic constricting bands are mostly sporadic. It is rarely associated with connective tissue disorders such as Ehlers-Danlos syndrome or epider-

molysis bullosa. Relation with methadone or lysergic acid diethylamide (LSD) was not confirmed (3). However, the etiology of amniotic band syndrome is still obscure.

Cranial defects associated with amniotic band syndrome are common, including acranium, acalvarium, encephalocele, hydrocephalus, microcephaly, focal absence of calvarial bones and anencephaly. Also cleft lip and plate, bizarre midline facial defects and orbital clefts could be seen. Craniofacial defects associated with amniotic bands are expected in one-third of cases. In both cases, amniotic bands were fused over the scalp. In the first case, amniotic band attached over the cranial defect along the sagittal suture and skull bones were absent below the site of attachment. However, in the second case bone defects secondary to amniotic band was smaller than first case. In either case amniotic band adherent to cranial defects could not be detected prenatally.

In the differential diagnosis of cranial bone defects, large encephaloceles, acranium, acalvarium, anencephaly and aplasia cutis congenital should be considered (2). Cranial bone defects are limited in the encephaloceles. However, for others cranial bony elements were absent and presence of varying degree of brain tissue could be detected. Diagnosis of cranial bone defects can be established by ultrasound in the first trimester. However detection was delayed until the mid-second trimester in both cases.

The presence of body wall defects with evisceration or herniation of intrathoracic or abdominal content also called body wall defects. Body wall defects could be seen secondary to amniotic bands. In this group of anomalies were produced during the very early stages of gestation (4). Ectopia cordis is an anomaly which the fetal heart lays outside the thoracic cavity is very rare. Incidence was less than 1 in 100 000. Prognosis is very poor. Most cases are sporadic, although a few cases associated with chromosomal abnormalities (5). Association of ectopia cordis with amniotic band is very rare. Ninety percent of fetuses with ectopia cordis were associated with other cardiovascular abnormalities such as septal defects, pulmoner valve atresia, tetralogy of Fallot, anomalous venous return (6). However, in the first case, possible associated cardiovascular anomalies were not seen. Prenatal diagnosis of ectopia cordis is made by extrathoracic pulsating mass containing Doppler

waveforms typical for intracardiac flow. Usually, the amniotic band syndrome is associated with oligohydramnios (4), amniotic fluid volume was normal in both cases.

In the differential diagnosis, pentology of Cantrell and Limb-Body wall complex should be considered for case one. Discrimination of two pathologies is difficult. Pentology of Cantrell consists of five malformations including ectopia cordis, sternoschisis, abdominal wall defects, and defect of diaphragm and of the pericardium. Presence of amniotic bands and association with serious facial clefts and absence of additional cardiac malformations suggest that this case independent from pentology of Cantrell (7). Large abdominal wall defects, severe neural tube defects, kyphoscoliosis and caudal regression syndrome are elements of Limb-Body wall complex. Discrimination from Limb-Body wall defect is difficult. Several features of case 1 were similar to Limb Body wall complex. However, absence of neural tube defects, vertebral anomalies and extremity anomalies suggest that diagnosis was amniotic band syndrome.

Diagnosis of ectopia cordis and cranial bone defects warrant a careful survey of fetal limbs, body wall and internal organs. Several ultrasonographic findings suggest amniotic band syndrome including digital defects or amputations, facial dysmorphism, body wall defects and amniotic bands. In the presence of multiple structural anomalies, amniotic band syndrome should be considered in the differential diagnosis.

References

1. Torpin R. Amniochorionic mesoblastic fibrous strings and amniotic bands associated constricting fetal malformations or fetal death. *Am J Obstet Gynecol* 1965;91:65-75.
2. Cincore V, Ninios A, Pavlik J, Hsu Chaur-Dong.. Prenatal diagnosis of acrania associated with amniotic band syndrome. *Obstet Gynecol* 2003;102:1176-8.
3. Blanc WA, Mattison DR, Kane R, Chauthan P. L.S.D. Intrauterine amputations and amniotic band syndrome. *Lancet* 1971;7716:158-9.
4. Frias MMI, Bermejo E, Rodriguez P. Body stalk defects, body wall defects, amniotic bands with and without body wall defects, and gastroschisis: Comparative Epidemiology. *Am J Med Genet* 2000;92:13-8.
5. Medina-Escobedo G, Reyes-Mugica M, Arteaga-Martinez M. Ectopia Cordis: Autopsy findings in four cases. *Pediatr Pathol* 1991;11:85-95.
6. Tongsong T, Wanapirak C, Sirivatanapa P, Wongtrangan S. Prenatal Sonographic Diagnosis of Ectopia Cordis. *J Clin Ultrasound* 1999;27:440-5.
7. Bognoni V, Quartuccio A, Quartuccio A. First-trimester sonographic diagnosis of Cantrell's pentology with exencephaly. *J Clin Ultrasound* 1999; 27:276-8.