

# Prenatal Ultrasonographic Diagnosis of Fetal Tumors

Halil ASLAN, Gökhan YILDIRIM, Yavuz CEYLAN

*Bakırköy Women's and Children's Research and Training Hospital, İstanbul, Turkey*

Received 15 July 2005; received in revised form 13 October 2005; accepted 14 October 2005

## Abstract

The prenatal diagnosis of fetal tumors have significant implications on the well-being of both mother and fetus. From February 2000 to May 2005, we diagnosed 12 fetuses with tumors: one neuroblastoma, one axillary lymphangioma, one hemangioma, four sacrococcygeal teratomas, two anterior cervical teratomas and three ovarian cysts. Two women had termination of pregnancy for their fetal sacrococcygeal and cervical teratomas. One fetus with sacrococcygeal teratoma died of heart failure. Six tumors of the live birth infants were surgically resected and they did well after surgery without adjuvant chemotherapy. Prenatal diagnosis of fetal tumors with a multidisciplinary approach may lead to successful outcome in neonates.

**Keywords:** fetus, tumors, prenatal diagnosis, ultrasonography

## Özet

### Fetal Tümörlerde Prenatal Ultrasonografik Tanı

Fetal tümörlerin prenatal tanısı hem anne hem de fetus sağlığı açısından hayli önemlidir. Ünitimizde Ocak 2000-Mayıs 2005 tarihleri arasında prenatal tanı almış 12 fetal tümör olgusu şunlardır: bir nöroblastoma, bir aksiller lenfanjioma, bir hemanjioma, dört sakrokoksigeal teratom, iki servikal teratom ve üç over kisti. Sakrokoksigeal ve servikal teratom nedeniyle iki gebelik ailenin isteği doğrultusunda sonlandırıldı. Sakrokoksigeal teratomlu bir fetus kalp yetmezliğinden intrauterin dönemde kaybedildi. Altı olgu cerrahi rezeksiyon sonrası adjuvan kemoterapi gerekmeksizin düzeldi. Fetal tümörlerde prenatal tanı ve multidisipliner yaklaşım ile yenidoğanlarda başarılı sonuçlar alınabilir.

**Anahtar sözcükler:** fetus, tümör, prenatal tanı, ultrasonografi

## Introduction

A variety of neoplasms may occur in any organ system during fetal life. A fetal neoplasm is very rare but may be associated with serious illness or even death in the fetal or neonatal period. The prenatal diagnosis of fetal tumors have significant implications on the well-being of both mother and fetus, as well as on perinatal and neonatal outcome. Prenatal detection of fetal tumors may alert the obstetrician not only to the fetus but also the potential of maternal risk. The prenatal diagnosis of fetal tumors by ultrasound has been described only in the last two decades (1). Improvements in antenatal diagnosis have been made by the addition of MRI (2), chromosomal studies of the fetal cells from amniocentesis (3), and attempts to identify tumor-associated antigens in maternal and fetal blood (4). We report a detailed study of 12 prenatally diagnosed fetal tumors, evaluating clinical outcomes.

## Materials and Methods

This study is a retrospective database analysis. Data were obtained from the database of the Maternal-Fetal Unit of Bakırköy Women's and Children's Research and Training Hospital. In our department prenatal ultrasound examinations were performed on all pregnancies at 20-22 weeks' gestation or at the first antenatal visit in the third trimester. In all women with an abnormal fetal ultrasonographic finding, further investigations such as detailed ultrasonography, genetic amniocentesis were performed. Counselling regarding the anomaly and further management was provided by a pediatrician and a pediatric surgeon. Depending on the diagnosis and the stage of the tumours, surgical intervention and adjuvant therapy were planned.

## Results

We reviewed the period from February 2000 to May 2005. All prenatal ultrasonographic examinations conducted on 6575 patients were analyzed, and 12 cases of fetal tumors were found in a variety of organs. They included one neuroblastoma (NB), one axillary lymphangioma, one hemangioma; 4 sacrococcygeal teratomas (SCT); 2 anterior cervical teratomas and 3 ovarian tumors.

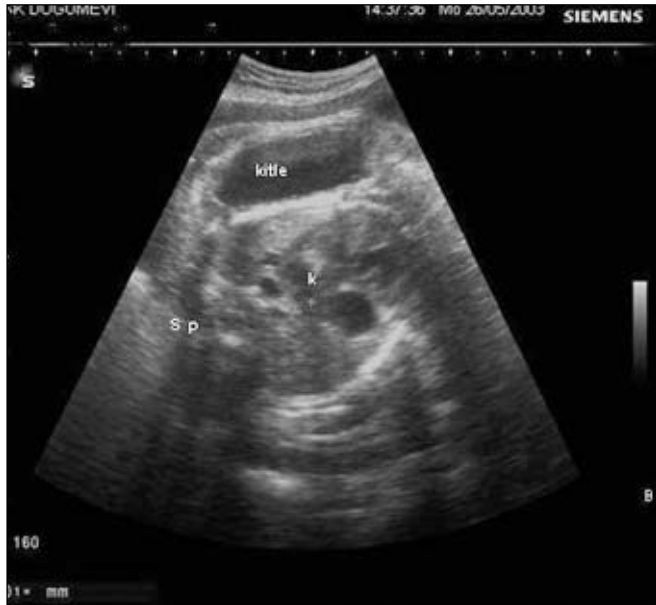**Corresponding Author:** Dr. Halil Aslan

Defne 02-03, B-10 Daire: 17

34850 Bahçeşehir, İstanbul, Türkiye

Phone : +90 543 62 70/418-183

E-mail : halil34aslan@gmail.com



**Figure 1.** Ultrasound image of large cystic tumor located on the left side of the trunk.

**Axillary Cystic Lymphangioma**

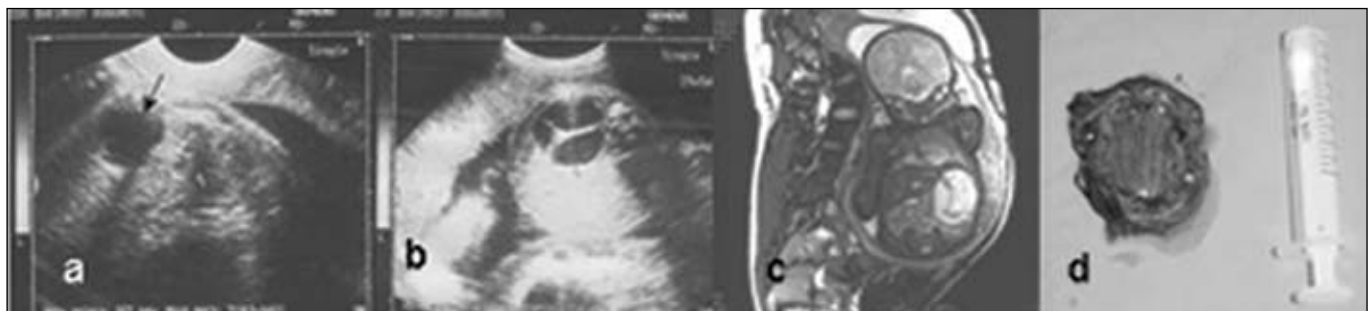
One fetus had an axillary cystic lymphangioma. Ultrasonographic examination at 34 weeks of gestation, revealed a 64x72x25 mm sized cystic mass in the left axillary region of the fetus (Figure 1). Doppler studies revealed absence of blood flow. A previously performed amniocentesis for an advanced maternal age at 17 weeks showed a normal karyotype (46 XX). A 3800 g weighing female infant was delivered at 39 weeks with spontaneous vaginal delivery, with Apgar scores of 10 and 10 at 1 and 5 minutes, respectively. On delivery, neonatal physical examination confirmed the presence of a large 70x80 mm cystic subcutaneous lesion in the left axillary region. No other structural anomalies were identified. To assess the connection of the mass with adjacent structures, a neonatal CT was performed. It showed a 70x60x50 mm-sized, well-defined cystic mass with multiple septation at the left lateral chest wall without extension to upper neck or mediastinum. The tumor was resected one month after birth and the neonate was discharged three days postoperatively. Histological examination of the tumor revealed a cystic lymphangioma. There were no signs of complications or sequelae.

**Sacrocoygeal Teratoma (SCT)**

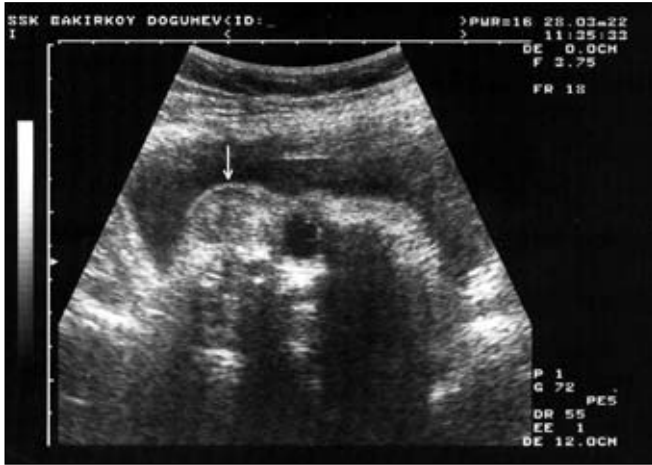Four fetuses with a SCT were determined. Termination of pregnancy was performed on one fetus with SCT at 18 weeks after prenatal counseling with the parents. Histology of the tumor showed immature teratoma. Another fetus died from heart failure. Postmortem examination confirmed prenatal ultrasonographic diagnosis. The third one was born at 37 weeks of gestation with cesarean delivery, weighing 3900 g. The tumor was resected one day after birth. The patient was discharged from hospital at seven days of age. Histological examination of the tumor showed immature teratoma with some areas of mature tissue. No complications or sequelae developed. Another fetus was born at 39 weeks of gestation with cesarean delivery weighing 3400 g. After a month the tumor was resected. Histological examination of the tumor showed neuroglial tissue. Followed up for 19 months, the patient did not show any evidence of complications.

**Neuroblastoma**

One fetus was found to have a cystic suprarenal mass at 26 weeks. The origin of this intraabdominal mass was the right renal fossa. The lesion was well demarcated, completely cystic and measured 16x19 mm in the location of the right fetal adrenal gland (Figure 2a). Follow-up ultrasonographic examinations performed at 29 weeks showed an increase in size of the mass with intracystic septations (Figure 2b). Magnetic resonance imaging (MRI) performed at 33 weeks revealed a complex cystic mass which has been located between right kidney and liver (Figure 2c). In T2 weighted MRI scans the lesion appeared as a well rounded, predominantly cystic complex mass measuring 60x60 mm in diameter. Three weeks after MRI scan, the patient delivered spontaneously a male infant weighing 2770 g. He underwent an ultrasound examination on the first day of his life, which confirmed the presence of adrenal tumor. The tumor was resected three days after birth (Figure 2d). Histopathologic analysis revealed a mildly-differentiated neuroblastoma. The surgical margins were free of neoplasm and there was no infiltrative growth. The infant had an uncomplicated postoperative period and was discharged 9 days after the operation. Followed up for two years, the infant did not show any evidence of tumor recurrence.



**Figure 2.** (a) Prenatal ultrasound of the fetus with a simple cystic suprarenal mass. (b) Horizontal fetal abdominal sonogram at 29 weeks, showing the tumor with intracystic septations. (c) Magnetic resonance image at 33 weeks shows a well demarcated, predominantly cystic mass. (d) Resected specimen of the neuroblastoma.



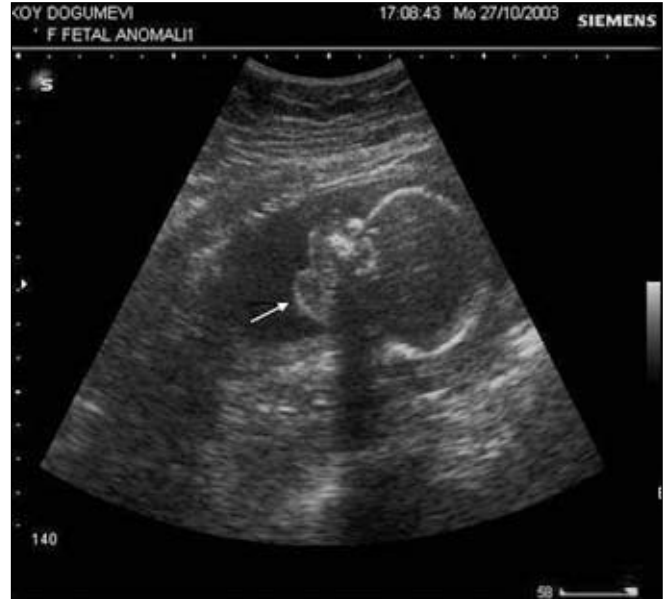**Figure 3.** An ultrasound scan of abnormal face with a mass around the fetal cheek.

### Fetal Hemangioma

One fetus was diagnosed to have a hemangioma of the face. At 40 weeks of pregnancy the fetal face was found to be abnormal; at the level of the left fetal cheek. A solid tumor measuring 66x70 mm was present (Figure 3). The fetal brain, chest, abdomen and limbs were normal. An elective cesarean was performed and a female baby weighing 3630 g was delivered. The extensively vascularized tumor of the neonatal face was proved by neonatal examination. The tumor infiltrated the left cheek, lower palpebra, and oral cavity. Its diameter and thickness was approximately 5x2 cm respectively. Within the tumor mass there were many dilated vessels. The infant was discharged six days after birth but died at 40 days with an unknown etiology.

### Cervical Teratoma (CT)

Two fetuses were diagnosed to have cervical teratomas. A complex cystic mass was found in the anterior aspect of the neck at 23 weeks. The cystic mass was well demarcated and measured 48x55 mm (Figure 4). The parents opted to terminate the pregnancy after antenatal counseling. A 880 g weighing male infant was delivered. Postmortem physical

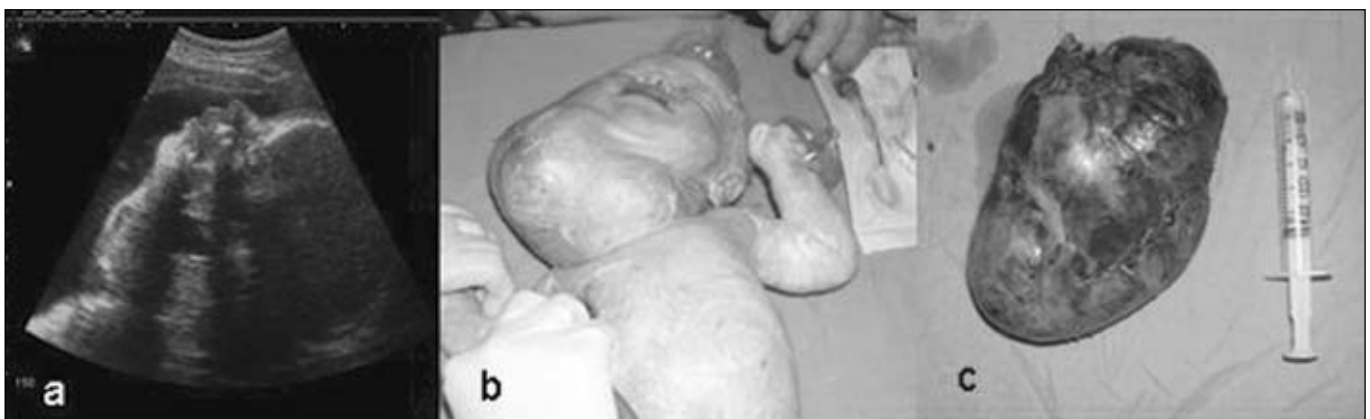

**Figure 4.** A complex cystic mass located on the anterior aspect of the fetal neck.

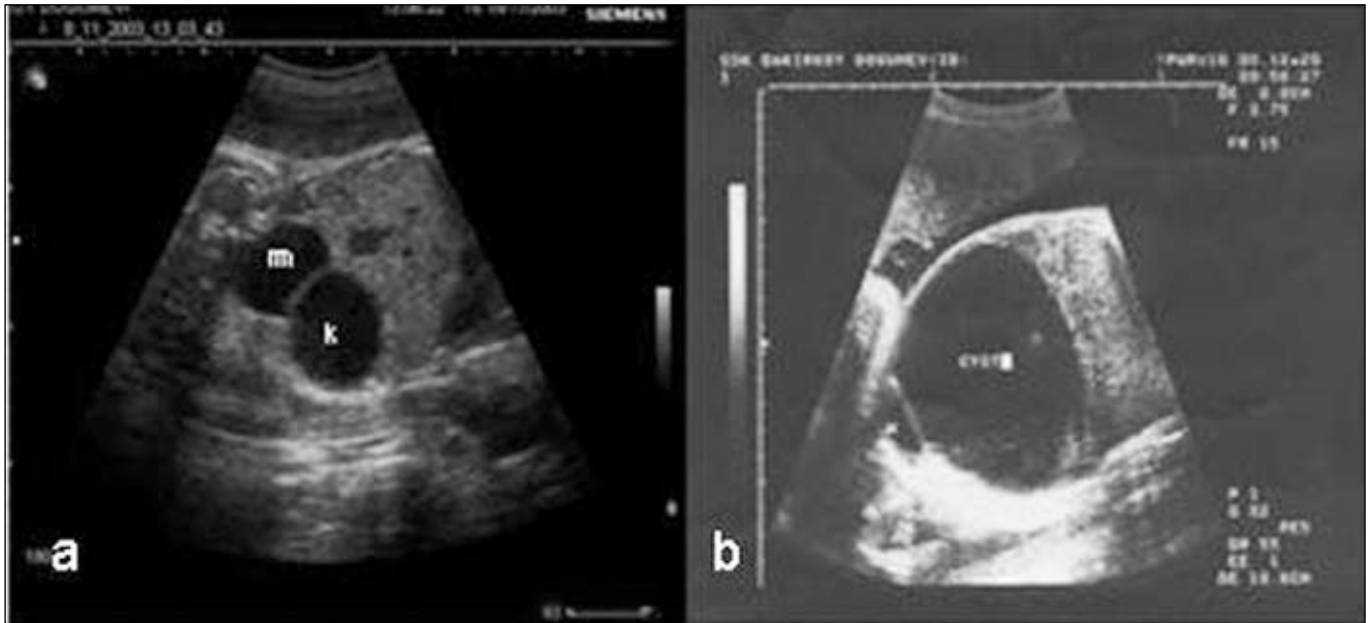
examination confirmed the presence of a large, 55x60 mm cystic lesion on the anterior neck region. Histology confirmed the prenatal diagnosis of cervical teratoma. In the second fetus, an asymmetric, unilateral, well demarcated multiloculated complex cervical mass was detected on ultrasound at 32 weeks of pregnancy (Figure 5a). At term, a male fetus weighing 3400 g was delivered by cesarean section (Figure 5b). The infant had postnatal intubation for the relief of airway obstruction because of a 120x100 mm solid mass in the cervical region. The tumor was resected in the second day of life (Figure 5c) and showed no recurrence 18 months after therapy.

### Ovarian Tumors

Three fetuses had ovarian tumors. Two fetuses were delivered with birth weights of 3390 and 3140 g respectively at 38 weeks by elective cesarean. Another fetus was delivered spontaneously with a birth weight of 3300 g at 40 weeks. One of the tumors was resected on postpartum day one beca-



**Figure 5.** (a) Sagittal scan of a giant multicystic complex neck mass. (b) Frontal view of the infant following delivery. (c) Photograph of the resected neck tumor.



**Figure 6.** Prenatal ultrasound images of fetal ovarian cysts. Note the position of the bladder in each case (a-b).

use of suspicion of ovarian torsion; histological examination of the tumor showed benign tissue (Figure 6b). In the remaining two infants (Figure 6a) there was no need to perform a surgical procedure and the follow-up of the cysts showed spontaneous regression in neonatal period.

### Discussion

Lymphangiomas are common congenital lymphatic malformations that are frequently present at birth and are thought to result from obstruction of lymphatic vessels leading to the jugular venous system. Prenatal diagnosis of a large lymphangioma can easily be achieved by ultrasonography on the basis of multilocular or septate cystic mass. Postnatal outcome is mainly related to the connections of the lesion with surrounding organs (5). In our case the axillary cystic lymphangioma was easily diagnosed by 2D ultrasonography, but in order to establish its extent and limits fetal MRI and 3D scans may be needed.

Sacroccygeal teratoma is the most common congenital neoplasm, usually presenting as a large mid-axial exophytic mass in the sacroccygeal region. It may be almost entirely external (type I), internal and external in equal parts (type II), mainly internal (type III), or entirely internal (type IV) (6). SCTs usually appear as cystic, solid, or mixed cystic and solid masses arising from the sacroccygeal region. The main causes of death are hydrops, intrapartum trauma and difficulties with either local resection or hemorrhage secondary to tumor vascularity in the postnatal period (7). In our series, two of the four prenatally diagnosed SCTs did well.

Neuroblastoma is the most frequent extracranial solid tumor in childhood, but it is seldom diagnosed prenatally (8). With the increasing use of prenatal ultrasonography to detect fetal anomalies, the possibility of early detection of children with neuroblastoma is increasing, with potential implications for

the management of these children. The tumor appears as a mass in the upper part of the kidney, but its sonographic aspect varies considerably. Three different ultrasonographic patterns have been described: cystic, complex and solid. There may be associated polyhydramnios and fetal hydrops. The tumor can metastasize in utero (placenta, liver, or blood vessels), however, metastasis from fetus to mother has never been reported. The differential diagnoses of a fetal adrenal mass include adrenal hemorrhage, neuroblastoma, adrenal and cortical renal cysts, pulmonary sequestrations, duplication of the gastrointestinal and urinary system and Beckwith-Wiedemann syndrome (9). In our case an initially simple cystic adrenal mass progressed to a multilobulate complex structure, suggesting intracystic hemorrhage. Fetuses with neuroblastoma tend to have a favorable stage of disease, favorable biological features, and consequently an excellent prognosis compared to infants diagnosed after birth. Prenatal diagnosis permits planned delivery and immediate neonatal surgery.

Hemangiomas are rare tumors in the neonatal period. They may be present in different parts of the body. In ultrasonographic examination hemangioma of the face may be present as an abnormality of the fetal face, with a solid tumor extending to fetal cheek and neck. The mouth, mandible and nose may be distorted by the tumor. The prenatal diagnosis of a fetal face tumor should include: lymphangioma, epignathus, teratoma, hygroma colli and atypical goitre (10). Color and pulsed Doppler examinations may reveal vascularization within the tumor.

Cervical teratomas are easily detected on prenatal ultrasound. Findings of a semisolid, semi-cystic mass in the antero-lateral aspect of fetal neck, extending across the midline are suggestive of this diagnosis. Airway obstruction in the newborn because of tracheal compression or occlusion has been reported as the cause of an 80-100% mortality rate in untreated cervical te-

ratomas in the neonatal period. However, survival is most often excellent after surgical removal. The differential diagnosis for cervical teratomas includes cystic hygroma, congenital goitre, thyroglossal duct cyst (11). We have demonstrated in the second case that prenatal diagnosis, and careful planning for delivery can allow for a successful outcome in a neonate with a large congenital cervical teratoma.

Fetal ovarian cysts are not rare and they represent cystic lesion confined to the lower abdomen of a female fetus, when the stomach, bladder and both kidneys appear normal. The cysts may achieve a considerable size up to 10 cm in large ones. The cysts may be unilocular or multilocular. Torsion is suspected when intracystic flocculation is observed. Most of the simple ovarian cysts tend to regress near term or in the early neonatal period. In such cases, fair prognosis does not justify in-utero therapy and labor induction (12-14). The outcome of a baby born with disabilities has been an important issue for clinicians in ethical, economical and legal aspects (15).

Once a fetal tumor has been detected, close surveillance by a multidisciplinary team is mandatory, with anticipation and early recognition of problems during pregnancy, labor and immediate postnatal stage.

## References

1. Meizner I. Perinatal oncology-the role of prenatal ultrasound diagnosis. *Ultrasound Obstet Gynecol* 2000;16:507-9.
2. Sbragia-Neto L, Melo-Filho AA, Guerra-Junior, et al. Beckwith-Wiedemann syndrome and virilizing cortical adrenal tumour in a child. *J Pediatr Surg* 2000;35:1269-71.
3. Al-Nemri AR, Kilani RA, Salih MA, Al-Ajlan AA. Embryonal rhabdomyosarcoma and chromosomal breakage in a newborn infant with possible Dubowitz syndrome. *Am J Med Genet* 2000;92:107-10.
4. Hohfeld P, Dang TT, Nahoul K, Daffos F, Forestier F. Tumour-associated antigens in maternal fetal blood. *Prenatal Diag* 1994;14:907-12.
5. Ruano R, Aubry JP, Simon I, Grebille AG, Sonigo P, Dumez Y, Domerguez M. Prenatal diagnosis of a large axillary cystic lymphangioma by three-dimensional ultrasonography and magnetic resonance imaging. *J Ultrasound Med* 2003;22:419-23.
6. Sheth S, Nussbaum Ar, Sanders RC, Hamper UM, Davison AJ. Prenatal diagnosis of sacrococcygeal teratoma: Sonographic-pathologic correlation. *Radiology* 1988;169:131-6.
7. Heerema-McKenney AH, Harrison MR, Bratton B, Farrell J, Zaloudek C. Congenital teratoma: a clinicopathologic study of 22 fetal and neonatal tumors. *Am J Surg Pathol* 2005;29(1):29-38.
8. Grosfeld JA, Rescorla FJ, West KW, Goldman J. Neuroblastoma in the first year of life: clinical and biological factors influencing outcome. *Semin Pediatr Surg* 1993;1:37-43.
9. Aslan H, Ozseker B, Gul A. Prenatal sonographic and magnetic resonance imaging diagnosis of cystic neuroblastoma. *Ultrasound Obstet Gynecol* 2004;24:693-4.
10. Respondek-Liberska M, Janiak K, Jakubek A, Marosynka I, Lipka B, Dembowska B, Milewska-Bobula B, Perek D, Wilczynski J. Prenatal diagnosis of fetal face hemangioma in a case of Kasabach-Meritt syndrome. *Ultrasound Obstet Gynecol* 2002;19(6):627-9.
11. Kerner B, Flaum E, Mathews H, Carlson DE, Pepkowitz SH, Hixon H, Graham JM Jr. Cervical teratoma: prenatal diagnosis and long-term follow-up. *Prenat Diagn* 1998;18:51-9.
12. Aslan H, Bulut H, Akyol A, Gülcan EM, Ark C. Torsiyone fetal over kistinin prenatal tanısı ve yönetimi. *Jinekoloji ve Obstetrik Dergisi* 2002;16:117-9.
13. Aslan H, Akyol A, Ülker V. Fetal over kisti. *Perinatoloji Dergisi* 2001;9:54-6.
14. Küçük T, Yenen MC, Dede M, Başer İ, Ergün A. Fetal overyan kistlerinde tanı ve takip. *Perinatoloji Dergisi* 2000;8:43-5.
15. Ward C, Myers NA. Babies born with major disabilities; the medical-legal interface. *Pediatr Surg Int* 1999;15:310-9.