

Ectopic Pregnancy in Mesoappendix

Cemil YAMAN¹, Manfred CZOMPO²

¹Department of Obstetrics and Gynecology, General Hospital of Linz Krankenhausstr. 9, A-4020 Linz, Austria

²Department of Pathology, General Hospital of Linz Krankenhausstr. 9, A-4020 Linz, Austria

Received 01 July 2005; received in revised form 18 August 2005; accepted 19 August 2005

Abstract

A 36-year-old nullipara with a history of two years of infertility was referred because of delayed menses and generalized lower abdominal pain. Although the beta human chorion gonadotropin (β -hCG) level was 9200 IU/mL, transvaginal sonography revealed no intrauterine gestational sac. Laparoscopy was performed. Ectopic pregnancy in mesoappendix with concurrent appendicitis were diagnosed. The occurrence of ectopic pregnancy in the mesoappendix is a new finding. Therefore, in cases without laparoscopic evidence of ectopic pregnancy in the fallopian tubes, also (meso)appendix should be checked.

Keywords: ectopic pregnancy, laparoscopy, mesoappendix

Özet

Mezoappendikse Yerleşmiş Ektopik Gebelik: Olgu Sunumu

Burada 36 yaşında, adet gecikmesi ve generalize alt abdominal ağrı nedeniyle refere edilen ve iki yıldan beri infertilite nedeniyle takip/televi edilen bir hasta sunulmaktadır. Transvajinal sonografide beta human chorion gonadotropin (β -hCG) seviyesinin 9200 IU/mL olmasına rağmen intrauterine gebelik kesesi saptanmamıştır. Yapılan laparoskopide appendisit bulgusuna eşlik eden ezoappendikse yerleşmiş ektopik gebelik izlenmiştir. Ektopik gebeliğin mezoappendiks lokalizasyonunda saptanması yeni bir bulgudur. Bu sebeple laparoskopik gözlem sırasında fallop tüplerinde ektopik gebelik bulgusuna rastlanmaması durumunda mezoappendiksin de kontrol edilmesinde fayda bulunmaktadır.

Anahtar sözcükler: ektopik gebelik, laparoskopi, mezoappendiks

Introduction

Ectopic pregnancy and appendicitis are two common causes of a surgical abdomen in young women and these conditions are associated with high morbidity. Women with a history of infertility prior to ectopic pregnancy, tubal surgery, pelvic infection or use of intrauterin device are at higher risk of ectopic pregnancy. These patients need to be screened in early gestations. The ectopic pregnancies usually occur in the fallopian tubes. Implantation of a pregnancy within the abdomen e.g. in ovary, omentum or within the scar of a previous cesarean delivery are described (1,2,3). Also unusual concurrent occurrence of acute appendicitis and ectopic pregnancy in the fallopian tube is known (4,5). The occurrence of ectopic pregnancy in the mesoappendix is a new finding (Figures 1 and 2).

Case Report

A 36-year-old nullipara with a history of two years of infertil-

ity was referred because of delayed menses and generalized lower abdominal pain. Her surgical history was unremarkable. The blood pressure was 130/70 mm Hg, temperature 38°C and pulse 80 beats per minute. She had mild abdominal distension with generalized lower abdominal tenderness (greater in the right lower quadrant than the left), guarding and rebound. The patient reported having had no nausea, vomiting or vaginal bleeding. The cervix was closed. The uterus was 6 weeks in size and not tender.

The transvaginal sonography revealed no intrauterine gestational sac but blood in the cul-de-sac and normal adnexa. Beta human chorion gonadotropin (β -hCG) level was 9200 IU/mL, hemoglobin 13.4 g/dL and progesterone level was 7.0 ng/mL. Laparoscopy was performed. There were no pregnancy in the fallopian tubes. The right tube was somewhat inflamed. The blood in the cul-de-sac implicated the tuborian abort. Approximately 100 mL blood was encountered. The entire abdomen and pelvis were irrigated with normal saline and laparoscopy was finished. Uterine curettage was performed.

The day after laparoscopy β -hCG level increased to 11 500 IU/mL. Two days after laparoscopy β -hCG was 16 525 IU/mL and her pain persisted.

Corresponding Author: Dr. Cemil Yaman
General Hospital of Linz
Krankenhausstr. 9, A-4020 Linz, Austria
Phone : +43 732 7806 73389
Fax : +43 732 7806 2226
E-mail : cemil.yaman@akh.linz.at

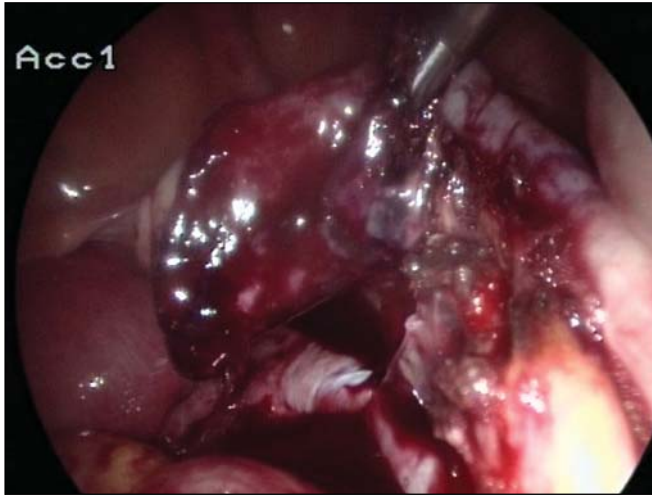

Figure 1. Laparoscopic imaging of ectopic pregnancy in the mesoappendix.

A second look laparoscopy was done. The ectopic pregnancy was seen at the mesoappendix (Figure 1). The appendix seemed to be infectious. The pregnancy was removed and appendectomy was performed by laparoscopy. Post-operative recovery was excellent. β -hCG levels decreased rapidly. The histological examination revealed the occurrence of ectopic pregnancy in the mesoappendix and appendicitis was confirmed (Figure 2).

Discussion

Ectopic pregnancies are reported to occur at a rate of 16 per 1000 pregnancies. Appendicitis appears about once per 1500 pregnancies, which is similar to that in the general population (6). The combination of ectopic pregnancy and appendicitis is expected to arise only once in nearly 94 000 pregnancies (4).

Pretreatment testing includes serum β -hCG, progesterone levels and transvaginal ultrasound. Sensitive β -hCG assays and transvaginal ultrasound can lead to the diagnosis of

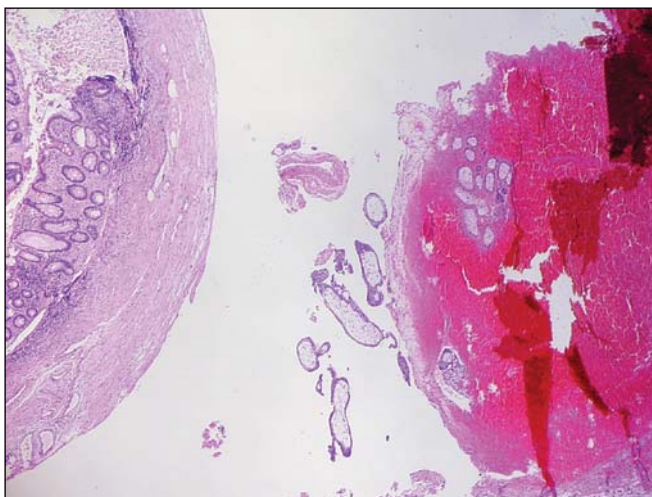


Figure 2. Histological demonstration of ectopic pregnancy in the mesoappendix.

ectopic pregnancy prior to symptoms. Subnormal rise in serum β -hCG and low progesterone levels are typically for abnormal early pregnancy (6). When β -hCG exceeds 2.400 IU/mL in serum, transvaginal ultrasound should be able to identify the presence of an intrauterine gestation of normal pregnancies (7).

Prompt laparotomy indicated by hemodynamically unstable patients are rare. Today, laparoscopy is performed to remove ectopic pregnancy. In cases with low β -hCG levels or persistent β -hCG levels, systemic methotrexat treatment may be considered (7).

A possible association between ectopic pregnancy and appendicitis in terms of a common pathogenic mechanism will be assumed. The cases reported suggest the possibility that an tubal pregnancy can produce an inflammatory reaction of the appendix (3,5,6).

Urbach et al. (8) critically assessed the evidence that appendiceal perforation is a risk factor for subsequent tubal infertility or ectopic pregnancy. The methodologic weaknesses of the studies did not permit acceptance of increased risk of tubal pregnancy or infertility as a consequence of perforation of the appendix.

Mesoappendix as primary location of the ectopic pregnancy is a new finding. We suggest that the implantation occurred in the mesoappendix and appendicitis occurred following this.

The presentation of acute abdominal pain in the first trimester can lead to many difficulties in achieving an accurate diagnosis. The possibility of multiple pathologic disorders should always be considered in a patient with an acute abdomen during pregnancy. In cases without laparoscopic evidence of ectopic pregnancy in the fallopian tubes, ovaries, omentum and also (meso)appendix should be visualized. In all locations of ectopic pregnancy, appendix should be checked to exclude concurrent inflammation. Otherwise, as seen in this case second look laparoscopy can be needed.

References

1. Robinson RD, Ginsburg ES. Persistent tubal pregnancy presenting with delayed hemorrhage from a second implantation of trophoblast on the ovary: a case report. *J Reprod Med.* 2004 Aug;49(8):693-5.
2. Pal L, Parkash V, Rutherford TJ. Omental trophoblastic implants and hemoperitoneum after laparoscopic salpingostomy for ectopic pregnancy. A case report. *J Reprod Med.* 2003 Jan;48(1):57-9.
3. Riggs JC, Schiavello HJ, Fixler R. Concurrent appendicitis and ectopic pregnancy. A case report. *J Reprod Med.* 2002 Jun;47(6):510-4.
4. Fylstra DL, Pound-Chang T, Miller MG, Cooper A, Miller KM. Ectopic pregnancy within a cesarean delivery scar: a case report. *Am J Obstet Gynecol.* 2002.
5. Barnett A, Chipchase J, Hewitt J. Simultaneous rupturing heterotopic pregnancy and acute appendicitis in an in-vitro fertilization twin pregnancy. *Hum Reprod.* 1999 Mar;14(3):850-1.
6. Akman MA, Katz E, Damewood MD, Ramzy AI, Garcia JE. Perforated appendicitis and ectopic pregnancy following in-vitro fertilization. *Hum Reprod.* 1995 Dec;10(12):3325-6.
7. Lipscomb GH, Meyer NL, Flynn DE, Peterson M, Ling FW. Oral methotrexate for treatment of ectopic pregnancy. *Am J Obstet Gynecol.* 2002 Jun;186(6):1192-5.
8. Urbach DR, Cohen MM. Is perforation of the appendix a risk factor for tubal infertility and ectopic pregnancy? An appraisal of the evidence. *Can J Surg.* 1999 Apr;42(2):101-8.