

Fused Umbilical Artery Found in a Case of Twin Pregnancy: A Case Report

Turgay SENER, H. Mete TANIR, Hikmet HASSA, Bülent ÇAKMAK

Department of Obstetrics and Gynecology, Osmangazi University School of Medicine, Eskişehir, Turkey

Received 17 November 2004; received in revised form 3 December 2004; accepted 6 December 2004

Abstract

In this manuscript, a fused umbilical artery found in a case of diamniotic-dichorionic twin pregnancy is reported. One of the twins was found to be deceased *in utero*. The living fetus have not had any perinatal complication. The postpartum examination of the umbilical cord revealed a fused umbilical artery in the proximal part of the cord. The antenatal sonographic evaluation of the umbilical cord is important in perinatal follow-up. The anomaly of fused umbilical arteries are frequently encountered in the proximal part of the umbilical arteries. For this reason, multiple cross sectional examinations must be performed during the sonographic evaluation of the cord.

Keywords: umbilical cord, umbilical cord abnormalities, prenatal diagnosis

Özet

Bir İkiz Gebelik Olgusunda Tespit Edilen Birleşik Umbilikal Arter: Olgu Sunumu

Bu yazıda, bir diamniotik-dikoryonik ikiz gebelik olgusunda tespit edilen birleşik umbilikal arter bildirilmiştir. İkizlerden biri *in utero* exitus olarak tespit edilmişti. Yaşayan fetüste herhangi bir perinatal komplikasyon oluşmadı. Umbilikal kordun postpartum yapılan incelemesinde proksimal kısımda birleşik umbilikal arter tespit edildi. Umbilikal kordun prenatal ultrasonografik incelemesi, perinatal takip açısından önemlidir. Umbilikal arterlerin plasentaya yakın kısımda sıklıkla birleşik umbilikal arter anomalisine rastlanmaktadır. Bu nedenle kordun sonografik incelemesinde fazla sayıda kesitlerde inceleme yapılması önemlidir.

Anahtar sözcükler: umbilikal kord, umbilikal kord anomalileri, prenatal tanı

Introduction

Ultrasonographic assessment, although not always possible, throughout the entire length of the umbilical cord with two arteries and one vein embedded in a Wharton's jelly, may assist in the diagnosis of various congenital and functional abnormalities of the cord such as cord cysts, hematomas, umbilical vein varix, aneurysms, single umbilical artery, fused umbilical arteries, velamentous insertion and vasa previa (1). The pathogenesis of single umbilical artery is assumed to result from the aplasia and atrophy of the missing vessel. At least in some cases, single umbilical artery may result from incomplete splitting of the single artery, leading to fused umbilical artery (2). Fused umbilical arteries near the placental insertion have been found in several studies, despite its evidence for the association with fetal anomalies has been rarely documented (3). However, the presence of a single umbilical artery is recognised as a soft marker for congenital anomalies, aneuploidy, earlier delivery and low birthweight (4,5,6).

We describe a diamniotic, dichorionic twin pregnancy showing a fused umbilical artery and dead co-twin *in utero* on prenatal ultrasonography.

Case Report

A 31-year-old women in her sixth pregnancy (G:6,P:4) was referred to our clinic due to inaccessibility of fetal cardiac signals on cardiotocography. On ultrasound examination at 36th weeks of gestation, she was found to have a diamniotic, dichorionic twin pregnancy. However, one of the fetus was dead *in utero*, with the additional findings of ascites, hydrothorax and hyperchogenic bowel. Both amniotic fluids and placentas were normal in appearance. On Doppler examination of the co-twin, near the placental insertion (<4 cm to placental insertion), a single umbilical artery was noticed (Figure 1). Further insonation along the cord revealed 'two- arteries-one vein' appearance. No fetal anomalies was present in the live fetus. The patient was delivered with cesarean section following which a 2960 g dead and 1890 g live neonates were born. Indication of cesarean section was elective and dependent on maternal request. Postcesarean follow-up of the live neonate was uneventful and discharged from the hospital on day 7 following the delivery together with her mother. No gross

Corresponding Author: Dr. Hüseyin Mete Tanır
Osmangazi Üniversitesi Tıp Fakültesi, Kadın ve Doğum AD
Meşelik Kampusu, 26480 Eskişehir, Türkiye
Phone&Fax : + 90 222 239 84 12
E-mail : mtanir@superonline.com

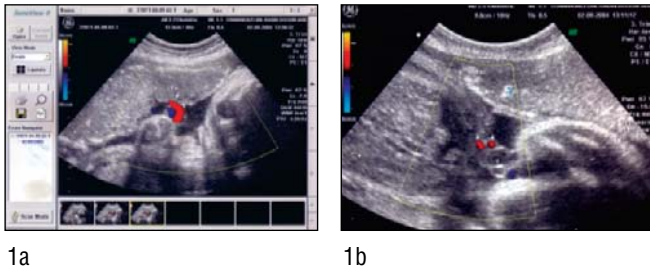


Figure 1. Two vessel cord view on Doppler ultrasonography near the placental cord insertion (1a) and normal three-vessel view of the cord 4 cm far from the placental insertion (1b).

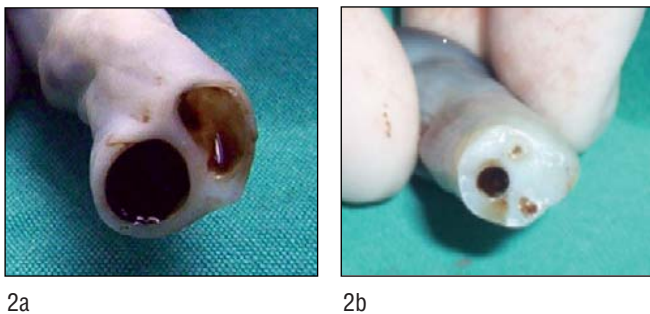


Figure 2. Cross-sectional gross views of the umbilical cord of live co-twin, showing two vessels near the placental insertion (2a) and the mid-segment 6 cm far from the placental insertion (2b), revealing three-vessels appearance.

anomaly was seen in the live co-twin. Autopsy of the dead twin was declined by the family. A cross-sectional view of the umbilical cord near the placental insertion (Figure 2a) and at mid-segment (Figure 2b) depicted the same anatomy, as shown also on color Doppler findings.

Discussion

Although prenatal complications and congenital malformations are assumed to be rare in fused umbilical arteries, anomalies such as renal agenesis, Hallermann-Streiff syndrome, velamentous and marginal placental insertions have been reported in some studies (2,6,7). Likewise, if the cord is sectioned near the chorionic plate, fused umbilical arteries may be misdiagnosed

as true SUA. Hence, single umbilical artery should be confirmed following the multi-sectional analysis of the umbilical cord at different points. Since, when a true single umbilical artery diagnosis was made on routine ultrasound, high incidence of major chromosomal and congenital anomalies, justifying a fetal ultrasonography, invasive tests and fetal echocardiography and fetal karyotyping (8). This issue is especially crucial with regard to the prognosis of such pregnancies. However, presence of fused umbilical arteries especially near the placental insertion, following a multi-segmental analysis and confirmation of normal vessel anatomy elsewhere in the cord, should refrain the physician to proceed to further extensive fetal evaluation. On Doppler ultrasonography, demonstration of a single umbilical artery around the bladder facilitates the diagnosis of single umbilical artery (4).

To conclude, on the basis of aforementioned case, it is noteworthy that the cord should be insonated sufficiently distant from the placental insertion (>4 cm) as two arteries may fuse into one trunk giving rise to an erroneous diagnosis fo a single umbilical artery. But, in determining the number of umbilical vessels, naked-eye or sonographic views can be misleading and histology should be the definitive method of ascertainment.

References

1. Sherer DM, Anyaegbunam A. Prenatal ultrasonographic morphologic assessment of the umbilical cord: a review Part II. *Obstet Gynecol Surv.* 1997;52(8):515-23.
2. Sepulveda W, Dezegara V, Carstens F, Gutierrez J. Fused umbilical arteries: prenatal sonographic diagnosis and clinical significance. *J Ultrasound Med.* 2001;20(1):59-62.
3. Fujikura T. Fused umbilical arteries near placental insertion. *Am J Obstet Gynecol.* 2003;188:765-7.
4. Singh V, Patel R, Pradhan P. Single umbilical artery and associated hydro-nephrosis: a report of 2 cases. *J Reprod Med.* 2004;49(2):136-8.
5. Sener T, Ozalp S, Hassa H, Zeytinoglu S, Basaran N, Durak B. Ultrasonographic detection of single umbilical artery: a simple marker of fetal anomaly. *Int J Gynecol Obstet.* 1997;58:217-21.
6. Prucka S, Clemens M, Craven C, McPherson E. Single umbilical artery: what does it mean to the fetus? A case-control analysis of pathological ascertained cases. *Genet Med.* 2004;6(1):54-7.
7. Johnson CW, Tennenbaum SY. Urologic anomalies and two-vessel umbilical cord; what are the implications? *Curr Urol Rep.* 2003;4(2):146-50.
8. Gornall AS, Kurinczuk JJ, Konje JC. Antenatal detection of a single umbilical artery: does it matter? *Prenat Diagn.* 2003;23(2):117-23.