



Spontaneous Ovarian Hyperstimulation Syndrome Complicating a Normal Singleton Pregnancy: A Case Report

Murat ULUKUŞ, Fuat AKERCAN, Özgür YENİEL, Nedim KARADADAŞ, Mustafa ULUKUŞ

Department of Obstetrics and Gynecology, Ege University Faculty of Medicine, İzmir, Turkey

Abstract

Ovarian hyperstimulation syndrome (OHSS) is the most common and sometimes life threatening complication of ovulation induction protocols and assisted reproductive procedures. It usually occurs iatrogenically by the use of drugs such as exogenous gonadotropins or less frequently clomiphene citrate to induce multiple ovulation. However spontaneous form of this syndrome is extremely rare in the literature. In this report we describe a case of spontaneous OHSS that occurred in a 26 year old pregnant woman with no underlying disease. When abdominal distension and dyspnea progressed, leading to deleterious laboratory results, the pregnancy was terminated by therapeutic abortion.

Keywords: pregnancy, spontaneous ovarian hyperstimulation syndrome

Özet

Normal Tekil Gebeliği Komplike Eden Spontan Ovaryan Hiperstimülasyon Sendromu: Olgu Sunumu

Ovaryan hiperstimülasyon sendromu (OHSS), ovulasyon indüksiyon protokolleri ve asiste reproduktif prosedürlerin en sık gözlenen ve bazen de hayatı tehdit edebilen bir komplikasyondur. Çoğu kez multipl ovulasyon elde etmek amacıyla ekzojen gonadotropinler ve daha nadir olarak da klomifen sitrat gibi ajanların kullanılmasına bağlı, iatrojenik olarak gelişen bir sendromdur. Bununla beraber bu sendromun spontan formu oldukça nadirdir. Bu makalede altta yatan herhangi bir hastalığı bulunmayan, 26 yaşındaki gebede spontan olarak gelişen ovaryan hiperstimülasyon sendromu sunulmuştur. Abdominal distansiyon, dispne ve laboratuvar bulgularındaki kötüleşme nedeniyle gebelik terapötik abortusla sonlandırılmıştır.

Anahtar sözcükler: gebelik, spontan ovaryan hiperstimülasyon sendromu

Introduction

Ovarian hyperstimulation syndrome (OHSS) is the most severe and even potentially life threatening complication of ovarian-stimulating agents. Exogenous gonadotropins and less frequently clomiphene citrate have been known as the main drugs associated with this syndrome (1,2). Abdominal pain, dyspnea, ovarian enlargement, ascites, oliguria, arterial and venous thrombosis and laboratory disturbances such as hemoconcentration and electrolyte imbalance are the main clinical manifestations of this syndrome (3). The incidence of mild form varies between 5-10% and severe form 0.2-0.5% of cycles in anovulatory woman treated with different preparations for induction of ovulation. The incidence in women treated by assisted reproduction is 2-4% moderate OHSS and 0.1-0.5% severe OHSS (4). However spontaneous OHSS complicating pregnancy is an extremely rare event.

Case report

A 26-year-old gravida 2 para 1 woman was admitted to our clinic in the 18th week of gestation because of abdominal distension, dyspnea and vaginal bleeding. She stated that abdominal distension and dyspnea have occurred one week before and since then she was hospitalized in a public hospital because of the confirmed bilateral ovarian cysts and ascites. As her clinical conditions progressing, it was decided to terminate the pregnancy by the intravaginally misoprostol administration. In the day of misoprostol administration, as her blood pressure decreases and dyspnea and abdominal distension worsening, she was sent to our clinic.

At the admission, blood pressure was 70/40 mm/Hg and pulse rate was 100 beats/min. Obstetric examination revealed 3 cm of cervical dilatation and vaginal bleeding due to misoprostol administration. Ultrasonographic examination revealed a living fetus, bilaterally enlarged multicystic ovaries (150X90 mm right, 135X96 mm left) and a large amounts of ascites (Figure 1). The AP X-ray of the chest showed basal pleural effusion on both sides. Laboratory studies revealed leucocytosis (18000/mm³), low concentra-

Corresponding Author: Murat Ulukuş, MD
Ege Üniversitesi Tıp Fakültesi Kadın Hastalıkları ve Doğum AD,
35100 Bornova, İzmir, Türkiye
Phone : +90 (232) 388 19 63 / 300
Fax : +90 (232) 343 07 11
E-mail : ulukus@med.ege.edu.tr

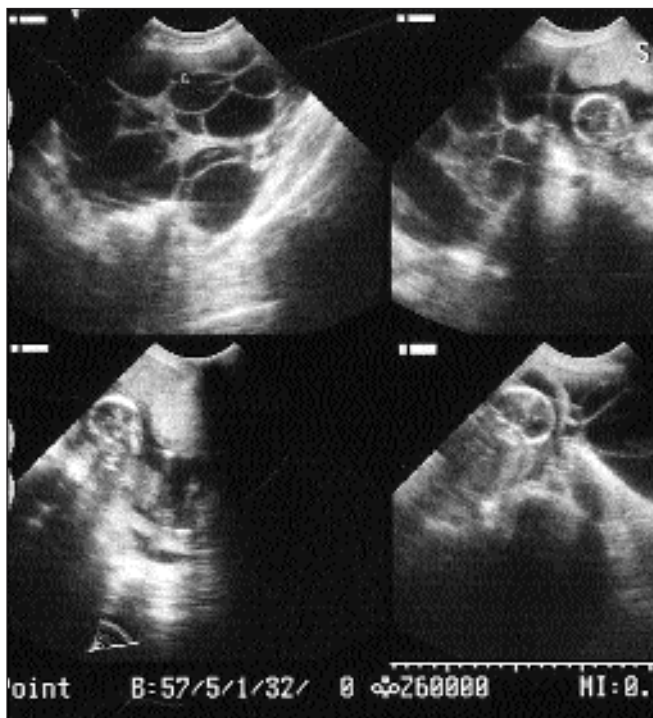


Figure 1. Ultrasonographic appearance of the pregnant uterus and bilaterally enlarged ovaries.

tions of hemoglobin (9.5 g/l), hematocrit (28%), albumin (2.7 g/dl) and total protein (5 g/dl). Blood urea nitrogen, creatinine and liver function tests were in normal range. On the hormone essays of the admission day, the β -hCG value was extremely above the normal range for gestational age (200.000 mIU/l), estradiol was 5500 pg/ml and the thyroid function tests were normal. The CA-125 level was 2110 IU/ml.

In her obstetric history she delivered a healthy normal baby at full term four years ago. In her present pregnancy she stated that a nuchal oedema was seen and therefore an amniocentesis was performed at the 12th weeks of gestation. Analysis of the amniocentesis revealed normal karyotype. She also stated that she had never taken medications for ovulation induction.

Two hours after the admission, the patient aborted a 400 g macroscopically normal fetus and dilatation and curettage was also performed. (Histopathological examination of fetus, placenta and the curettage material showed no abnormality.) According to Gollan's classification, we made the diagnosis as severe OHSS (5). She was immediately managed with intravenous fluid replacement, human albumin and low-molecular weight heparin (LMWH). Body weight, abdominal circumference, intake and outputs, ultrasonography and laboratory studies were monitored strictly daily. Interestingly, the full-blown picture of the syndrome developed after the day of the abortion. The β -hCG value increased to 330.000 mIU/l, hemoconcentration (41%) and thrombocytosis ($780.000/\text{mm}^3$) occurred. As the dyspnea and abdominal distension remains after the abortion, ultrasound guided therapeutic paracentesis was performed three times with two days

intervals and 5500 cc ascitic fluids was taken totally. Cytological examination of the ascites revealed fluid of theca lutein cyst.

At the end of 4th week of admission, her complaints of dyspnea and abdominal distension decreased, laboratory abnormalities like hemoconcentration and thrombocytosis improved and size of the ovarian cysts and ascites regressed. Three weeks after the discharge, she had no complaint, ultrasonographic and laboratory examination was completely normal.

Discussion

OHSS occurs iatrogenically in almost all cases by using the drugs to induce multiple ovulation in infertile patients. This condition may also develop spontaneously, but it is an extremely rare event. Although there are no clear predictive risk factors for the development of OHSS, young age, polycystic ovary syndrome, asthenic habitus, luteal supplementation of hCG, protocols with GnRHa, high level of serum estradiol, multiple follicles and ovarian necklace sign were reported as the possible risk factors (4). This syndrome is characterized by massive transudation of protein-rich fluid (mainly albumin) from the vascular space especially into the peritoneal and pleural cavities. It has been reported that the intensity of the syndrome is related to the degree of the follicular response in the ovaries to the ovulation inducing agents (6).

The exact pathogenesis of OHSS is not yet clearly determined. It has been suggested that vasoactive substances such as histamine, serotonin, prostoglandins, interleukins, TNF- α , ovarian renin-angiotensin system and vascular endothelial growth factor (VEGF) which are activated by exogenous gonadotropins can lead to increased vascular permeability and extravascular fluid accumulation in OHSS (4,7-9). In recent years particularly VEGF became more popular on the pathogenesis of OHSS. It has been reported that it is responsible for the significant increase in the capillary permeability, extravascular fluid accumulation, hemoconcentration and elevated plasma concentration of von Willebrand factor, all known complications of OHSS (4,10). Elevated levels of this cytokine were found both in the serum and in the ascitic fluid of patients with severe OHSS (4,10,11). However it has been also reported that the serum concentrations of VEGF does not predict the course of the disease (12). The etiopathogenesis of spontaneous OHSS is less clear. Some authors suggested that polycystic ovary syndrome (PCOS) could also be a risk factor for spontaneous OHSS (13,14). However some cases developed this condition without underlying PCOS (15-18). Spontaneously developed OHSS has been reported in twin and molar pregnancies in which the endogenous hCG levels were higher than normal (19,20). However, OHSS also been observed in women with normal or lower than normal hCG concentration. Thus, it is postulated that high concentrations of hCG are not responsible for every case of OHSS (21). Hypothyroidism is another postulated risk factor for the development of spontaneous

OHSS (22,23). Our case did not show any signs of PCOS or hypothyroidism as confirmed by blood and ultrasound examinations we performed 3 months after the abortion.

Our case developed the full-blown picture of OHSS after the termination of the pregnancy, and this picture lasted during two weeks. We could exclude the molar pregnancy by histopathological examination of the placenta and fetus, and ovarian malignancy by cytological examination of the ascitic fluid. We postulated that elevated concentration of β -hCG was the main triggering mechanism for the present case.

The principals of management of OHSS are the same in both spontaneously and iatrogenically developed forms. When OHSS complicates pregnancy, many authors recommend the continuation of the pregnancy, as the syndrome is a self-limiting process. In almost all cases, the disease regresses spontaneously with time or delivery. However the management and treatment of each patient is critical as deaths from the syndrome have been reported due to hypovolemia, hemorrhage and thromboembolic phenomena (6). Hospitalization is needed in moderate and severe forms. Strictly monitoring of the hemodynamic status, intravenous crystalloid and albumin infusion, application of LMWH for the prophylaxis of thrombosis are the main steps for the management. Paracentesis of ascitic fluids may have positive effects on the respiratory functions and also on the renal functions by increasing urinary output and reducing blood urea nitrogen (24).

However the conservative management could not be sufficient in every case and termination of the pregnancy might be necessary. (13,19). If the clinical conditions worsening despite the extensive therapy as happened in our case, termination of the pregnancy should be encouraged regardless of the gestational age. Another reported subject with this syndrome is that the exploratory laparotomy was performed in some cases in which ovarian malignancy could not be excluded (16,25). In fact, surgery should be reserved only in cases of ovarian rupture, torsion and intraperitoneal hemorrhage.

References

1. Tucker TE. Reproductive toxicity of ovulation induction. *Semin Reprod Endocrinol* 1996;14:345-353.
2. Delvigne A and Rosenberg S. Systematic review of data concerning etiology of ovarian hyperstimulation syndrome. *Int J Fertil Womens Med* 2002;47:211-226.
3. Foong LC, Bhagavath B, Kumar J and Ng SC. Ovarian hyperstimulation syndrome is associated with reversible impairment of vascular reactivity. *Fertil Steril* 2002;78:1159-1163.
4. Schenker JG. Clinical aspects of ovarian hyperstimulation syndrome. *Eur J Obstet Gynecol Reprod Biol* 1999;85:13-20.
5. Golan A, Ron-el R, Herman A, Soffer Y, Weinraub Z and Caspi E. Ovarian hyperstimulation syndrome: an update review. *Obstet Gynecol Surv* 1989;44:430-440.
6. Rutkowski A. and Dubinsky I. Ovarian hyperstimulation syndrome: imperatives for the emergency physician. *J Emerg Med* 1999;17:669-672.
7. Abramov Y, Schenker JG, Levin A, Friedler S, Nisman B and Barak V. Plasma inflammatory cytokines correlate to the ovarian hyperstimulation syndrome. *Hum Reprod* 1996;11:1381-1386.
8. Loret de Mola JR, Flores JP, Baumgardner GP, Goldfarb JM, Gindlesperger V and Friedlander MA. Elevated interleukin-6 levels in the ovarian hyperstimulation syndrome: ovarian immunohistochemical localization of interleukin-6 signal. *Obstet Gynecol* 1996;87:581-587.
9. Delbaere A, Bergmann PJ, Gervy-Decoster C, Deschodt-Lanckman M, de Maertelaer V, Staroukine M, Camus M and Englert Y. Increased angiotensin II in ascites during severe ovarian hyperstimulation syndrome: role of early pregnancy and ovarian gonadotropin stimulation. *Fertil Steril* 1997;67:1038-1045.
10. Abramov Y, Barak V, Nisman B and Schenker JG. Vascular endothelial growth factor plasma levels correlate to the clinical picture in severe ovarian hyperstimulation syndrome. *Fertil Steril* 1997;67: 261-265.
11. Krasnow JS, Berga SL, Guzick DS, Zeleznik AJ and Yeo KT. Vascular permeability factor and vascular endothelial growth factor in ovarian hyperstimulation syndrome: a preliminary report. *Fertil Steril* 1996;65:552-555.
12. Ludwig M, Bauer O, Lopens A, Jelkmann W and Diedrich K. Serum concentrations of vascular endothelial growth factor cannot predict the course of severe ovarian hyperstimulation syndrome. *Hum Reprod* 1998;13: 30-32.
13. Zalel Y, Katz Z, Caspi B, Ben-Hur H, Dgani R and Insler V. Spontaneous ovarian hyperstimulation syndrome concomitant with spontaneous pregnancy in a woman with polycystic ovary disease. *Am J Obstet Gynecol* 1992;167:122-124.
14. Zalel Y, Orvieto R, Ben-Rafael Z, Homburg R, Fisher O and Insler V. Recurrent spontaneous ovarian hyperstimulation syndrome associated with polycystic ovary syndrome. *Gynecol Endocrinol* 1995;9: 313-315.
15. Rosen GF and Lew MW. Severe ovarian hyperstimulation syndrome in a spontaneous singleton pregnancy. *Am J Obstet Gynecol* 1991;65:1312-1313.
16. Lipitz S, Grisaru D, Achiron R, Ben-Baruch G, Schiff E and Mashiach S. et al. Spontaneous ovarian hyperstimulation mimicking an ovarian tumour. *Hum Reprod* 1996;1:720-721.
17. Regi A, Mathai M, Jasper P, Krishnaswami H, Prem S and Peedicayil A. Ovarian hyperstimulation syndrome (OHSS) in pregnancy not associated with ovulation induction. *Acta Obstet Gynecol Scand* 1996;75:599-600.
18. Chae HD, Park EJ, Kim SH, Kim CH, Kang BM and Chang YS. Ovarian hyperstimulation syndrome complicating a spontaneous singleton pregnancy: a case report. *J Assist Reprod Genet* 2001;18:120-123.
19. Leis, D., Richter, K. and Schimid, K. Spontaneous hyperstimulation of the ovaries with luteal cysts and ascites during a twin pregnancy-extreme case of the syndrome of painful early pregnancy. *Geburtshilfe Frauenheilkd* 1978;38:1085-1087.
20. Ludwig M, Gembruch U, Bauer O and Diedrich K. Ovarian hyperstimulation syndrome (OHSS) in a spontaneous pregnancy with fetal and placental triploidy: information about the general pathophysiology of OHSS. *Hum Reprod* 1998;13:2082-2087.
21. Todros T, Carmazzi CM, Bontempo S, Gaglioti P, Donvito P and Massobrio M. Spontaneous ovarian hyperstimulation syndrome and deep vein thrombosis in pregnancy. *Hum Reprod* 1999;14:2245-2248.
22. Rotmensch S. and Scommegna A. Spontaneous ovarian hyperstimulation syndrome associated with hypothyroidism. *Am J Obstet Gynecol* 1989;160:1220-1222.
23. Nappi RG, Di Naro E, D'Aries AP, Nappi L. Natural pregnancy in hypothyroid women complicated by spontaneous ovarian hyperstimulation syndrome. *Am J Obstet Gynecol* 1998;178:610-611.
24. Levin I, Almog B, Avni A, Baram A, Lessing JB and Gamzu R. Effect of paracentesis of ascitic fluids on urinary out and blood indices in patients with ovarian hyperstimulation syndrome. *Fertil Steril* 2002;77:986-988.
25. Ayhan A, Tuncer Z and Aksu AT. Ovarian hyperstimulation syndrome associated with spontaneous pregnancy. *Hum Reprod* 1996;11:1600-1601.