



A Case of Malignant Low Grade Endometrial Stromal Sarcoma and Review of the Literature

Mert GOL¹, Aydın ÇETİN², Cenk M. GÜVEN², Ali BALOĞLU², Seyran YİĞİT³

¹Department of Obstetrics and Gynecology, Dokuz Eylül University Faculty of Medicine, İzmir, Turkey

²Department of Obstetrics and Gynecology, 1st Clinic, Atatürk Training and Research Hospital, Yeşilyurt, İzmir, Turkey

³Department of Pathology, Atatürk Training and Research Hospital, Yeşilyurt, İzmir, Turkey

Abstract

Low grade endometrial stromal sarcoma is a rare pelvic malignancy that most commonly arises from the endometrium. These tumors are usually limited to the pelvis and uterus thus extensive spread is not common.

In this case report, we present a 42-year-old woman with the complaint of abnormal uterine bleeding and pelvic pain diagnosed with advanced extrauterine low grade endometrial stromal sarcoma. Abdomino-pelvic exploration at laparotomy showed that the tumor was extending from the uterus to middle and upper abdomen. After tumor debulking surgery, she was treated with adjuvant radiotherapy and chemotherapy regimen containing of ifosfamide, adriamycin, and cisplatin. However, there was no any regression in the remaining parts of the tumor and the patient succumbed to the disease 12 months after the diagnosis.

We suggest that low grade endometrial stromal sarcomas should be classified as malignant as high grade endometrial stromal sarcomas.

Keywords: uterine sarcoma, low grade endometrial stromal sarcoma, extrauterine disease

Özet

Malıgn Düşük Dereceli Endometriyal Stromal Sarkom Olgusu: Literatürün Gözden Geçirilmesi

Düşük dereceli endometriyal stromal sarkom, en sık olarak endometriumdan köken alan ve nadir olarak görülen pelvik bir tümördür. Bu tümörler genelde uterus ve pelvisle sınırlıdır ve ileri yayılım sık olarak görülmemektedir. Bu olgu sunumunda, tanı konulduğu anda uterusun, orta ve yukarı abdomene doğru yayılım gösteren düşük dereceli endometriyal stromal sarkom sunulmuştur. Kırk iki yaşındaki kadın hastada, pelvik ağrı ve abnormal vajinal kanama şikâyeti nedeniyle yapılan incelemelerde, ileri yayılım gösteren ekstrauterin düşük dereceli endometriyal stromal sarkom tespit edildi. Tümör "debulking" cerrahi sonrasında hastaya adjuvan radyoterapi ile birlikte ifosfomide, adriamisin ve sispilatin rejimleri içeren kemoterapi uygulandı. Ameliyattan on iki ay sonra hasta tümör nedeniyle hayatını kaybetti. Düşük dereceli endometriyal stromal sarkomlar, yüksek dereceli endometriyal stromal sarkomlar gibi malıgn olabilmektedir. Bu çalışmada bu tümörlerin tedavisi ve prognozu ile ilgili literatür tartışılmıştır.

Anahtar sözcükler: uterin sarkom, düşük dereceli endometriyal stromal sarkom, ekstrauterin hastalık

Introduction

Low grade endometrial stromal sarcoma (LGESS) is an uncommon, indolent uterine sarcoma that most commonly arises from the endometrium. They have mitotic count of less than 10/10 high power fields (hpf), as well as absent of pleomorphic anaplastic cells (1). Spreading of the disease to unusual sides such as the bowel, the liver and the lungs is uncommon at the time of diagnosis. Recurrence is a common problem in these tumors and usually confines in the pelvis (2, 3). However, only a minority of cases die from the disease.

In this case we presented the surgical and chemotherapeutic management of a patient with advanced LGESS. We believe that this case is the first that shows extensive extrauterine spread of a LGESS. These tumors could be as malignant as high grade endometrial stromal sarcomas.

Case

A 42-year-old G5P3 woman admitted with the complaint of abnormal vaginal bleeding and sensation of pain in her lower abdomen for one week. Her last menstrual period was one year ago. In physical examination the patient was found to be normal. In gynecological examination the patient had an exophytic, ulcerated, and bloody discharged tumor in 3 x 2 cm diameters, which was extending from the cervical ostium through the vagina. There was a firm, non-mobile tumor in the pelvis extending through the up-

Corresponding Author: Mert Gol, MD
Mithatpaşa Cad. No: 1131/4 Üçkuyular, İzmir, Türkiye
Phone: +90 (232) 246 25 44
E-mail: mertgol@egenet.com.tr

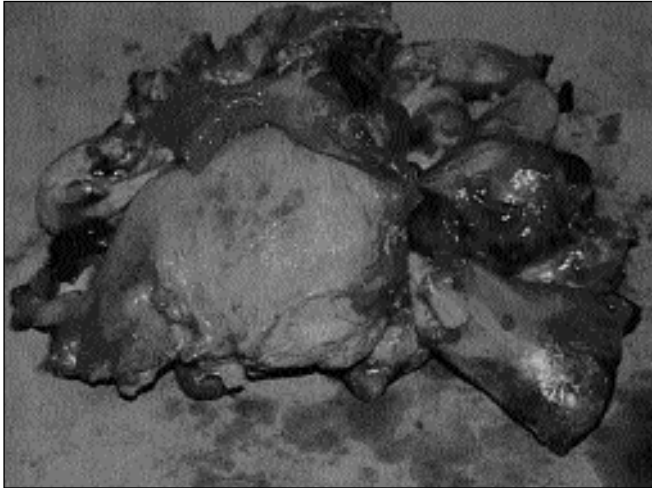


Figure 1. Low grade endometrial stromal sarcoma extending from the posterior wall of the uterus.

per abdomen. The uterus and the adnexae were not palpable. An ultrasound and CT scan were performed which confirmed the presence of heterogenic tumor that was extending from the enlarged uterus through the upper abdomen with bilateral normal adnexae. Endoscopic examinations of the upper and lower gastrointestinal systems were normal. Biopsy of the tumor, which was extending from the cervix, showed hyperplastic stroma with a few glands. Exploratory surgery with the presumptive diagnosis of uterin tumor was decided to be performed.

Abdomino-pelvic examination at laparotomy revealed a fragile, yellow-green colored, irregular, 20 x 20 x 12 cm in diameters tumor, which was extending from the pelvis through the upper abdomen. Uterus was 4 weeks in size which was ruptured at the posterior wall by the tumor (Figure 1). The adnexae were normal bilaterally. Tumor formed a conglomerate mass with the transvers and ascending colon, whereas the sigmoid colon, rectum and omentum were all involved with the tumor. Whole pelvis was filled with tumoral pieces.

A total hysterectomy with bilateral salpingo-oophorectomy, omentectomy, and tumor debulking procedure were performed. However some adherent tumor pieces to bowel in the mid and upper abdomen could not be removed completely. Pathologic examination of the tumor was performed by an experienced pathologist in gynecologic oncology. Final pathologic diagnosis was low grade endometrial stromal sarcoma arising from the endometrium. Both ovaries were tumor free. All of the resected tumor nodules throughout the abdomen were positive for tumor.

Further examinations revealed a mitotic count of 2-3/10 hpf and myometrial invasion (Figure 2). The neoplastic stromal cells were positive for vimentin and desmin. The glandular as well as the stromal elements were negative for estrogen and progesterone receptors. Immunohistochemical staining with CD10 was diffusely positive throughout the tumor. The-

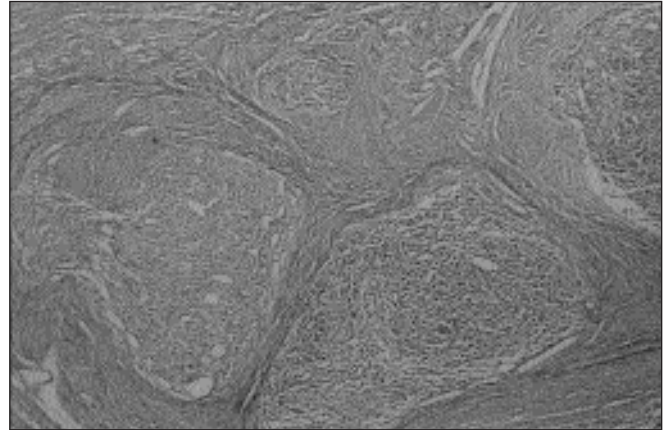


Figure 2. Showing myometrial invasion of the tumor (HE x 44).

se findings were consistent with the diagnosis of LGESS.

The patient had an uneventfully postoperative period. Adjuvant radiotherapy, subsequently 6 cycles of chemotherapy with ifosfamide, adriamycine, and cisplatin was applied postoperatively. However the patient did not respond to the treatment protocol and died 12 months after the operation.

Discussion

Endometrial stromal sarcoma constitutes 15% to 25% of uterine sarcomas. These tumors are seen most commonly in older postmenopausal women; however women in the reproductive ages may be affected (2). LGESS has typically a mitotic count of 5 and-or less/10 hpf with minimal atypia in the cells. Some tumors may be positive for estrogen and progesterone receptors which may affect treatment modalities (4).

Patients with LGESS typically present with abnormal vaginal bleeding, pelvic and abdominal pain. In some cases it might be without any complaints (5). Most tumors grow through the intramural sections of the uterus rather than intra cavitary, hence making it difficult for preoperative histopathologic diagnosis. Patients most commonly undergo surgery with the presumptive diagnosis of uterine fibroid or pelvic mass. The physician should have a suspicion when the histopathologic diagnosis of endometrial sampling yields hyperplastic stroma with few glands.

LGESS usually behaves in an indolent clinical fashion; however recurrences and distant metastases can occur. Prolonged survival as well as cure is common despite the development of recurrent or metastatic disease (3). Spread from the uterus at the time of the diagnosis is a common finding in LGESS, however extension usually confines in the pelvis. Bohr and Thomsen (2) showed in a series of 138 cases that the extension beyond the uterus occurs in one-third of the patients at the time of the diagnosis. These authors' stated that invasion



most commonly occurs through the myometrium, lymphatic vessels, and venous channels of the broad ligament, adnexae, and cardinal ligament. Recurrence is a common finding and occurs in almost 50% of patients with an average interval of five years after the initial therapy (2).

The mitotic count is an important independent prognostic factor for these tumors (3). In addition, it has been suggested that early tumor stage, low myometrial invasion, and low mitotic count are associated with a lengthened overall survival in patients with endometrial stromal sarcomas (6). In contrary, Chang et al. (7) postulated that the mitotic count is not an important prognostic factor in stage I patients. Similarly in Kempson's (8) series of 73 stage I patients with endometrial sarcoma, 4 of 15 (26%) patients with a mitotic count of 10 or more/10 hpf had recurrence, whereas 22 of 54 (40%) patients with a mitotic count of 10 or less/10 hpf had recurrence. This author concluded that the stage of the tumor, as a prognostic factor, is more important than the mitotic count.

Surgical resection is the primary treatment for endometrial stromal sarcomas. Total abdominal hysterectomy with bilateral salphingo-oophorectomy should be performed to improve the local control of the disease. Adnexae should always be removed bilaterally because of the high propensity of the tumor extension into the parametria, broad ligaments, and adnexial structures, as well as the possible stimulating effect of estrogen from retained ovaries on tumor cells (8). Lymph node involvement is an uncommon finding in LGESS, thereby lymphadenectomy would be of dubious value. The applicability of radical hysterectomy is limited since the diagnosis is typically made during or after the surgery.

The role of adjuvant therapy for stage I LGESS is uncertain, however it is recommended because of high recurrence rates. (4,5). It was postulated that either pelvic radiation and high-dose progesterone therapy (e.g., MPA 100 mg/day PO) are effective treatment modalities (4,5). Piver et al. (9) noted objective responses to progesterone therapy in six of 13 (46%) patients with endometrial stromal sarcoma.

Radiation therapy and progesterone treatment can be used sequentially or alone. In the later case, the absence of hormone receptors would favor the use of radiation therapy whereas in patients with slender stature and other features increasing the risk of radiation complications would favor hormonal therapy. It has been emphasized that surgical cytoreduction should despite be the first line of treatment for cases with recurrence or at advanced stages [8]. Chemotherapy with cytotoxic drugs should be used in patients when radiation therapy or progesterone is not applicable as an adjunctive treatment modality. In the study of Yamawaki et al. (10) it was reported that the use of combined chemo-therapeutic

agents in a patient with endometrial stromal sarcoma shrank metastatic pulmonary nodules and pelvic metastases.

The clinical behavior of LGESS is not that of a low grade-malignancy in terms of the frequency of recurrence, because approximately one-third of stage-I patients have recurrent disease (2). However the disease is characterized by late recurrence and slow progression. The most common site of recurrences is the pelvic structures; however metastasis to the upper abdomen and lung is not unusual (5). Although recurrence is a common finding in LGESS prognosis is usually good in early stages (7).

In this case report we presented a patient with advanced primary extra-uterine LGESS. This aggressive clinical fashion of the tumor may be explained by the early and excess lymphatic involvement of these tumors (4). In the present case, there was also extensive lympho-vascular involvement throughout the specimens. To our knowledge, this case is the first that shows extensive dissemination of a LGESS through the whole pelvis and upper abdomen. We suggest that LGESS may be as malignant as a high grade endometrial stromal sarcoma.

References

1. Hacker NF, Moore JG, Uterine sarcomas. In: Hacker, NF, Moore, JG, editors. *Essentials of Obstetric and Gynecology*. 2nd ed. Philadelphia: WB Saunders, 1998;642.
2. Bohr L, Thomsen CF. Low-grade stromal sarcoma: a benign appearing malignant uterine tumor: a review of current literature: differential diagnostic problems illustrated by four cases. *Eur J Obstet Gynecol Reprod Biol* 1991;39:63.
3. Gadducci A, Sartori E, Landoni F, Zole P, Maggino T, Urgesi A. Endometrial stromal sarcoma: Analysis of treatment failures and survival. *Gynecol Oncol* 1996;63(2):247-53 (doi:10.1006/gyno.1996-0314).
4. Katz L, Merino MJ, Sakamoto H, Schwartz PE. Endometrial stromal sarcoma: a clinicopathologic study of 11 cases with determination of estrogen and progesterone receptor levels in three tumors. *Gynecol Oncol* 1987;26(1):87-97.
5. Feliete PS, Velias F. The clinical and histopathological spectrum of endometrial stromal neoplasms: a report of all cases. *Int. J. Gynecol Pathol* 1984;3:198.
6. Bodner K, Bodner B, Obermair A, Windbichler G, Petru E, Mayerhofer S. Prognostic parameters in endometrial stromal sarcoma: A clinicopathologic study in 31 patients. *Gynecol Oncol* 2001;81(2):160-65 (doi:10.1006/gyno.2001-6152).
7. Chang KL, Crabtree GS, Lim-Tan SK. Primary uterine endometrial stromal neoplasms: a clinico-pathologic study of 117 cases. *Am J Surg Pathol* 1990;14:415.
8. Kempson RL: Uterine mesenchymal neoplasms. 5th Annual Review Course on Gynecologic Oncology and Pathology, Matsumoto, Japan, November 22-23, 1994.
9. Piver MS, Rutledge FN, Copeland L, Webster K, Blumenson L, Suh O. Uterine endolymphatic stromal myosis: a collaborative study. *Obstet Gynecol* 1984;64:173-8.
10. Yamawaki T, Shimizu Y, Hasumi K. Treatment of stage-IV high grade endometrial stromal sarcoma with ifosfamide, adriamycin, and cisplatin. *Gynecol Oncol* 1997;64(2):265-269 (doi:10.1006/gyno.1996-4537).